SOC · OBSTET · LOND ·
1859



G18.06 067
44

Library

of the

Academy of Medicine,

Toronto.

2421

Presented by

J. Hillman Esq M.D.
1915

OBSTETRICAL TRANSACTIONS.

VOL. XLIV.

TRANSACTIONS

OF THE

OBSTETRICAL SOCIETY

OF

LONDON.

VOL XLIV.

FOR THE YEAR 1902.

WITH A LIST OF OFFICERS, FELLOWS, ETC.

EDITED BY

AMAND ROUTH, M.D., SENIOR SECRETARY,

AND

ALBAN DORAN, F.R.C.S.

LONDON:

LONGMANS, GREEN, AND CO.

1903.

LIBRARY
NOV 2 1 2001
UNIVERSITY OF TORONTO

PRINTED BY ADLARD AND SON, LONDON AND DORKING.

OBSTETRICAL SOCIETY OF LONDON.

OFFICERS FOR 1903.

PRESIDENT.	MALINS, EDWARD, M.D. (Birmingham).
VICE-PRESIDENTS.	BARBOUR, A. H. F., M.D. (Edinburgh). PHILLIPS, JOHN, M.A., M.D. SINCLAIR, WILLIAM JAPP, M.D. (Manchester). SPENCER, HERBERT R., M.D.
TREASURER.	HERMAN, GEORGE ERNEST, M.D.
CHAIRMAN OF THE BOARD FOR THE EXAMINATION OF MIDWIVES.	DAKIN, W. R., M.D.
HONORARY SECRETARIES.	ROUTH, AMAND, M.D. HANDFIELD-JONES, MONTAGU, M.D.
HONORARY LIBRARIAN.	BOXALL, ROBERT, M.D.
EX-OFFICIO MEMBERS OF COUNCIL.	WILLIAMS, Sir JOHN, Bart., M.D. (*Trustee and Past President.* BLACK, J. WATT, M.D. (*Trustee and Past President*). CHAMPNEYS, FRANCIS HENRY, M.D. (*Trustee and Past President*). PLAYFAIR, WILLIAM S., M.D. (*Past President*). GERVIS, HENRY, M.D. (*Past President*). GALABIN, ALFRED LEWIS, M.D. (*Past President*). HORROCKS, PETER, M.D. (*Ex-President*).
OTHER MEMBERS OF COUNCIL.	BERKELEY, COMYNS, M.B., B.C. BIGGS, JOHN M. BRIGGS, HENRY, M.B. (Liverpool). CAMERON, MURDOCH, M.D. (Glasgow). FOWLER, CHARLES OWEN, M.D. GOULLET, CHARLES ARTHUR. GRIFFITH, WALTER SPENCER ANDERSON, M.D. HART, DAVID BERRY, M.D. (Edinburgh). KEEP, ARTHUR CORRIE, M.D., C.M.Edin. LEA, ARNOLD W. W., M.D. (Manchester). LEWERS, ARTHUR H. N., M.D. POLLOCK, WILLIAM RIVERS, M.B., B.C. POPE, HARRY CAMPBELL, M.D. RAY, EDWARD REYNOLDS. STEVENS, THOMAS GEORGE, M.D. SWAYNE, WALTER C., M.D (Bristol). TAYLER, FRANCIS T., M.B. WRIGHT, CHARLES J. (Leeds).

STANDING COMMITTEES.

BOARD FOR THE EXAMINATION OF MIDWIVES.

CHAIRMAN. DAKIN, W. R., M.D.

BLACKER, GEORGE FRANCIS, M.D.
ROBERTS, CHARLES HUBERT, M.D.
EDEN, THOMAS WATTS, M.D.
STABB, ARTHUR FRANCIS, M.B.

EX-OFFICIO. MALINS, EDWARD, M.D., *President.*
ROUTH, AMAND, M.D., } *Hon. Secs.*
HANDFIELD-JONES, M., M.D., }

LIBRARY COMMITTEE.

CULLINGWORTH, CHARLES JAMES, M.D.
DORAN, ALBAN, F.R.C.S.
BLACKER, GEORGE FRANCIS, M.D.
ROBINSON, GEORGE H. DRUMMOND, M.D.
SPENCER, HERBERT R., M.D.

EX-OFFICIO. MALINS, EDWARD, M.D., *President.*
HERMAN, G. E., M.D., *Treasurer.*
ROUTH, AMAND, M.D., } *Hon. Secs.*
HANDFIELD-JONES, M., M.D., }
BOXALL, ROBERT, M.D., *Hon. Lib.*

PUBLICATION COMMITTEE.

CHAMPNEYS, FRANCIS HENRY, M.A., M.D.
McCANN, FREDERICK JOHN, M.D.
HERMAN, GEORGE ERNEST, M.B.
PHILLIPS, JOHN, M.A., M.D.
STABB, ARTHUR FRANCIS, M.B.
DORAN, ALBAN, F.R.C.S.

EX-OFFICIO. MALINS, EDWARD, M.D., *President.*
SPENCER, HERBERT R., M.D., *Editor.*
ROUTH, AMAND, M.D., } *Hon. Secs.*
HANDFIELD-JONES, M., M.D., }

FINANCE COMMITTEE.

BOULTON, PERCY, M.D.
CULLINGWORTH, CHARLES JAMES, M.D.
PHILLIPS, JOHN, M.A., M.D.
WILLIAMS, SIR JOHN, BART., M.D.
BLACK, J. WATT, M.D.
CHAMPNEYS, F. H., M.D.

EX-OFFICIO. MALINS, EDWARD, M.D., *President.*
HERMAN, G. E., M.D., *Treasurer.*
ROUTH, AMAND, M.D., } *Hon. Secs.*
HANDFIELD-JONES, M., M.D., }

PATHOLOGY COMMITTEE.

BLACKER, GEORGE FRANCIS, M.D.
DORAN, ALBAN, F.R.C.S., *Chairman.*
EDEN, THOMAS WATTS, M.D.
FAIRBAIRN, JOHN SHIELDS, M.D.
KEEP, ARTHUR CORRIE, M.D.
LOCKYER, CUTHBERT, M.D.
ROBERTS, CHARLES HUBERT, M.D.
SMITH, GUY BELLINGHAM, F.R.C.S.
SPENCER, HERBERT R., M.D.
TARGETT, JAMES HENRY, M.S.

EX-OFFICIO. MALINS, EDWARD, M.D., *President.*
ROUTH, AMAND, M.D., } *Hon. Secs.*
HANDFIELD-JONES, M., M.D., }

HONORARY LOCAL SECRETARIES.

JONES, EVAN	Aberdare.
GOSS, T. BIDDULPH	Bath.
FURNER, WILLOUGHBY	Brighton.
BRAITHWAITE, JAMES, M.D.	Leeds.
THOMPSON, JOSEPH	Nottingham.
WALKER, THOMAS JAMES, M.D.	Peterborough.
WALTERS, JAMES HOPKINS	Reading.
KEELING, JAMES HURD, M.D.	Sheffield.
BURD, EDWARD, M.D., C.M.	Shrewsbury.
TAKAKI, KANAHEIRO	Japan.

LIST OF PAST PRESIDENTS OF THE SOCIETY.

1859 EDWARD RIGBY, M.D.
1861 WILLIAM TYLER SMITH, M.D.
1863 HENRY OLDHAM, M.D.
1865 ROBERT BARNES, M.D.
1867 JOHN HALL DAVIS, M.D.
1869 GRAILY HEWITT, M.D.
1871 JOHN BRAXTON HICKS, M.D., F.R.S.
1873 EDWARD JOHN TILT, M.D.
1875 WILLIAM OVEREND PRIESTLEY, M.D.
1877 CHARLES WEST, M.D.
1879 WILLIAM S. PLAYFAIR, M.D.
1881 J. MATTHEWS DUNCAN, M.D., F.R.S.
1883 HENRY GERVIS, M.D.
1885 JOHN BAPTISTE POTTER, M.D.
1887 JOHN WILLIAMS, M.D.
1889 ALFRED LEWIS GALABIN, M.D.
1891 JAMES WATT BLACK, M.D.
1893 G. ERNEST HERMAN, M.B.
1895 F. H. CHAMPNEYS, M.A., M.D.
1897 CHARLES JAMES CULLINGWORTH, M.D.
1899 ALBAN DORAN, F.R.C.S.
1901 PETER HORROCKS, M.D.

REFEREES OF PAPERS FOR THE YEAR 1903

Appointed by the Council.

BLACK, J. WATT, M.D.
BLAND-SUTTON, J.
BOXALL, ROBERT, M.D.
CHAMPNEYS, F. H., M.A., M.D.
CULLINGWORTH, CHARLES JAMES, M.D.
DAKIN, WILLIAM RADFORD, M.D.
DORAN, ALBAN, F.R.C.S.
GALABIN, ALFRED LEWIS, M.A., M.D.
HERMAN, G. ERNEST, M.B.
HORROCKS, PETER, M.D.
LEWERS, ARTHUR H. N., M.D.
MEREDITH, W. A., M.B., C.M.
PHILLIPS, JOHN, M.A., M.D.
SPENCER, HERBERT R., M.D.
WILLIAMS, Sir JOHN, Bart., M.D,

OBSTETRICAL SOCIETY OF LONDON.

TRUSTEES OF THE SOCIETY'S PROPERTY.

Sir John Williams, Bart., M.D.
J. Watt Black, M.D.
F. H. Champneys, M.A., M.D.

HONORARY FELLOWS.

BRITISH SUBJECTS.

Elected

1899 Hutchinson, Jonathan, F.R.C.S., F.R.S., LL.D., 15, Cavendish square, W.

1892 Lister, The Right Honorable Lord, M.B., F.R.C.S., F.R.S., LL.D., 12, Park crescent, Portland place, W.

1892 Turner, Sir William, M.B., F.R.C.S., F.R.S., Principal of the University of Edinburgh; 6, Eton terrace, Edinburgh.

FOREIGN SUBJECTS.

1899 Budin, P., M.D., Professor, 4, Avenue Hoche, Paris. *Trans.* 1.

1900 Chadwick, James R., M.A., M.D., Physician for Diseases of Women, Boston City Hospital; Clarendon street, Boston, Massachusetts, U.S.

Elected

1895 Gusserow, Professor, Berlin.

1866 Lazarewitch, J., M.D., Professor Emeritus and Physician to the Maximilian Hospital; Spaskaja, 2, St. Petersburg. *Trans.* 3.

1899 Martin, A. E., M.D., Professor of Obstetrics and Gynæcology, Greifswald. *Trans.* 1.

1899 Olshausen, R. M., Professor, N. Artilleriestrasse 19, Berlin.

1899 Pinard, A., Professor, 10, Rue Cambacérés, Paris.

1872 Thomas, T. Gaillard, M.D., Professor of Obstetrics in the College of Physicians and Surgeons; 600, Madison avenue, New York.

1895 von Winckel, Professor, Sonnenstrasse 16a, Munich.

ORDINARY FELLOWS.

1903.

Those marked thus (*) have paid the Composition Fee in lieu of further annual subscriptions.

Those marked thus (†) reside beyond the London Postal District.

The letters O.F. are prefixed to the names of the "Original Fellows" of the Society.

Elected

1898 Aarons, S. Jervois, M.D.Edin., 14, Stratford place, W.

1900 Abbott, Horatio White, L.R.C.P.Lond., 66, Jackson road, Holloway, N.

1890† Ackerley, Richard, M.B., B.S.Oxon., Croft House, The Hill, Surbiton.

1891 Adams, Charles Edmund, M.R.C.S., 227, Gipsy road, West Norwood, S.E. *Council*, 1901.

1884*†Adams, Thomas Rutherford, M.D., 119, North End, West Croydon. *Council*, 1894-7.

1890 Addinsell, Augustus W., M.B., C.M.Edin., M.R.C.P., Pathologist to the Chelsea Hospital for Women, 7, Upper Brook street, W. *Council*, 1898-1900. *Trans.* 1.

1895† Albrecht, John Adolph, L.R.C.P. & S.Edin., 343, The Cliff, Lower Broughton road, Manchester.

1883*†Allan, Robert John, L.R.C.P.Ed., The Bungalow, Dulwich hill, Sydney, New South Wales.

Elected

1887 Ambrose, Robert, B.A., L.R.C.P. & S.Ed., The Mount, Mile End road, E.

1901 Amsden, Walter, L.R.C.P.Lond., 24, Fairhazel gardens, South Hampstead.

1875* Anderson, John Ford, M.D., C.M., 41, Belsize park, N.W. *Council*, 1882, 1898-9.

1899 Andrews, E. Collingwood, M.A., M.D.Cantab., 110, Finchley road, South Hampstead, N.W.

1899 Andrews, Henry Russell, M.D., M.R.C.P.Lond., 6, Cavendish place, W. *Trans.* 1.

1870*† Appleton, Robert Carlisle, M.R.C.S., The Bar House, Beverley.

1884 Appleton, Thomas A., M.R.C.S., 46, Britannia road, Fulham, S.W.

1883† Archibald, John, M.D., Hazelden, Wimborne road, Bournemouth.

1871 Argles, Frank, L.R.C.P.Ed., Hermon Lodge, Wanstead, Essex, N.E. *Council*, 1886-7.

1898† Auden, George A., M.D., B.C.Cantab., 76, Bootham, York.

1887 Bailey, Henry Frederick, M.R.C.S., The Hollies, Lee terrace, Lee, S.E.

1880† Balls-Headley, Walter, M.D., F.R.C.P., Lecturer on Obstetrics and Diseases of Women, University of Melbourne, 4, Collins street east, Melbourne, Victoria.

1869* Bantock, George Granville, M.D., Consulting Surgeon to the Samaritan Free Hospital; 12, Granville place, Portman square, W. *Council*, 1874-6. *Trans.* 2.

1886*† Barbour, A. H. Freeland, M.D.Edin., Lecturer on Midwifery and Diseases of Women, Edinburgh Medical School, 4, Charlotte square, Edinburgh. *Council*, 1898-1901. *Vice-Pres.* 1903.

1884† Barraclough, Robert W. S., M.D., Stockholme, Linton, road, Hastings.

1896 Barrett, Sidney Edward, M.B., B.C.Cantab., 56, Manor road, Stoke Newington, N.

Elected

1886† Barrington, Fourness, M.B.Edin., F.R.C.S.Eng., 213, Macquarie street, Sydney, New South Wales.

1891 Barton, Edwin Alfred, L.R.C.P.Lond., 56, Kensington Court, W.

1887† Barton, William Edwin, M.D.Durh., Amble House, Ambleside avenue, Streatham, S.W.

1861*†Bartrum, John S., F.R.C.S., Surgeon to the Bath General Hospital; 13, Gay street, Bath. *Council*, 1877-9.

1895† Beachcroft, Francis Seward, L.R.C.P.Lond., The Chains, Petworth, Sussex.

1871 Beadles, Arthur, M.R.C.S., Park House, Dartmouth Park, Forest hill, S.E.

1892 Beauchamp, Sydney, M.B., B.C.Cantab., 95, Cromwell road, S.W.

1896 Belben, Frank, M.B., F.R.C.S., Endsleigh, Suffolk road, Bournemouth.

1866*†Belcher, Henry, M.D., 28, Cromwell road, West Brighton.

1899 Belfrage, Sydney Henning, M.D.Lond., 1, Montagu place, Montagu square, W.

1871*†Bell, Robert, M.D.Glasg., 29, Lynedoch street, Glasgow.

1901 Bell, Robert Hamilton, M.B., B.C.Cantab., Stafford terrace, Kensington, W.

1889† Benson, Matthew, M.D.Brux., 35, Dicconson street, Wigan.

1894 Berkeley, Comyns, B.A., M.B., B.C.Cantab., Physician to Out-patients to Chelsea Hospital for Women; 53, Wimpole street, W. *Council*, 1902-3.

1893† Berridge, William Alfred, M.R.C.S., Oakfield, Redhill.

1883† Bertolacci, J. Hewetson, L.S.A., Beaufort House, Knap Hill, Surrey.

1889† Best, William James, M.R.C.S., 1, Cambridge terrace, Dover.

1893*†Betenson, William Betenson, L.R.C.P.Lond., Bungay, Suffolk.

Elected

1894* Betenson, Woodley Daniel, L.R.C.P.Lond., Holmdale, Woodridinge, Pinner.

1891† Beville, Frederick Wells, L.R.C.P.Lond., Sussex Lodge, Uxbridge.

1887*†Biden, Charles Walter, L.R.C.P.Lond., Laxfield, Framlingham.

1879 Biggs, J. M., M.R.C.S., L.R.C.P.Lond., Hillside, Child's hill, N.W. *Council*, 1903.

1889† Bisshopp, Francis Robert Bryant, M.A., M.B., B.C. Cantab., Belvedere, Mount Pleasant, Tunbridge Wells.

1898 Blaber, Percy Leonard, L.R.C.P.Lond., Sunny Bank, Shoot-up hill, West Hampstead.

1890† Black, George, M.B., B.S.Lond., Hurstpierpoint, Hassocks, Sussex.

1868* Black, James Watt, M.A., M.D., F.R.C.P., Obstetric Physician to the Charing Cross Hospital; 15, Clarges street, Piccadilly, W. *Council*, 1872-4. *Vice-Pres.* 1885-6. *Chairman, Board Exam. Midwives*, 1887-90. *Pres.* 1891-2. *Treas.* 1898-1901.

1893 Blacker, George Francis, M.D., B.S.Lond., F.R.C.S., Obstetric Physician to University College Hospital; 11, Wimpole street, W. *Council*, 1898-1901. *Board Exam. Midwives*, 1900-1. *Trans.* 2.

1901 Blair, G. MacLellan, M.B., B.S., 89, Goswell road, E.C.

1861*†Blake, Thomas William, M.D.St.And., Hurstbourne, Bournemouth, Hants.

1888* Bland-Sutton, John, F.R.C.S., Surgeon to the Middlesex Hospital; 47, Brook street, W. *Council*, 1894-5. *Trans.* 5.

1902† Boardman, Edith, M.D.Brux., Hyderabad, Deccan, India.

1894 Bodilly, Reginald Thomas H., L.R.C.P.Lond., Woodbury, High road, South Woodford.

Elected

1902† Bonnar, Kathleen, L.R.C.P. and S.Edin., c/o Captain J. Mackey, Medical College, Calcutta.

1883 Bonney, William Augustus, M.D., 100, Elm park gardens, Chelsea, S.W.

1900 Bonney, William Francis Victor, M.D., M.S.Lond., F.R.C.S.Eng., Assistant Physician to Chelsea Hospital for Women; 10, Devonshire street, Portland place, W.

1894† Borcherds, Walter Meent, M.R.C.S., L.R.C.P., Cathcart, Cape Colony.

1866* Boulton, Percy, M.D., Physician to the Samaritan Free Hospital; 15, Seymour street, Portman square, W. *Council*, 1878-80, 1885, 1896. *Hon. Lib.* 1886. *Hon. Sec.* 1886-9. *Vice-Pres.* 1890-2. *Board Exam. Midwives*, 1890-1. *Chairman*, 1897-1900. *Editor*, 1894-1900. *Trans.* 4.

1886† Boustead, Robinson, M.D., B.C. Cantab., Lieutenant-Colonel, Indian Medical Service; c/o Messrs. H. S. King and Co., 45, Pall Mall, S.W.

1899 Bowie, Albert W., M.B., C.M.Edin., 626, High road, Tottenham, N.

1899† Bowring, Walter Andrew, F.R.C.S.Eng., 38, Montpelier crescent, Brighton.

1884* Boxall, Robert, M.D.Cantab., Obstetric Physician to Out-patients, and Lecturer on Midwifery and Diseases of Women at the Middlesex Hospital; 40, Portland place, W. *Council*, 1888-90, 1894-5, 1899-1901. *Board Exam. Midwives*, 1891-3. *Hon. Lib.* 1902–3. *Trans.* 12.

1902 Boyd, Florence Nightingale, M.D.Brux., L.R.C.P. and S.I., 134, Harley street, W.

1897 Boyd, John Stewart, L.R.C.P.Lond., Victoria House, Custom House, E.

1884† Boys, Arthur Henry, L.R.C.P.Ed., Chequer Lawn, St. Albans.

Elected

1886† Bradbury, Harvey K., M.R.C.S., L.R.C.P., 181, Hornington street, Burton-on-Trent.

1877*†Bradley, Michael McWilliams, M.B., Jarrow-on-Tyne.

1873† Braithwaite, James, M.D., Obstetric Physician to the Leeds General Infirmary; Lecturer on Diseases of Women and Children at the Leeds School of Medicine; 16, Clarendon road, Leeds. *Vice-Pres.* 1877-9. *Hon. Loc. Sec. Trans.* 6.

1880† Branfoot, Arthur Mudge, M.B., High Ground, Bangalore.

1887 Bridger, Adolphus Edward, M.D.Ed., 18, Portland place, W.

1901† Bridgman, Harry Meilor Weaver, M.D., Woodhall Spa, Lincolnshire.

1888*†Briggs, Henry, M.B., F.R.C.S., Surgeon to the Hospital for Women, and Professor of Midwifery and Gynæcology, University College (Victoria University), Liverpool; 3, Rodney street, Liverpool. *Council*, 1901–3.

1894 Brinton, Roland Danvers, B.A., M.D.Cantab., 8, Queen's Gate terrace, S.W.

1887† Brodie, Frederick Carden, M.B., The Hutch, Sandown, Isle of Wight.

1892 Brodie, William Haig, M.D., C.M.Edin., F.R.C.S.Eng., Battle, Sussex.

1902† Brook, William Henry Breffit, M.D., B.S., F.R.C.S., 8, Eastgate, Lincoln.

1868 Brown, Andrew, M.D. St. And., 27, Lancaster road, Belsize park, N.W. *Council*, 1893-4. *Trans.* 1.

1865* Brown, D. Dyce, M.D., 29, Seymour street, Portman square, W.

1898† Brown, Haydn, L.R.C.P.Edin., Mount Nelson. King Charles road, Surbiton Hill.

Elected

1889*†Brown, William Carnegie, M.D.Aber., Glassaugh House, Portsoy, N.B.

1902 Browne, Ada Margaret, L.S.A., 64, Belsize park, N.W.

1895† Buckley, Samuel, M.D.Lond., F.R.C.S.Eng., 2, Ebor villas, Broughton park, Manchester.

1885*†Bunny, J. Brice, L.R.C.P. Ed., Warre House, Bishop's Lydeard, Taunton.

1877† Burd, Edward, M.D., M.C., Senior Physician to the Salop Infirmary; Newport House, Shrewsbury. *Council*, 1886-7. *Hon. Loc. Sec.*

1894 Burt, Robert Francis, M.B., C.M.Edin., 124, Stroud Green road, N.

1888 Burton, Herbert Campbell, L.R.C.P. Lond., Lee Park Lodge, Blackheath, S.E.

1878 Butler-Smythe, Albert Charles, F.R.C.P. & S.Ed., Surgeon to Out-patients, Samaritan Free Hospital; 76, Brook street, Grosvenor square, W. *Council*, 1889-91.

1887* Buxton, Dudley W., M.D. Lond., 82, Mortimer street, Cavendish square, W.

1886† Byers, John W., M.A., M.D., M.A.O. (Hon. Causâ), Professor of Midwifery and Diseases of Women and Children at Queen's College, and Physician for Diseases of Women to the Royal Hospital, Belfast; Dreenagh House, Lower crescent, Belfast. *Vice-Pres.* 1899-1902.

1891† Calthrop, Lionel C. Everard, M.B. Durh., Gosberton House, 76, Jesmond road, Newcastle-on-Tyne.

1887† Cameron, James Chalmers, M.D., Professor of Midwifery and Diseases of Infancy, McGill University; 941, Dorchester street, Montreal.

1887† Cameron, Murdoch, M.D.Glas., Regius Professor of Midwifery in the University of Glasgow, 7, Newton terrace, Charing Cross, Glasgow. *Council*, 1903.

Elected

1902 Campbell, Janet, M.B., B.S.Lond., Belhaven, Shepherd's hill, Highgate, N.

1894† Campbell, John, M.A., M.D.Dubl., F.R.C.S., Crescent House, University road, Belfast.

1888*†Campbell, William Macfie, M.D. Edin., 1, Princes gate East, Liverpool.

1886† Carpenter, Arthur Bristowe, M.A., M.B. Oxon., Wykeham House, Bedford park, Croydon.

1887† Case, William, M.R.C.S., Denmark house, Caister-on-Sea, Norfolk.

1901 Cater, Joseph, M.A., M.B., M.D.Brux., 43, Albemarle street, Piccadilly, W.

1876* Champneys, Francis Henry, M.A., M.D. Oxon., F.R.C.P., Physician-Accoucheur to, and Lecturer on Midwifery at, St. Bartholomew's Hospital; 42, Upper Brook street, W. *Council*, 1880-1, 1900-1. *Hon. Lib.* 1882-3. *Hon. Sec.* 1884-7. *Vice-Pres.* 1888-90. *Board Exam. Midwives*, 1883, 1888-90; *Chairman*, 1891-5. *Editor*, 1888-93. *Pres.* 1895-6. *Treas.* 1902. *Trans.* 16.

1867*†Charles, T. Edmondston, M.D., F.R.C.P., 72, Via di San Niccolo da Tolentino, Rome. *Council*, 1882-4.

1874*†Charlesworth, James, M.D., Physician to the North Staffordshire Infirmary; 25, Birch terrace, Hanley, Staffordshire.

1890† Childe, Charles Plumley, B.A., F.R.C.S., Cranleigh, Kent road, Southsea.

1897† Chinery, Edward Fluder, F.R.C.S.Edin., Monmouth House, Lymington, Hants.

1863*†Chisholm, Edwin, M.D., 44, Roslyn gardens, Sydney, New South Wales. [Per Messrs. Turner and Henderson, care of Messrs. W. Dawson, 121, Cannon street, E.C.]

1897 Clark, William Gladstone, M.A.Cantab., F.R.C.S.Eng., Civil Service Club, Capetown.

Elected

1893 Clarke, W. Bruce, F.R.C.S., Assistant Surgeon to St. Bartholomew's Hospital, 51, Harley street, W.

1899 Clayton, Charles Hollingsworth, L.R.C.P., 10, College terrace, Belsize park, N.W.

1889 Clemow, Arthur Henry Weiss, M.D., C.M.Edin., M.R.C.P.Lond., 101, Earl's Court road, Kensington, W.

1865*† Coates, Charles, M.D., Physician to the Bath General and Royal United Hospitals; 10, Circus, Bath.

1875* Coffin, Richard Jas. Maitland, F.R.C.P.Ed., 8, Wetherby terrace, Earl's Court, S.W.

1875*† Cole, Richard Beverly, M.D. Jefferson Coll. Philad., 218, Post street, San Francisco, California, U.S.

1897† Coles, Richard A., M.B. & C.M.Aber., Barham, near Canterbury.

1888 Cooper, Peter, L.R.C.P.Lond., Stainton Lodge, 35, Shooter's Hill road, Blackheath, S.E.

1875*† Cordes, Aug., M.D., M.R.C.P., Consulting Accoucheur to the "Miséricorde;" Privat Docent for Midwifery at the University of Geneva; 12, Rue Bellot, Geneva. *Trans.* 1.

1883 Corner, Cursham, L.S.A., 113, Mile End road, E.

1877 Crawford, James, M.D.Durh., Grosvenor Mansions, Victoria street, S.W.

1893 Cripps, William Harrison, F.R.C.S., Surgeon to St. Bartholomew's Hospital; 2, Stratford place, W. *Trans.* 1.

1889† Croft, Edward Octavius, M.D.Durh., Hon. Surgeon to the Hospital for Women and Children; Hon. Demonstrator of Obstetrics to the Yorkshire College, Leeds; 8, Clarendon road, Leeds. *Trans.* 1.

1881*† Cronk, Herbert George, M.B. Cantab., Repton, near Burton-on-Trent.

1893 Crosby, Herbert Thomas, M.A., M.B., B.C.Cantab., 19, Gordon square, W.C.

Elected

1895 Cross, Ernest W., L.R.C.P.Lond., The Limes, Wallwood Park, Leytonstone.

1886*†Cross, William Joseph, M.B., Horsham, Victoria, Australia.

1898† Cullen, Thomas, M.D.Toronto, Johns Hopkins Hospital, Baltimore, U S.A.

1875* Cullingworth, Charles James, M.D., D.C.L., F.R.C.P., Obstetric Physician to St. Thomas's Hospital; 14, Manchester square, W. *Council*, 1883-5, 1891-3. *Vice-Pres.* 1886-8. *Board Exam. Midwives*, 1889-91. *Chairman*, 1895-6. *Pres.* 1897-8. *Trans.* 13.

1889*†Cursetji, Jehángir J., M.D. Brux., 94, Chundunwádi, Bombay.

1894 Cutler, Lennard, L.R.C.P.Lond., 1, Kensington Gate, Kensington, W. *Trans.* 1.

1885 Dakin, William Radford, M.D., B.S., F.R.C.P., Obstetric Physician to, and Lecturer on Midwifery at, St. George's Hospital; 8, Grosvenor street, W., *Council*, 1889-91. *Hon. Lib.* 1892-3. *Hon. Sec.* 1894-7. *Vice-Pres.* 1898-1901. *Chairman*, 1901-3. *Trans.* 3.

1868 Daly, Frederick Henry, M.D., 185, Amhurst road, Hackney Downs, N.E. *Council*, 1877-9. *Vice-Pres.* 1883-5. *Trans.* 2.

1901 Daly, Frederick James Purcell, L.R.C.P.Lond., 185, Amhurst road, Hackney Downs, N.E.

1893 Dauber, John Henry, M.A. Oxon., M.B., B.Ch., Physician to the Hospital for Women, Soho square; 29, Charles street, Berkeley square, W.

1901 Davies, Hughes Reid, L.R.C.P.Lond., 196, Regent's Park road, N.W.

1892† Davis, Robert, M.R.C.S., Darrickwood, Orpington, Kent.

Elected

1877 Dawson, Smith Houston, M.D., Campden villa, 203, Maida vale, W. *Council*, 1889-91.

1891 Dawson, Ernest Rumley, L.R.C.P.Lond., The Broadway, Leyton, E. *Trans.* 1.

1889 Des Vœux, Harold A., M.D.Brux., 8, James street, Buckingham gate, S.W. *Council*, 1896-8.

1894 Dickinson, Thomas Vincent, M.D.Lond., M.R.C.P., Physician to the Italian Hospital, Queen square; 33, Sloane street, S.W. *Council*, 1900-2.

1894 Dickson, John William, B.A., M.B., B.C. Cantab., 42, Hertford street, Mayfair, W.

1886† Donald, Archibald, M.D. Edin., M.R.C.P., Obstetric Physician to the Royal Infirmary, Manchester; Honorary Surgeon to St. Mary's Hospital for Women, Manchester; Platt Abbey, Rusholme, Manchester. *Council*, 1893-5. *Trans.* 3.

1879* Doran, Alban H. G., F.R.C.S., Surgeon to the Samaritan Free Hospital; 9, Granville place, Portman square, W. *Council*, 1883-5. *Hon. Lib.* 1886-7. *Hon. Sec.* 1888-91. *Vice-Pres.* 1892-4. *Pres.* 1899-1900. *Trans.* 22.

1890† Douty, Edward Henry, M.A., M.B., B.C.Cantab., Davos Platz, Switzerland.

1887 Dovaston, Milward Edmund, M.R.C.S., Hatchcroft house, Hendon, N.W.

1899† Down, Elgar, L.R.C.P.Lond., 14, Mount Edgcumbe terrace, Stoke, Devonport.

1896 Downes, J. Lockhart, M.B., C.M. Edin., 269, Romford road, E.

1884† Doyle, E. A. Gaynes, L.R.C.P., Colonial Hospital, Port of Spain, Trinidad.

1894† Drew, Henry William, F.R.C.S., Eastgate, East Croydon.

Elected

1883 Duncan, Alexander George, M.B., 25, Amhurst park, Stamford hill, N.

1882 Duncan, William, M.D., Obstetric Physician to, and Lecturer on Obstetric Medicine at, the Middlesex Hospital; 6, Harley street, W. *Council*, 1885-6, 1888-9. *Hon. Lib.* 1890-1. *Hon. Sec.* 1892-5. *Vice-Pres.* 1896-9. *Trans.* 2.

1871* Eastes, George, M.B., F.R.C.S., 35, Gloucester terrace, Hyde park, W. *Council*, 1878-80.

1896 Easton, Frank Edward, L.R.C.P. Lond., 12, Devonport street, Hyde park, W.

1883† Eccles, F. Richard, M.D., Professor of Gynæcology, Western University; 1, Ellwood place, Queen's avenue, London, Ontario, Canada.

1893 Eden, Thomas Watts, M.D.Edin., M.R.C.P.Lond., Assistant Obstetric Physician to, and Lecturer on Practical Midwifery at, Charing Cross Hospital, 26, Queen Anne street, W. *Council*, 1897-9. *Trans.* 4.

1901† Ellis, Francis Hamilton, M.B., B.C.Cantab., Grove Hospital, Tooting Grove, Tooting Graveney, S.W.

1894 Ellis, Robert Kingdon, M.B., B.Ch.Oxon., Lowdham, Notts.

1873*† Engelmann, George Julius, A.M., M.D., 336, Beacon street, Boston, Mass., U.S.A.

1898† Evans, David J., M.D.McGill, 939, Dorchester street, Montreal.

1897 Evans, Evan Laming, M.B., B.C.Cantab., F.R.C.S., 116 Piccadilly, W.

1875† Ewart, John Henry, M.R.C.S., L.R.C.P., Eastney, Devonshire place, Eastbourne.

1899 Fairbairn, John Shields, M.D., B.Ch.Oxon., Assistant Obstetric Physician to St. Thomas's Hospital, 60, Wimpole street, W. *Trans.* 1.

Elected

1894 Fairweather, David, M.A., M.D., C.M.Edin., Carlton Lodge, Palmerston road, Bowes Park, N.

1876† Farncombe, Richard, M.D.Brux., 183, Belgrave road, Balsall heath, Birmingham.

1869* Farquhar, William, M.D., Deputy Surgeon-General, 40, Westbourne gardens, Bayswater, W.

1882† Farrar, Joseph, M.D., Gainsborough. *Trans.* 1.

1894† Fazan, Charles Herbert, L.R.C.P. Lond., Belmont, Wadhurst, Sussex.

1868* Fegan, Richard, M.D., Westcombe park, Blackheath, S.E.

1883 Fenton, Hugh, M.D., Physician, Chelsea Hospital for Women; 27 George street, Hanover square, W.

1901 Ferguson, George Bagot, M.D., B.Ch.Oxon, Altidore Villa, Pittville, Cheltenham.

1893† Finley, Harry, M.D.Lond., West Malvern, Worcestershire.

1877*†Fonmartin, Henry de, M.D., 26, Newberry terrace, Lower Bullar street, Nichols Town, Southampton.

1897† Fothergill, W. E., M.B., C.M.Edin., 200, Oxford road, Manchester.

1884 Fouracre, Robert Perriman, M.R.C.S., 58, Tollington park, N.

1886† Fowler, Charles Owen, M.D., Cotford House, Thornton heath. *Council*, 1901–3.

1898 Frampton, Trevethan, M.R.C.S., F.R.C.P., 168, Gloucester terrace, Hyde park, W.

1875*†Fraser, Angus, M.D., Physician and Lecturer on Clinical Medicine to the Aberdeen Royal Infirmary; 232, Union street, Aberdeen. *Council*, 1897-1900.

1888† Fraser, James Alexander, L.R.C.P. Lond., Western Lodge, Romford.

Elected

1902† Freeland, Arthur Raymond Stilwell, L.R.C.P., M.R.C.S., St. John's Cottage, Leatherhead.

1883 Fuller, Henry Roxburgh, M.D. Cantab., 45, Curzon street, Mayfair, W. *Council*, 1893. *Trans.* 1.

1886† Furner, Willoughby, F.R.C.S., 13, Brunswick square, Brighton. *Council*, 1894-6. *Hon. Loc. Sec.*

1874* Galabin, Alfred Lewis, M.A., M.D., F.R.C.P., Obstetric Physician to, and Lecturer on Midwifery at, Guy's Hospital; 49, Wimpole street, Cavendish square, W. *Council*, 1876-8. *Hon. Lib.* 1879. *Hon. Sec.* 1880-3. *Vice-Pres.* 1884. *Treas.* 1885-8. *Pres.* 1889-90. *Trans.* 12.

1888 Galloway, Arthur Wilton, L.R.C.P. Lond., 79, New North road, N.

1863* Galton, John H., M.D., Chunam, Sylvan road, Upper Norwood, S.E. *Council*, 1874-6, 1891-2. *Vice-Pres.* 1895-8.

1881 Gandy, William, M.R.C.S., Hill Top, Central hill, Norwood, S.E. *Council*, 1897-8.

1886*†Garde, Henry Croker, F.R.C.S. Edin., Maryborough, Queensland.

1887 Gardiner, Bruce H. J., L.R.C.P. Ed., Gloucester House, Barry road, East Dulwich, S.E.

1894 Gardner, H. Bellamy, M.R.C.S., L.R.C.P.Lond., 52, Beaumont street, Portland place, W.

1872*†Gardner, William, M.A., M.D., Professor of Gynæcology, McGill University; Gynæcologist to the Royal Victoria Hospital; 109, Union avenue, Montreal, Canada.

1876† Garner, John, M.R.C.S., 21, Easy row, Birmingham.

1891† Garrett, Arthur Edward, L.R.C.S. & L.M.Ed., Dalkeith House, Leamington.

1873*†Garton, William, M.D., F.R.C.S., Inglewood, Aughton, ear Ormskirk.

Elected

1901 Gayer, Reginald Courtenay, L.R.C.P., 13, Rosary gardens, South Kensington, S.W.

1889* Gell, Henry Willingham, M.A., M.B. Oxon., 36, Hyde park square, W.

1898*† Gemmell, John Edward, M.B., C.M.Edin., Hon. Surgeon to the Hospital for Women, Liverpool; 12, Rodney street, Liverpool.

1902 George, Jessie, L.R.C.P., L.R.C.S.Edin., 42, Marsden street, Calcutta, India.

1859* Gervis, Henry, M.D., F.R.C.P., Consulting Obstetric Physician to St. Thomas's Hospital; The Towers, Hillingdon, Uxbridge. *Council*, 1864-6, 1889-91, 1893. *Hon. Sec.* 1867-70. *Vice-Pres.* 1871-3. *Treas.* 1878-81. *Pres.* 1883-4. *Trans.* 8.

1866* Gervis, Frederick Heudebourck, M.D.Brux., 1, Fellows road, Haverstock hill, N.W. *Council*, 1877-9. *Vice-Pres.* 1892. *Trans.* 1.

1899† Gervis, Henry, M.A., M.B., B.C.Cantab., 74, Dyke road, Brighton.

1883* Gibbons, Robert Alexander, M.D., Physician to the Grosvenor Hospital for Women and Children; 29, Cadogan place, S.W. *Council*, 1889-90. *Trans.* 1.

1894 Gibson, Henry Wilkes, L.R.C.P. Lond., 6, College terrace, Fitzjohn's avenue, N.W.

1892 Giles, Arthur Edward, M.D. Lond., M.R.C.P., Physician to Out-patients, Chelsea Hospital for Women; 10, Upper Wimpole street, W. *Council*, 1898-1900. *Trans.* 7.

1869 Gill, William, L.R.C.P. Lond., 11, Russell square, W.C.

1891 Gimblett, William Henry, M.D.Durh., Queen's road, Buckhurst hill, Essex.

1899† Glover, Thomas Anderson, M.D., C.M.Edin., 24, Hallgate, Doncaster.

Elected

1894† Goddard, Charles Ernest, M.D., Wembley, Harrow.

1871 *Godson, Clement, M.D., C.M.; 82, Brook street, W. *Council*, 1876-7. *Hon. Sec.* 1878-81. *Vice-Pres.* 1882-4. *Board Exam. Midwives*, 1877, 1882-86. *Trans.* 5.

1893† Goodman, Roger Neville, M.A., M.B.Cantab., Thursley, Kingston Hill.

1893† Gordon, Frederick William, L.R.C.P.Lond., Manukau road, Auckland, New Zealand.

1883 Gordon, John, M.D., 63, Cheapside, E.C.

1869† Goss, Tregenna Biddulph, M.R.C.S., 1, The Circus, Bath. *Hon. Loc. Sec.*

1891† Gostling, William Ayton, M.D., B.S.Lond., Barningham, West Worthing.

1889 Goullet, Charles Arthur, L.R.C.P.Lond., 2, Finchley road, N.W. *Council* 1902–3.

1890 Gow, William John, M.D.Lond., Physician-Accoucheur in charge of Out-patients, St. Mary's Hospital; 27, Weymouth street, W. *Council*, 1893-5-1901. *Board Exam. Midwives*, 1898-1900-1. *Trans.* 2.

1893† Gowan, Bowie Campbell, L.R.C.P.Lond., Raven Dene, Great Stanmore.

1893 Grant, Leonard, M.D.Edin., Hillside, New Southgate, N.

1902† Grech, Salvatore, M.D.Malta, Margherita House, Cospicua, Malta.

1894† Green, Charles Robert Mortimer, F.R.C.S.Eng., Major, Indian Medical Service, c/o Inspector-General of Civil Hospitals, Bengal.

1887 Greenwood, Edwin Climson, L.R.C.P., 19, St. John's wood park, N.W.

1863 *Griffith, G. de Gorrequer, M.R.C.S., L.R.C.P., 34, St. George's square, S.W. *Trans.* 2.

Elected

1879* Griffith, Walter Spencer Anderson, M.D. Cantab., F.R.C.S., F.R.C.P., Assistant Physician-Accoucheur to St. Bartholomew's Hospital; 96, Harley street, W. *Council*, 1886-8, 1893-5, 1901-3. *Hon. Lib.* 1896-7. *Board Exam. Midwives*, 1887-9. *Trans.* 10.

1888*†Grimsdale, Thomas Babington, B.A., M.B. Cantab., Surgeon to the Hospital for Women, and Medical Officer to the Liverpool Lying-in Hospital; 29, Rodney street, Liverpool.

1880 Grogono, Walter Atkins, M.R.C.S., L.R.C.P., Berwick House, Broadway, Stratford, E.

1896† Groves, Ernest W., M.B., B.Sc., Kingswood, Bristol. *Trans.* 1.

1881† Hair, James, M.D., Brinklow, Coventry.

1894 Hamilton, Bruce, L.R.C.P. Lond., "Falklands," 9, Frognal, N.W.

1887† Hamilton, John, F.R.C.S.Ed., Beechhurst House, Swadlincote, Burton-on-Trent.

1883 Handfield-Jones, Montagu, M.D. Lond., F.R.C.P., Physician-Accoucheur to, and Lecturer on Midwifery and Diseases of Women at, St. Mary's Hospital; 35, Cavendish square, W. *Council*, 1887-9, 1896-7. *Board Exam. Midwives*, 1894-6. *Hon. Lib.* 1900-3. *Trans.* 1.

1901 Handley, William Sampson, M.S., M.D. Lond., F.R.C.S.Eng., 51, Devonshire street, Portland place, W. *Trans.* 1.

1886† Hardy, Henry L. P., M.D. Brux., Stroud, Gloucestershire.

1892 Harold, John, M.B., B.Ch., B.A.O., 91, Harley street, W.

1877 Harper, Gerald S., M.B. Aber., 40, Curzon street, Mayfair, W. *Council*, 1894-5.

1898† Harper, John Robinson, L.R.C.P., Redcot, Barnstaple, Devon.

Elected

1878† Harries, Thomas Davies, F.R.C.S., Grosvenor House, Aberystwith, Cardiganshire.

1867* Harris, William H., M.D., Deputy Surgeon-General, Shirley, Parklands, Surbiton.

1880* Harrison, Richard Charlton, M.R.C.S., L.R.C.P., 19, Uxbridge road, Ealing, W.

1890† Hart, David Berry, M.D.Edin., Assistant Gynæcologist, Royal Infirmary, Edinburgh; 29, Charlotte square, Edinburgh. *Council* 1902–3.

1886† Hartley, Horace, L.R.C.P. Ed., Stone, Staffordshire.

1886 Hartley, Reginald, M.D. Durh., F.R.C.S.Ed., 68, Porchester terrace, Hyde park, W.

1893† Harvey, John Jordan, L.R.C.P. & S.Edin., 54, Barking road, Canning Town, E.

1880 Harvey, John Stephenson Selwyn, M.D.Durh., M.R.C.P., 1, Astwood road, Cromwell road, S.W.

1899† Hawes, Godfrey Charles Browne, L.R.C.P., Pangbourne.

1899*† Hawkes, Claude Somerville, L.R.C.P., Swansea place, Wickham Terrace, Brisbane, Queensland.

1893† Haydon, Thomas Horatio, M.B., B.C. Cantab., 22, High street, Marlborough.

1900 Hayford, Ernest James, M.D., c/o The Agent, Claude's Ashanti Goldfields, Ltd., Cape Coast Castle, Gold Coast, West Africa.

1901† Haynes, Edward James Ambrose, F.R.C.S.I., Weetalabah, Hay street west, Perth, Western Australia.

1880 Heath, William Lenton, M.D., 90, Cromwell road, Queen's gate, S.W. *Council*, 1891. *Trans.* 1.

1892† Hellier, John Benjamin, M.D.Lond., Lecturer on Diseases of Women and Children, Yorkshire College; Hon. Obstetric Physician to Leeds Infirmary; 27, Park square, Leeds.

Elected

1890† Helme, T. Arthur, M.D.Edin., M.R.C.P., Senior Assistant Surgeon to the Manchester Clinical Hospital for Women and Children, 3, St. Peter's square, Manchester.

1867† Hembrough, John William, M.D., The Moot Hall, Newcastle-on-Tyne.

1876* Herman, George Ernest, M.B., F.R.C.P., Obstetric Physician to, and Lecturer on Midwifery at, the London Hospital; 20, Harley street, Cavendish square, W. *Council*, 1878-9, 1898-1901. *Hon. Lib.* 1880-1. *Hon. Sec.* 1882-5. *Vice-Pres.* 1886-7. *Board Exam. Midwives*, 1886-8. *Treas.* 1889-92, 1903. *Pres.* 1893-4. *Trans.* 33.

1901 Hilliard, Francis Porteus Tyrrell, M.A., M.B.Oxon., London Hospital, E.

1898 Hindley, Godfrey D., L.R.C.P.Lond., 11, Gwendolen avenue, Putney.

1886† Hodges, Herbert Chamney, L.R.C.P.Lond., Watton-at-Stone, Herts. *Trans.* 1.

1886† Holberton, Henry Nelson, L.R.C.P.Lond., East Molesey.

1875 Hollings, Edwin, M.D., 22, Endsleigh gardens, N.W. *Council*, 1888-90. *Vice-Pres.* 1893-4.

1897 Hollings, Guy Bertram, M.D., B.S., 22, Endsleigh gardens, N.W.

1859 Holman, Constantine, M.D., 26, Gloucester place, Portman square, W. *Council*, 1867-9, 1895-6. *Vice-Pres.* 1870-1.

1891† Holman, Robert Colgate, M.R.C.S., Whithorne House, Midhurst, Sussex.

1864* Hood, Wharton Peter, M.D., 11, Seymour street, Portman square, W.

1896† Hopkins, George Herbert, F.R.C.S., 3, North Quay, Brisbane, Queensland.

Elected

1883* Horrocks, Peter, M.D., F.R.C.P.Lond., Obstetric Physician to Guy's Hospital; 42, Brook street, W. *Council*, 1886-7. *Hon. Lib.* 1888-9. *Hon. Sec.* 1890-3. *Vice-Pres.* 1894-6. *Pres.* 1901–2. *Trans.* 2.

1876 Horsman, Godfrey Charles, L.S.A., 22, King street, Portman square, W.

1883 Hoskin, Theophilus, L.R.C.P. Lond., 1, Amhurst park, N.

1884† Hough, Charles Henry, M.R.C.S., Full street, Derby.

1879† Hubbard, Thomas Wells, L.R.C.P., L.R.C.S., Barming place, Maidstone.

1901 Humphreys, Francis Rowland, L.R.C.P.Lond., 27, Fellows road, N.W.

1884*†Hurry, Jamieson Boyd, M.D. Cantab., 43, Castle street, Reading. *Council*, 1887-9. *Vice.-Pres.* 1897-1900. *Trans.* 2.

1878* Husband, Walter Edward, M.R.C.S., L.R.C.P., Grove Lea, Lansdown, Bath.

1895 Huxley, Henry, L.R.C.P.Lond., 39, Leinster gardens, Hyde park, W.

1894† Ilott, Herbert James, M.D. Aber., 57, High street, Bromley, Kent.

1901† Inglis, Arthur Stephen, M.D.Aber., 5, Pevensey road, St. Leonards-on-sea.

1902 Inglis, John, M.D., 18, Cornwallis gardens, Hastings.

1902† Ionides, Theodore Henry, M.B., B.S.Lond., 25, First avenue, Brighton.

1884*†Irwin, John Arthur, M.A., M.D., 14, West Twenty-ninth street, New York.

1883† Jackson, George Henry, M.R.C.S., Ashburton, Carew road, Eastbourne.

1897 Jäger, Harold, M.B. Lond., 6, Darnley road, Royal crescent, W.

Elected

1873† Jakins, William Vosper, L.R.C.P. Ed., 14, Collins street East, Melbourne.

1890† James, Charles Henry, L.R.C.P.Lond., Captain, Indian Medical Service; Lahore, Punjab, India.

1883*†Jenkins, Edward Johnstone, M.D. Oxon., 213, Macquarie street, Sydney.

1877† Jenks, Edward W., M.D., 84, Lafayette avenue, Detroit, Michigan, U.S.

1882* Jennings, Charles Egerton, M.D. Durh., F.R.C.S. Eng., Assistant Surgeon to the North-West London Hospital; Burke House, Beaconsfield.

1901*†Johnson, Edward Angus, M.B., B.S.Melb., L.R.C.P. Lond., "St. Catharine's" Prospect, South Australia.

1900 Johnson, Henry Heath Pochin, L.R.C.P., Ferry Hill, near Durham.

1868† Jones, Evan, M.R.C.S., Ty-Mawr, Aberdare, Glamorganshire. *Council*, 1886-8. *Vice.-Pres.* 1890-1. *Hon. Loc. Sec.*

1894 Jones, Evan, L.R.C.P. Lond., 89, Goswell road, E.C.

1902† Jones, Evan James Trevor, M.D.Brux., Ty-Mawr, Aberdare, Glamorganshire.

1895† Jones, George Horatio, M.R.C.S., Deddington, Oxon.

1894† Jones, John Arnallt, L.R.C.P. Lond., Heathmont, Aberavon, Port Talbot, Glamorganshire.

1887† Jones, J. Talfourd, M.B. Lond. Consulting Physician to the Breconshire Infirmary, St. David's, 1, Lascelles terrace, Eastbourne.

1873† Jones, Philip W., M.R.C.S., L.R.C.P., River House, Enfield.

1886† Jones, William Owen, M.R.C.S., The Downs, Bowdon, Cheshire.

1884 Keates, William Cooper, L.R.C.P., 20, East Dulwich road, S.E.

1883† Keeling, James Hurd, M.D., 267, Glossop road, Sheffield. *Hon. Loc. Sec.*

Elected

1896 KEEP, ARTHUR CORRIE, M.D., C.M.Edin., Surgeon to Out-patients to the Samaritan Free Hospital; 14, Gloucester place, Portman square, W. *Council*, 1902-3.

1894 KELLETT, ALFRED FEATHERSTONE, M.B., B.C.Cantab., 142, Lewisham road, S.E.

1874* KEMPSTER, WILLIAM HENRY, M.D., Chesterfield, Clapham common, North side, S.W.

1886 KENNEDY, ALFRED EDMUND, L.R.C.P. Ed., Chesterton House, Plaistow, E.

1879 KER, HUGH RICHARD, L.R.C.P.Ed., Tintern, 2, Balham hill, S.W.

1895† KERR, JOHN MARTIN MUNRO, M.B., C.M.Glasg.; Obstetric Physician to the Glasgow Maternity Hospital; 28, Berkeley terrace, Glasgow. *Trans.* 1.

1877*†KERSWILL, JOHN BEDFORD, M.R.C.P. Ed., Fairfield, St. German's, Cornwall.

1878† KHORY, RUSTONJEE NASERWANJEE, M.D., M.R.C.P., Medical Syndic, Bombay University; Honorary Physician, Bai Motlibai Obstetric and Gynæcological Hospital; Hormazd Villa, Khumballa hill, Bombay.

O.F.* KIALLMARK, HENRY WALTER, M.R.C.S., 5, Pembridge gardens, Bayswater. *Council*, 1879-80.

1872* KISCH, ALBERT, M.R.C.S., 61, Portsdown road, W. *Council*, 1896-7.

1876*†KNOTT, CHARLES, M.R.C.P. Ed., Liz Ville, Elm grove, Southsea.

1889 LAKE, GEORGE ROBERT, M.R.C.S., 177, Gloucester terrace, Hyde park, W.

1867* LANGFORD, CHARLES P., M.R.C.S., Sunnyside, Hornsey lane, N.

1894† LEA, ARNOLD W. W., M.D., B.S.Lond., F.R.C.S., Lecturer on Midwifery and Diseases of Women, Owens College; 274, Oxford road, Manchester. *Council*, 1903. *Trans.* 2.

1901 LEAHY-LYNCH, TIMOTHY, L.R.C.P., L.M.Edin., 2, Finsbury park road, N.

1884*†LEDIARD, HENRY AMBROSE, M.D., 35, Lowther street, Carlisle. *Council*, 1890-2. *Trans.* 1.

Elected

1902† Lendon, Alfred Austin, M.D.Lond., North terrace, Adelaide, South Australia.

1897 Leslie, William Murray, M.D. Edin., 74, Cadogan place, Belgrave square, S.W.

1900* Levison, Hugo Adolf, M.D.(Columbia Univ.), L.R.C.P. Lond., 44, West 35th street, New York.

1885 Lewers, Arthur H. N., M.D. Lond., F.R.C.P., Obstetric Physician to the London Hospital; 72, Harley street, W. *Council*, 1887-9, 1893, 1901-3. *Board Exam. Midwives*, 1895-7. *Trans.* 13.

1902 Lewis, Ernest Wool, L.R.C.P., M.R.C.S., The Hermitage, Fulham Palace road, S.W.

1901† Littlewood, Harry, F.R.C.S., 25, Park square, Leeds. *Trans.* 1.

1894 Livermore, William Leppingwell, L.R.C.P. Lond., 52, Stapleton Hall road, Stroud green, N.

1899 Lockyer, Cuthbert, M.D., B.S.Lond., F.R.C.S., 117a, Harley street, W. *Trans.* 3.

1893† Logan, Roderic Robert Walter, M.R.C.S., Church street, Ashby-de-la-Zouch.

1893† Lowe, Walter George, M.D. Lond., F.R.C.S., Burton-on-Trent.

1878*† Lycett, John Allan, M.D., Gatcombe, Consulting Gynæcologist to the Wolverhampton and District Hospital for Women, Wolverhampton.

1902† Lynn, Edward, M.R.C.S., 638, Woolwich road, New Charlton, Kent.

1896† Lyons, A., M.B., Thames Ditton.

1871† McCallum, Duncan Campbell, M.D., Emeritus Professor McGill University; 45, Union avenue, Montreal, Canada. *Trans.* 4.

1890 McCann, Frederick John, M.D., C.M.Edin., F.R.C.S. Eng., M.R.C.P., Physician to In-patients at the Samaritan Hospital; 5, Curzon street, Mayfair, W. *Council*, 1897-8. *Trans.* 3.

Elected

1894† McCausland, Albert Stanley, M.D. Brux., Churchill House, Swanage.

1890 McCaw, J. Dysart, M.D., F.R.C.S., Wallington, Surrey. *Council*, 1898-1900.

1894† McDonnell, Æneas John, M.D., Ch.M. Sydney, Toowoomba, Queensland.

1896 M'Donnell, W. Campbell, L.R.C.P. Lond., Park House, Park lane, Stoke Newington, N.

1892† McKay, W. J. Stewart, M.B., M.Ch.Sydney, Australian Club, Macquarie street, Sydney, N.S.W.

1897† McKerron, Robert Gordon, M.B. Aberd., 1, Albyn place, Aberdeen. *Trans.* 2.

1900† Macan, Jameson John, M.A., M.D.Cantab., Crossgates, Cheam, Surrey.

1893 Maclean, Ewen John, M.D., F.R.S.Edin., M.R.C.P.Lond., Senior Gynæcologist to Cardiff Infirmary; 12, Park place, Cardiff. *Council*, 1900.

1899 Macleod, William Aitken, M.B., C.M.Edin., 9, Pembridge villas, Bayswater, W.

1902 McMahon-Dillon, H. V., Capt. R.A.M.C., L.R.C.S.I., 2, Scarsdale Villas, Kensington.

1886 McMullen, William, L.K.Q.C.P.I., 319A, Brixton road, S.W.

1878*†Macnaughton-Jones, H., M.D., M.A.O. (Hon. Causâ), F.R.C.S.I. & Edin., 131, Harley street, Cavendish square, W. *Trans.* 1.

1898 Macnaughton-Jones, Henry, M.B., B.Ch., 12, Sandwell mansions, West End lane, N.W.

1894† McOscar, John, L.R.C.P.Lond., The Shrubbery, Woking.

1899† Maguire, George J., M.B., B.Ch., Kew road, Richmond.

1895† Maidlow, William Harvey, M.D.Durh., F.R.C.S.Eng., Ilminster, Somerset.

1884 Malcolm, John D., M.B., C.M., Surgeon to the Samaritan Free Hospital; 13, Portman street, W. *Council*, 1894-6.

Elected

1871† Malins, Edward, M.D., Obstetric Physician to the General Hospital, Professor of Midwifery at Mason College, Birmingham ; 50, Newhall street, Birmingham. *Council*, 1881-3. *Vice-Pres.* 1884-6, 1901-2. *Pres.* 1903. *Hon. Loc. Sec.*

1868*†March, Henry Colley, M.D., Portisham, Dorchester. *Council*, 1890-2.

1887 Mark, Leonard P., M.D.Durh., 61, Cambridge street, Hyde-park, W.

1860† Marley, Henry Frederick, M.R.C.S., L.R.C.P., The Nook, Padstow, Cornwall.

1862*†Marriott, Robert Buchanan, M.R.C.S., Swaffham, Norfolk.

1887† Marsh, O. E. Bulwer, L.R.C.P. Ed., Parkdale, Clytha park, Newport, Monmouthshire.

1890† Martin, Christopher, M.B., C.M.Edin., F.R.C.S.Eng., Surgeon to the Birmingham and Midland Hospital for Women ; 35, George road, Edgbaston, Birmingham. *Trans.* 1.

1883† Maurice, Oliver Calley, M.D.Heidelb., 75, London street, Reading. *Council*, 1888-90.

1899† Maxwell, John Preston, M.B.Lond., F.R.C.S., Changhoo, c/o E. P. Mission, Amoy, China. *Trans.* 1.

1890 May, Chichester Gould, M.A., M.D.Cantab., Assistant Physician to the Grosvenor Hospital for Women and Children ; 59, Cadogan place, S.W.

1884† Maynard, Edward Charles, L.R.C.P.Ed., Arundel lodge Worthing.

1886 Mennell, Zebulon, M.R.C.S., 1, Royal crescent, Notting hill, W.

1898 Menzies, Henry, M.B.Cantab., 4, Ashley gardens, S.W.

1882 Meredith, William Appleton, M.B., C.M., F.R.C.S.Eng., Surgeon to the Samaritan Free Hospital for Women and Children ; 21, Manchester Square, W. *Council*, 1886-8. *Vice-Pres.* 1891-3. *Trans.* 3.

Elected

1893† Michie, Harry, M.B. Aber., 27, Regent street, Nottingham.

1875*†Miles, Abijah J., M.D., Professor of Diseases of Women and Children in the Cincinnati College of Medicine, Cincinnati, Ohio, U.S.

1895† Miller, James Thomas Roger, L.S.A., Castlegate House, Malton, Yorkshire.

1902 Milligan, Wyndham Anstruther, M.B., C.M. Aber., 104, Bethune road, N.

1876* Millman, Thomas, M.D., 59, Yonge street, Toronto, Ontario, Canada.

1880† Mills, Robert James, M.B., M.C., 35, Surrey street, Norwich.

1892† Milton, Herbert M. Nelson, M.R.C.S., Kasr-el-Aini Hospital, Cairo, Egypt.

1869*†Minns, Pembroke R. J. B., M.D., Thetford, Norfolk.

1867* Mitchell, Robert Nathal, M.D., Brookwood, Hollington, St. Leonard's-on-Sea.

1877 Moon, Frederick, M.B., 20, Bryanston street, Portman square, W.

1859† Moorhead, John, M.D., Surgeon to the Weymouth Infirmary and Dispensary; Weymouth, Dorset.

1895 Morison, Henry Bannermann, M.B. Durh., Lindley Lodge, Mottingham, Eltham, S.E.

1890 Morris, Charles Arthur, M.A., M.B., B.C. Cantab., F.R.C.S., 29, Eccleston street, Eaton square, S.W.

1883 Morris, Clarke Kelly, M.R.C.S., Gordon Lodge, Charlton road, Blackheath, S.E.

1899 Morris, Edwin Hugh Grant, M.B., B.C. Cantab., 47 Onslow gardens, S.W.

1893† Morse, Thomas Herbert, F.R.C.S., All Saints' green, Norwich. *Trans.* 1.

1896 Mugford, Sidney Arthur, L.R.C.P., 135, Kennington park road, S.E.

Elected

1893 Muir, Robert Douglas, M.D., The Limes, New Cross road, S.E.

1896† Murphy, James Keogh, M.A., M.D., B.C.Cantab., 35, Princes square, Bayswater, W.

1885 Murray, Charles Stormont, L.R.C.S. and L.M.Ed., 85, Gloucester place, Portman square, W.

1893† Murray, Robert Milne, M.B. Edin., 11, Chester street, Edinburgh.

1893† Nairne, John Stuart, F.R.C.S. Ed., 141, Hill street, Garnethill, Glasgow.

1887 Napier, A. D. Leith, M.D. Aber., M.R.C.P. Lond., F.R.S.Edin., North terrace, East Adelaide, South Australia. *Trans.* 2.

1896† Nariman, R. T., M.D. Brux., Parsi Lying-in Hospital, Bombay.

1902† Nariman, Temulfi Bhicafi, L.M.&F.Bombay, Bombay, India.

1892† Nash, W. Gifford, F.R.C.S., Senior Surgeon to the Bedford County Hospital, Clavering House, De Parys avenue, Bedford.

1902† Newland, H. Simpson, M.B.Adel., F.R.C.S.Eng., Adelaide, South Australia.

1859*† Newman, William, M.D., Surgeon to the Stamford and Rutland Infirmary; Barn Hill House, Stamford, Lincolnshire. *Council*, 1873-5. *Vice-Pres.* 1876-7. *Trans.* 5.

1889† Newnham, William Harry Christopher, M.A., M.B. Cantab., Physician-Accoucheur to the Bristol General Hospital; Chandos Villa, Queen's road, Clifton, Bristol.

1895† Newstead, James, M.R.C.S., 9, York place, Clifton, Bristol.

1893† Nichol, Frank Edward, M.A., M.B., B.C. Cantab., 11, Ethelbert Terrace, Margate.

1873† Nicholson, Arthur, M.B. Lond., 30, Brunswick square, Brighton. *Council*, 1897-9.

1876* Nix, Edward James, M.D., 11, Weymouth street, W. *Council*, 1889-90.

Elected

1882† Norman, John Edward, M.D.Durham, Lismore House, Hebburn-on-Tyne.

1888 Oliver, Franklin Hewitt, L.R.C.P. Lond., 2, Kingsland road, N.E.

1899† Osborn, Francis Arthur, L.R.C.P.Lond., Ennismore House, Dover.

1877† Osterloh, Paul Rudolph, M.D. Leipzic, Physician for Diseases of Women, Diaconissen Hospital; Wienerstrasse 8, Dresden.

1892 Owen, Samuel Walshe, L.R.C.P.Lond., 10, Shepherd's Bush road, W.

1902 Oxley, Alfred James Rice, M.D.Dubl., 7, Courtfield road, S.W.

1889* Page, Harry Marmaduke, M.D.Brux., F.R.C.S., 14, Grenville place, S.W.

1891† Page, Herbert Markant, M.D.Brux., 16, Prospect hill, Redditch.

1877* Paramore, Richard, M.D., 2, Gordon square, W.C.

1867*† Parks, John, M.R.C.S., Bank House, Manchester road, Bury, Lancashire.

1887 Parsons, John Inglis, M.D.Durh., M.R.C.P., Physician to Out Patients, Chelsea Hospital for Women, 3, Queen street, Mayfair, W. *Trans.* 2.

1880 Parsons, Sidney, M.R.C.S., 78, Kensington Park road, W.

1865*† Paterson, James, M.D., Hayburn Bank, Partick, Glasgow.

1899 Paul, J. E., M.D., 26, Queensborough terrace, Bayswater, W.

1902 Payne, Edward Marten, M.B., C.M., 38, Chichele road, Cricklewood, N.W.

1882* Peacey, William, M.D., Rydal Mount, St. John's road, Eastbourne.

1894 Peake, Solomon, M.R.C.S., 118, Percy road, Shepherd's Bush, W.

1899 Peck, Francis Samuel, M.R.C.S.Eng., Major, Indian Medical Service; 6, Harington street, Calcutta.

1871* Pedler, George Henry, M.R.C.S., L.R.C.P., 6, Trevor terrace, Rutland gate, S.W. *Council*, 1897-8.

Elected

1880*†Pedley, Thomas Franklin, M.D., Rangoon, India. *Trans.* 1.

1898 Penny, Alfred Gervase, M.A., M.B., B.C.Cantab., Queen's Avenue, Muswell Hill, N.

1881† Perigal, Arthur, M.D., New Barnet, Herts. *Council*, 1892–3.

1893 Perkins, George C. Steele, M.D., 85, Wimpole street, W.

1879*†Pesikaka, Hormasji Dosabhai, 23, Hornby row, Bombay.

1894 Petty, David, M.B., C.M.Edin., 6, High road, South Tottenham, N.E.

1879 Phillips, George Richard Turner, M.R.C.S., 28, Palace court, Bayswater hill, W. *Council*, 1891.

1882 Phillips, John, M.A., M.D. Cantab., F.R.C.P., Obstetric Physician to King's College Hospital, and Lecturer on Practical Obstetrics in King's College; 68, Brook street, W. *Council*, 1887-9, 1893. *Hon. Lib.* 1894-5. *Hon. Sec.* 1896-9. *Board Exam. Midwives*, 1892-4. *Vice-Pres.* 1900-3. *Trans.* 11.

1897 Phillips, Llewellyn C. P., M.B., B.C. Cantab., St. Bartholomew's Hospital, E.C.

1878* Philpot, Joseph Henry, M.D., 61, Chester square, S.W. *Council*, 1891.

1889† Pinhorn, Richard, L.R.C.P. Lond., 5, Cambridge terrace, Dover. *Council*, 1897-9.

1893 Playfair, Hugh James Moon, M.D.Lond., Assistant Physician, Hospital for Women and Children, Waterloo road; 7, Upper Brook street, Grosvenor square, W. *Council*, 1900.

1864* Playfair, W. S., M.D., LL.D., F.R.C.P., Physician-Accoucheur to H.I. & R.H. the Duchess of Edinburgh; Consulting Obstetric Physician to King's College Hospital, West Green Manor, Winchfield, Hants. *Council*, 1867, 1883-5. *Hon. Librarian*, 1868-9. *Hon. Sec.* 1870-72. *Vice-Pres.* 1873-5. *Pres.* 1879-80. *Trans.* 15.

Elected

1891* Pollock, William Rivers, M.B., B.C.Cantab., Assistant Obstetric Physician to the Westminster Hospital, 56, Park street, Grosvenor square, W. *Council*, 1895-7, 1902-3. *Board Exam. Midwives*, 1898-9.

1876* Pope, H. Campbell, M.D., F.R.C.S., Broomsgrove Villa, 280, Goldhawk road, Shepherd's Bush, W. *Council*, 1902-3.

1891† Pope, Henry Sharland, M.B., B.C.Cantab., Castle Bailey, Bridgwater.

1888* Popham, Robert Brooks, M.R.C.P. Edin., L.R.C.P.Lond., "Beaucroft," Queen's road, Boscombe. Hants.

1893 Powell, Herbert Edward, M.R.C.S., Manor Lodge, Upper Clapton, N.E.

1901 Powell, Llewellyn, M.B., B.C.Cantab., 37, Brunswick gardens, Campden Hill, W.

1886 Prangley, Henry John, L.R.C.P. Lond., Tudor House, 197, Anerley road, Anerley, S.E.

1880* Prickett, Marmaduke, M.A.Cantab., M.D., Physician to the Samaritan Hospital; 27, Oxford square, W. *Council*, 1892.

1895 Priestley, R. C., M.A., M.B.Cantab., 81, Linden gardens, Bayswater, W.

1898† Purslow, Charles Edwin, M.D., M.R.C.P.Lond., Honorary Obstetric Officer, Queen's Hospital, Birmingham; 192, Broad street, Birmingham.

1876*†Quirke, Joseph, M.R.C.P. Ed., The Oaklands, Hunter's road, Handsworth, Birmingham.

1878† Rawlings, John Adams, M.R.C.P.Ed., 14, Northampton place, Swansea.

1897 Rawlings, J. D., M.B.Lond., Rose Hill House, Dorking.

1870* Ray, Edward Reynolds, M.R.C.S., 15a, Upper Brook street, W. *Council*, 1902-3.

1894† Rayner, Herbert Edward, F.R.C.S., Harcourt House, Camberley, Surrey.

1899† Rayner, David Charles, F.R.C.S.Eng., 9, Lansdowne place, Victoria square, Clifton, Bristol.

Elected

1860* Rayner, John, M.D., Swaledale House, Highbury quadrant, N.

1879 Read, Thomas Laurence, M.R.C.S., 11, Petersham terrace, Queen's gate, S.W. *Council*, 1892.

1879† Reid, William Loudon, M.D., Professor of Midwifery and Diseases of Women and Children, Anderson's College; Physician to the Glasgow Maternity Hospital; 7, Royal crescent, Glasgow. *Council*, 1899-1901-2.

1893† Renshaw, Israel James Edward, F.R.C.S.Edin., Ashton Grange, Cross street, Ashton-upon-Mersey.

1875*† Rey, Eugenio, M.D., 39, Via Cavour, Turin.

1890 Reynolds, John, M.D.Brux., 11, Brixton hill, S.W.

1872*† Richardson, William L., M.D., A.M., Professor of Obstetrics in Harvard University; Physician to the Boston Lying-in Hospital; 225, Commonwealth avenue, Boston, Massachusetts, U.S.

1889† Richmond, Thomas, L.R.C.P. Ed., 22, Holyrood crescent, Glasgow.

1871* Rigden, Walter, M.D. St. And., 16, Thurloe place, S.W. *Council*, 1882-3. *Trans.* 1.

1892 Roberts, Charles Hubert, M.D.Lond., F.R.C.S.Eng., M.R.C.P., Physician to Out-patients to Queen Charlotte's Hospital; Demonstrator of Practical Midwifery and Diseases of Women, St. Bartholomew's Hospital; 21, Welbeck street, Cavendish square. *Council*, 1897-9. *Board Exam. Midwives*, 1901. *Trans.* 4.

O.F.*† Roberts, David Lloyd, M.D., F.R.C.P., F.R.S. Edin., Consulting Obstetric Physician to the Manchester Royal Infirmary; and Lecturer on Clinical Midwifery and the Diseases of Women in Owens College; 11, St. John street, Deansgate, Manchester. *Council*, 1868-70, 1880-2. *Vice-Pres.* 1871-2. *Trans.* 5.

1867* Roberts, David W., M.D., 56, Manchester street, Manchester square, W.

Elected

1890† Roberts, Hugh Jones, M.R.C.S., Gwyddfor, Penygroes, R.S.O., N. Wales.

1893 Roberts, Thomas, L.S.A., 2, Selborne gardens, York road, Ilford, Essex.

1874* Robertson, William Borwick, M.D., St. Anne's, Thurlow park road, West Dulwich, S.E.

1892 Robinson, George H. Drummond, M.D., B.S. Lond., Assistant Obstetric Physician, West London Hospital; 84, Park street, Grosvenor square, W. *Council*, 1899-1900. *Board Exam. Midwives*, 1898-1900. *Trans.* 2.

1887 Robinson, Hugh Shapter, L.R.C.P. Ed., Talfourd House, 78, Peckham road, Camberwell, S.E.

1895† Robson, Alfred William, M.D. Brux., Kempstow House, 111, Park road, Aston, Birmingham.

1890† Robson, A. W. Mayo, F.R.C.S., 7, Park square, Leeds.

1876†* Roe, John Withington, M.D., Ellesmere, Salop.

1874*† Roots, William Henry, M.R.C.S., Canbury House, Kingston-on-Thames.

1893† Rosenau, Albert, M.D., Hôtel Victoria, Kissingen, Bavaria. (*Winter*, Avenue la Costa, Monte Carlo.)

1884† Rossiter, George Frederick, M.B., Surgeon to the Weston-super-Mare Hospital; Cairo Lodge, Weston-super-Mare.

1902 Rotheroe, W. Burslem, L.R.C.S. & P. Edin., 47, Gloucester place, Portman square, W.

1884† Roughton, Walter, F.R.C.S., Cranborne House, New Barnet.

1882* Routh, Amand, M.D., B.S., F.R.C.P., Obstetric Physician and Lecturer on Midwifery at Charing Cross Hospital; 14A, Manchester square, W. *Council*, 1886-8, 1896-7. *Board Exam. Midwives*, 1893-5. *Hon. Lib.* 1898-9. *Hon. Sec.* 1900-3. *Trans.* 5.

Elected

O.F.* Routh, Charles Henry Felix, M.D., Consulting Physician to the Samaritan Free Hospital for Women and Children; 52, Montagu square, W. *Council*, 1859-61. *Vice-Pres.* 1874-6. *Trans.* 13.

1887*†Rowe, Arthur Walton, M.D. Dur., 1, Cecil street, Margate.

1886 Rushworth, Frank, M.D. Lond., 1A, Goldhurst terrace, South Hampstead, N.W.

1888† Rushworth, Norman, L.R.C.P. Lond., Beechfield, Walton-on-Thames.

1886† Rutherfoord, Henry Trotter, M.A., M.D. Cantab., Salisbury House, Taunton. *Council*, 1892-3. *Trans.* 1.

1866*†Saboia, Baron V. de, M.D., Director of the School of Medicine, Rio de Janeiro; 7, Rua dom Affonso, Petropolis, Rio Janeiro. *Trans.* 2.

1864*†Salter, John H., M.R.C.S., D'Arcy House, Tolleshunt d'Arcy, Kelvedon, Essex. *Council*, 1894-6.

1868* Sams, John Sutton, M.R.C.S., St. Peter's Lodge, Eltham road, Lee, S.E. *Council*, 1892.

1886† Sanderson, Robert, M.B. Oxon., 56, Brunswick square, Brighton.

1872 Sangster, Charles, M.R.C.S., 148, Lambeth road, S.E.

1877 Savory, Charles Tozer, M.D., 25, Grange road, Canonbury, N. *Trans.* 1.

1894† Savory, Horace, M.A., M.B., B.C.Cantab., Assistant Physician to Bedford County Hospital, 45, Harpur street, Bedford. *Trans.* 1.

1890 Schacht, Frank Frederick, B.A., M.D.Cantab., 153, Cromwell road, S.W.

1902 Scharlieb, Mary Ann Dacomb, M.D.Lond., M.S., B.S., 149, Harley street, W.

1888 Scott, Patrick Cumin, B.A., M.B. Cantab., 38, Shooter's Hill road, Blackheath, S.E.

1882 Serjeant, David Maurice, M.D., 27, Peckham road, S.E.

1875 Seton, David Elphinstone, M.D., 1, Emperor's gate, S.W. *Council*, 1884.

Elected

1896† Sharman, Mark, M.B., C.M.Glas., Rickmansworth.

1894† Sharpin, Archdale Lloyd, L.R.C.P. Lond., 23, Kimbolton road, Bedford.

1887 Shaw, John, M.D. Lond., Obstetric Physician to the North-West London Hospital; 32, New Cavendish street, Cavendish square, W. *Trans.* 3.

1891 Shaw-Mackenzie, John Alexander, M.D. Lond., 31, Grosvenor street, W.

1900† Shepherd, Thomas William, L.R.C.S.Edin., Castle Hill House, Launceston.

1900 Sherren, James, L.R.C.P.Lond., F.R.C.S.Eng., London Hospital, E.

1902 Sikes, Alfred Walter, M.D., B.Sc.Lond., 40, Argyll road, Campden hill, W.

1902 Simson, Henry J. F., M.B., F.R.C.S.Ed., 3, Charles street, Berkeley square, W.

1888† Sinclair, William Japp, M.D. Aber., Honorary Physician to the Southern Hospital for Women and Children and Maternity Hospital, Manchester; and Professor of Obstetrics and Gynæcology, Owens College, Manchester; 250, Oxford road, Manchester. *Council*, 1899-1902. *Vice-Pres.*, 1903. *Trans.* 1.

1881† Sloan, Archibald, M.B., 21, Elmbank street, Glasgow.

1876† Sloan, Samuel, M.D., C.M., 5, Somerset place, Sauchiehall street west, Glasgow.

1890† Sloman, Frederick, M.R.C.S., 18, Montpellier road, Brighton.

1861 Slyman, William Daniel, M.R.C.S., 26, Caversham road, Kentish Town, N.W. *Council*, 1881.

1901 Smith, Guy Bellingham, M.B., B.S.Lond., F.R.C.S., 24, St. Thomas's street, S.E.

1867* Smith, Heywood, M.D., 25, Welbeck street, Cavendish square, W. *Council*, 1872-5. *Board Exam. Midwives*, 1874-6. *Trans.* 6.

1875 Smith, Richard Thomas, M.D., Physician to the Hospital for Women, Soho square; 117, Haverstock hill, N.W.

1886† Smith, Samuel Parsons, L.K.Q.C.P.I., Park Hyrst, Addiscombe road, Croydon.

Elected

1899*†Smyly, William Josiah, M.D., F.R.C.P.I., 58, Merrion square, Dublin.

1899† Smithson, Oliver, L.R.C.P., Moor street, Luton, Beds.

1895 Soden, Wilfred Newell, M.B.Lond., 186, Amhurst road, Hackney, N.E.

1868* Spaull, Barnard E., M.R.C.S., L.R.C.P., 1, Stanwick road, West Kensington, W.

1888* Spencer, Herbert R., M.D., B.S.Lond., F.R.C.P., Professor of Midwifery in University College, London, and Obstetric Physician to University College Hospital; 104, Harley street, W. *Council*, 1890-92. *Board Exam. Midwives*, 1896-7. *Hon. Sec.* 1898-1901. *Vice-Pres.*, 1902-3. *Trans.* 8.

1876† Spencer, Lionel Dixon, M.D., Brigade-Surgeon, I.M.S., Bengal Establishment [care of Messrs. Grindlay and Co., 55, Parliament street, S.W.].

1882 Spooner, Frederick Henry, M.D., Maitland Lodge, Maitland place, Clapton, N.E.

1876† Spurgin, Herbert Branwhite, M.R.C.S., 82, Abington street, Northampton.

1897 Stabb, Arthur Francis, M.B., B.C. Cantab., Assistant Obstetric Physician to St. George's Hospital, and Lecturer in Midwifery in the University of Cambridge; 109, Harley street, W. *Council*, 1899-1901.

1894 Stevens, Thomas George, M.D., B.S. Lond., 8, St. Thomas's street, S.E. *Council*, 1902-3. *Trans.* 2.

1884† Stevenson, Edmond Sinclair, F.R.C.S. Ed., Strathallan House, Rondebosch, Cape of Good Hope. *Trans.* 2.

1877† Stephenson, William, M.D., Professor of Midwifery, University of Aberdeen; 3, Rubislaw terrace, Aberdeen. *Council*, 1881-3. *Vice-Pres.*, 1887-9. *Trans.* 2.

1875*†Stewart, William, F.R.C.P. Ed., 26, Lethbridge road, Southport.

1884† Stiven, Edward W. F., M.D., The Manor Lodge, Harrow-on-the-Hill.

Elected

1883 Stocks, Frederick, M.R.C.S., 421, Wandsworth road, S.W.

1894† Stott, William Atkinson, M.R.C.S., L.R.C.P. Lond., 1, Grove terrace, Leeds.

1866* Strange, William Heath, M.D., 2, Belsize avenue, Belsize park, N.W. *Council*, 1882-4.

1895 Stuck, Sidney Joseph, M.D., Kent House, 6, Bow road, E.

1898† Sturmer, Arthur James, M.R.C.S., L.R.C.P., Lieut.-Col., Indian Medical Service, Madras.

1884 Sunderland, Septimus, M.D., M.R.C.P., Physician to the Royal Hospital for Children and Women; 11, Cavendish place, Cavendish square, W.

1894 Swallow, Allan James, M.B., B.S. Durh., Taunton House, 404, Clapham road, S.W.

1896 Swan, Charles Atkin, M.B., B.Ch.Oxon., 4, Devonport street, Hyde Park, W.

1901 Swanton, James Hutchinson, M.D., M.Ch., 40, Harley street, W.

1893 Swayne, Francis Griffiths, M.A., M.B., B.C.Cantab., 140, Church road, Norwood, S.E.

1859*†Swayne, Joseph Griffiths, M.D., Consulting Physician-Accoucheur to the Bristol General Hospital; Emeritus Professor of Midwifery in University College, Bristol; Harewood House, 74, Pembroke road, Clifton, Bristol. *Council*, 1860-1. *Vice-Pres.* 1862-4. *Trans.* 9.

1892† Swayne, Walter Carless, M.D.Lond., Obstetric Physician, Bristol Royal Infirmary; Lecturer on Practical Midwifery in University College, Bristol; 8, Leicester place, St. Paul's road, Clifton. *Council*, 1903.

1888* Sworn, Henry George, L.K.Q.C.P. & L.M., 5, Highbury crescent, N.

1883 Tait, Edward Sabine, M.D., 48, Highbury park, N. *Council*, 1892-4. *Trans.* 1.

1879 Tait, Edward W., M.R.C.S., 10, Ellerdale road, Hampstead, N.W. *Council*, 1886-7.

1880*†Takaki, Kanaheiro, F.R.C.S., 10, Nishi-Konyachō, Kiōbashika, Tokio, Japan. *Hon. Loc. Sec.*

Elected

1891 Targett, James Henry, M.B., M.S. Lond., F.R.C.S., Assistant Obstetric Surgeon to Guy's Hospital, 6, St. Thomas's street, S.E. *Council*, 1895. *Board Exam. Midwives*, 1900-1.

1892 Tate, Walter William Hunt, M.D.Lond., Obstetric Physician to, and Lecturer on Midwifery and the Diseases of Women at, St. Thomas's Hospital; 32, Queen Anne street, Cavendish square, W. *Council*, 1895-7. *Board Exam. Midwives*, 1898-9. *Trans.* 1.

1871 Tayler, Francis T., B.A. Lond., M.B., Claremont villa, 224, Lewisham High road, S.E. *Council*, 1902-3.

1900 Taylor, Frank Edward, M.A., M.B., Chelsea Hospital for Women, Fulham road, S.W.

1890*†Taylor, John William, F.R.C.S., Surgeon to the Birmingham and Midland Hospital for Women; Professor of Gynæcology, Birmingham University; 22, Newhall street, Birmingham. *Council*, 1900-2. *Trans.* 4.

1892 Taylor, William Bramley, M.R.C.S., 145, Denmark hill, S.E.

1894† Tench, Montague, M.D. Brux., L.R.C.P. Lond., Great Dunmow, Essex.

1902† Tennant, John, M.A., M.B., C.M.Edin., 39, University road, Belfast.

1890† Thomas, Benjamin Wilfred, L.R.C.P. Lond., Welwyn.

1899† Thomas, J. Raglan, M.D., 13, West Southernhay, Exeter.

1887† Thomas, William Edmund, L.R.C.P.Ed., Ashfield, Bridgend, Glamorganshire.

1901 Thompson, Charles Herbert, M.D.Dubl., 133, Harley street, W.

1867*†Thompson, Joseph, L.R.C.P.Lond., Surgeon to the General Hospital and Hospital for Women, Nottingham; 1, Oxford street, Nottingham. *Hon. Loc. Sec. Council*, 1896-8. *Trans.* 1.

Elected

1902 THORNE, MARY, M.D., 10, Nottingham place, W.

1873* TICEHURST, CHARLES SAGE, M.R.C.P.Edin., Petersfield, Hants.

1895† TINLEY, WILLIAM EDWIN FALKINGRIDGE, M.B., B.S.Durh., Hildegard House, Whitby.

1879† TIVY, WILLIAM JAMES, F.R.C.S. Ed., 8, Lansdown place, Clifton, Bristol.

1884 TRAVERS, WILLIAM, M.D., 2, Phillimore gardens, W.

1893† TRETHOWAN, WILLIAM, M.B., C.M. Aber., care of Dr. Mac-Williams, Perth, Western Australia.

1886† TUCKETT, WALTER REGINALD, M.R.C.S., Woodhouse Eaves, near Loughborough.

1898 TURNER, ARTHUR SCOTT, L.R.C.P.Lond., 39, Anerley road, Upper Norwood, S.E.

1865* TURNER, JOHN SIDNEY, M.R.C.S., Stanton House, 81, Anerley road, Upper Norwood, S.E. *Council*, 1893-4.

1891 TURNER, PHILIP DYMOCK, M.D.Lond., Sudbury villa, Ryde, Isle of Wight. *Trans.* 1.

1897 TWYNAM, GEORGE EDWARD, L.R.C.P.Lond., 31, Gledhow gardens, S.W.

1890 TYRRELL, WALTER, L.R.C.P.Lond., 104, Cromwell road, S.W.

1893 UMNEY, WILLIAM FRANCIS, M.D.Lond., Heatherbell, 15, Crystal Palace park road, Sydenham, S.E.

1874* VENN, ALBERT JOHN, M.D., 63, Grosvenor street, W.

1873* VERLEY, REGINALD LOUIS, F.R.C.P. Ed., Constitutional Club, W.C.

1892† VERRALL, THOMAS JENNER, L.R.C.P.Lond., 97, Montpellier road, Brighton.

1900* VINCENT, RALPH HENRY, M.D., B.S.Durh., 1, Harley street, W.

1879† WADE, GEORGE HERBERT, M.R.C.S., Ivy Lodge, Chislehurst, Kent. *Council*, 1892-3.

Elected

1894† Wagstaff, Frank Alex., L.R.C.P. Lond., Saffron Walden, Essex.

1898† Walker, Alfred, M.D., B.C., M.A.Cantab., 12, Lingfield road, Wimbledon.

1866*†Walker, Thomas James, M.D., Surgeon to the General Infirmary, Peterborough; 33, Westgate, Peterborough. *Council*, 1878-80. *Hon. Loc. Sec.*

1889 Wallace, Abraham, M.D. Edin., 39, Harley street, W.

1901† Wallace, Arthur John, M.D.Edin., 1, Gambier terrace, Liverpool.

1870 Wallace, Frederick, M.R.C.S., L.R.C.P., Foulden Lodge, Upper Clapton, N.E. *Council*, 1880-2.

1897† Wallace, James Robert, M.D.Brux., F.R.C.S.I., 50, Park street, Calcutta.

1883 Wallace, Richard Unthank, M.B., Cravenhurst, Craven park, Stamford hill, N.

1893† Walls, Willlam Kay, M.B. Lond., 14, St. John street, Manchester.

1879*†Walter, William, M.A., M.D., Surgeon to St. Mary's Hospital, Manchester; 20, St. John street, Manchester.

1867*†Walters, James Hopkins, M.R.C.S., Surgeon to the Royal Berkshire Hospital; 15, Friar street, Reading, Berks. *Council*, 1884-6. *Hon. Loc. Sec. Trans.* 1.

1873† Walters, John, M.B., Church street, Reigate, Surrey. *Council*, 1896-8. *Trans.* 1.

1898*†Ward, Charles, F.R.C.S.I., M.R.C.S.Eng., Pietermaritzburg, Natal, S. Africa.

1895 Warner, Frederick Ashton, L.R.C.P., 10, Brechin place, South Kensington, S.W.

1898† Watson, C. R., M.D.Brux., 3, Mount Ephraim road, Tunbridge Wells.

1899† Watson, Harry Jackson, M.D., C.M. Toronto, Ottumwa, Iowa, U.S.A.

1884† Waugh, Alexander, L.R.C.P. Lond., Midsomer-Norton, Bath.

Elected

1894† Webb, John Curtis, M.A., M.B., B.C.Cantab., 6, Bina, Gardens, S.W.

1893† Webster, Thomas James, M.R.C.S., Brynglâs, Merthyr Tydvil.

1901† Weekes, Henry Holman, M.D.Brux., L.R.C.P.Lond., 21, Kidbrook park road, Blackheath, S.E.

1897† Weeks, Courtenay Charles, L.R.C.P.Lond., 9, Lewisham park, Lewisham, S.E.

1886† West, Charles J., L.R.C.P. Lond., The Grove, Fulbeck, Grantham.

1888* Weston, Joseph Theophilus, M.D.Brux., Civil Surgeon, Hissar, Punjab (care of Messrs. Thacker, Spink, and Co., booksellers and publishers, Government place, Calcutta).

1890* Wheaton, Samuel W., M.D.Lond., Physician to the Royal Hospital for Children and Women; 10, Rastell avenue, Streatham hill, S.W.

1890 White, Charles Percival, M.A., M.B., B.C.Cantab. 22, Cadogan gardens, S.W. *Council*, 1901.

1902† White, Clement, M.B., B.C.Cantab., Star hill, Rochester.

1902† Whitelocke, Richard Henry A., M.B., C.M.Edin., 6, Banbury road, Oxford.

1882 Wholey, Thomas, M.B. Durh., Room 79, Electra House, Moorgate street, E.C.

1901† Wigg, Henry Higham, M.D.Brux., L.R.C.P.Adelaide.

1902 Willett, John Abernethy, M.B.Oxon., 36, Wimpole street, W.

1901 Willey, F. J. I., M.B., B.S., The Wych, Avenue road, Highgate.

1872 Williams, Sir John, Bart., M.D., F.R.C.P., Physician-Accoucheur to H.R.H. Princess Beatrice, Princess Henry of Battenberg; Consulting Obstetric Physician to University College Hospital; 63, Brook street, Grosvenor square, W. *Council*, 1875-6, 1892, 1894. *Hon. Sec.* 1877-9. *Vice-Pres.* 1880-2. *Board Exam. Midwives*, 1881-2; *Chairman*, 1884-6. *Pres.* 1887-8. *Trans.* 12. *Trustee.*

Elected

1897 Williams, Joseph William, L.R.C.P., 128, Mansfield road, Gospel Oak, N.W.

1890 Williams, Reginald Muzio, M.D.Lond., 35, Kensington park gardens, W.

1899 Williamson, Herbert, M.A., M.B., B.C.Cantab., 10, Bentinck street, Manchester square, W. *Trans.* 1.

1898† Wilson, Claude, M.D.Edin., Belmont, Church road, Tunbridge Wells.

1892† Wilson, Thomas, M.D., B.S.Lond., F.R.C.S., Assistant Obstetric Physician at the General Hospital, Birmingham; 87, Cornwall street, Newhall street, Birmingham. *Trans.* 3.

1901† Wilson, Thomas George, M.B., Ch.M.Sydney, F.R.C.S. Edin.; 296, Ward street, North Adelaide, South Australia.

1900† Wingate, William Warburton, M.B., B.C.Cantab., 60, St. Andrew's street, Cambridge.

1886† Winterbottom, Arthur Thomas, L.R.C.P.Ed., Lark hill, Swinton, Manchester.

1877* Wintle, Henry, M.B., 33, Strawberry High road, Twickenham.

1893 Wise, Robert, M.D.Edin., 5, Weston park, Crouch End, N.

1887† Withers, Robert, M.R.C.S., Stenteford Lodge, Spencer terrace, Lipson road, Plymouth.

1890 Wornum, George Porter, M.R.C.S., 58, Belsize park, Hampstead, N.W.

1876† Worts, Edwin, M.R.C.S., L.R.C.P., 6, Trinity street, Colchester.

1887† Wright, Charles James, M.R.C.S., Senior Surgeon to the Hospital for Women and Children, Leeds; Professor of Midwifery to the Yorkshire College; Lynton Villa, Virginia road, Leeds. *Council*, 1903.

Elected

1888*†Wyatt-Smith, Frank, M.B., B.C.Cantab., British Hospital, Buenos Ayres.

1871 Yarrow, George Eugene, M.D., 26, Duncan terrace, Islington, N. *Council*, 1881-3.

1882*†Young, Charles Grove, M.D., Berbice, Sea road, Bexhill-on-Sea.

Number of Fellows 618

CONTENTS.

	PAGE
List of Officers for 1903	v
Standing Committees	vii, viii
List of Honorary Local Secretaries	viii
List of Past Presidents	ix
List of Referees of Papers for 1903	x
Trustees of the Society's Property	xi
List of Honorary Fellows	xi, xii
List of Ordinary Fellows	xiii
Contents	lv
List of Plates	lxi
List of Illustrations	lxii
Advertisement	lxiii
Hours of Attendance at Library	lxiii

January 1st, 1902—

A Case of (?) Parasitic Cyst of the Vulva, shown by Lieut.-Col. A. J. STURMER	2
Report on Lieut.-Col. A. J. Sturmer's Specimen of Parasitic Cyst of the Vulva	4
A Case of Primary Pneumococcus Meningitis simulating Puerperal Eclampsia, by Dr. THOMAS WILSON	5
Two Uteri removed by Abdominal Pan-hysterectomy for Cancer of the Body, by Dr. LEWERS	10
I. A Case of Chorio-Epithelioma with Pulmonary Metastases, by Dr. CUTHBERT LOCKYER	24

February 5th, 1902—

Annual Meeting	38
Dermoid Cyst of Ovary removed by Posterior Colpotomy, by Dr. AMAND ROUTH	38

PAGE

Uterus removed at eight and a half months of Gestation by Abdominal Hysterectomy for Fibroid obstructing Labour, by Dr. AMAND ROUTH . 41

On a Case of Tubal Pregnancy diagnosed before Rupture, and a Case of Tubal Abortion, by Mr. BLAND-SUTTON 44

Annual Meeting—the Audited Report of the Treasurer (Dr. CHAMPNEYS) . . 47, 48

—— Report of the Honorary Librarian (Dr. M. HANDFIELD-JONES) 47

—— Report of the Chairman of the Board for the Examination of Midwives (Dr. DAKIN) . . 49

Alterations in the Laws 51

Election of Officers and Council for the year 1902 . 51

Annual Address of the President . . . 53

March 5th, 1902—

Case of Rupture of an Ovarian Abscess twelve hours after Labour, by Dr. COMYNS BERKELEY . 73

Report of the Pathological Committee on Dr. Comyns Berkeley's specimen of Ovarian Abscess ruptured during Labour 77

A Case of Teratoma of the Fœtal Head, by Mr. H. S. STANNUS 78

Report of Teratological Committee upon Mr. Stannus's specimen of Orbital Tumour in a Fœtus . . 91

Solid Tumour of the Left Ovary with an attached Cyst communicating with the Left Fallopian Tube, by Dr. VICTOR BONNEY . . . 92

Report of the Pathological Committee on Dr. Bonney's specimen of Solid Ovarian Tumour with a Cyst attached, with the Tube open . . . 93

Sarcoma of Ovary, by the President (Dr. PETER HORROCKS) 94

Lithopædion retained in Patient for sixteen years, by Dr. WALTER TATE 95

II. Suppression of Urine after Labour, by Dr. R. G. MCKERRON 97

April 2nd, 1902—

Unilocular Ovarian Cyst containing Solid Masses undergoing Necrotic Change, by Dr. F. S. FAIRBAIRN 126

PAGE

Small Fibroma Uteri showing Sarcomatous Changes, by Dr. MUNRO KERR 129
Fibro-myoma of the Vagina, by Dr. MUNRO KERR . 130
Report of the Pathological Committee on Dr. Munro Kerr's specimen of Tumour of the Uterus . 130
Fallopian Tube ruptured towards its Fimbriated End in two places, by Dr. AMAND ROUTH . . 131
Tubal Mole removed by Colpotomy, by Dr. F. J. McCANN 133
Squamous Carcinoma of the Cervix Uteri, by Dr. F. J. McCANN 136
A Case of Congenital Prolapse of the Uterus associated with Spina Bifida, by Dr. H. RUSSELL ANDREWS 137
Tubercle of the Uterus, by Dr. PETER HORROCKS . 141
Abnormal Umbilical Cord; Tubercle of Uterus, by Dr. HERBERT WILLIAMSON . . . 141
Tuberculosis of Cervix, by Dr. E. O. CROFT . 142
III. A Case of Primary Tuberculosis of the Cervix simulating Cancer, and treated by Vaginal Hysterectomy, by Dr. ARTHUR H. N. LEWERS . . 144

May 7th, 1902—

Lymphangitis Mammæ: an Affection of the Breast arising about the tenth day of the Puerperium with well-marked clinical features (illustrated by six cases), by Dr. RALPH VINCENT . . . 158
A probable Case of Superfœtation, by Dr. W. F. VICTOR BONNEY 163
Gangrenous Sarcoma of Uterus removed by Abdominal Hysterectomy from a Patient suffering from Glycosuria, by Dr. WALTER TATE . . 165
A Pure Myoma of the Ovary, with a microscopic section, by Mr. ALBAN DORAN . . . 168
A Pure Fibroma of the Ovary, by Mr. ALBAN DORAN 172
Fibroma of Ovary one third of an inch in diameter, by Mr. ALBAN DORAN . . . 173
Fibroma of Ovary, by Dr. FLORENCE NIGHTINGALE BOYD 176
IV. Five Specimens of Fibroid Tumour of the Ovary, with Observations on their Pathological Anatomy, by Dr. JOHN S. FAIRBAIRN 177

PAGE

June 4th, 1902—

Primary Ovarian Gestation, by Mr. A. W. Mayo Robson 215

Specimens of Cancer of the Cervix from eight cases treated by the Supra-vaginal Amputation, in which from four to fifteen years had elapsed without recurrence, by Dr. Lewers . . . 221

Adeno-carcinoma of both Ovaries, by Dr. Arnold W. W. Lea 225

Unusual Case of Ectopic Gestation, by Dr. Herbert Williamson 225

Case of Extra-uterine Fœtation, by Dr. Horrocks . 228

V. Pregnancy after Removal of both Ovaries for Cystic Tumour, by Mr. Alban Doran . . 231

July 2nd, 1902—

Report of the Pathological Committee on Dr. Fothergill's specimen of Decidual Uterine Cast of seven weeks' growth, together with an Ovum of about five days' growth (shown June 5th, 1901) . . 251

Report of the Pathological Committee on Dr. Tate's specimen of Sarcoma of the Uterus (shown May 7th, 1902) 252

A Case of Puerperal Eclampsia, with Autopsy and Remarks, by Dr. R. H. Bell . . . 253

Retro-peritoneal Lipoma weighing thirteen pounds twelve ounces, by Mr. Alban Doran . . 265

VI. Ovarian Tumour obstructing Delivery; Posterior Vaginal Section and Ovariotomy during Labour; Operation and Delivery at one Sitting; Recovery, by Mr. J. W. Taylor . . . 275

October 8th, 1902—

Uterus showing rapidly growing Epithelioma of the Cervix; Death from Recurrence five months after removal, by Dr. Cuthbert Lockyer . . 284

Uterus removed by Abdominal Pan-hysterectomy for Primary Carcinoma of the Body, by Dr. Lewers . 290

Uterus and Vagina with the child *in situ* in the second stage of Labour, by Dr. W. F. Victor Bonney . 292

A Case of "Deciduoma malignum" after the Menopause, by Dr. F. J. McCann . . . 294

PAGE

Three months Gravid Uterus removed by Vaginal Hysterectomy for Squamous Epithelioma of Cervix, by Dr. WILLIAM DUNCAN . . . 297

A Small Ovarian Tumour removed by Posterior Vaginal Section from a Patient who was about two months pregnant, by Prof. J. W. TAYLOR . 297

The Porro Medal, and Report on Porro-Cæsarean Section, by Dr. HERBERT R. SPENCER . . 298

VII. Complete Inversion of Uterus of Seven Months' duration; failure of Elastic Pressure with Repositors; Operation of Anterior Vaginal Cœliotomy, Anterior Hysterotomy, and Replacement; Recovery, by Prof. J. W. TAYLOR 299

November 5th, 1902—

Report of the Pathological Committee on Mr. Alban Doran's Specimen of Retro-peritoneal Lipoma (p. 265) 310

——— of the Pathological Committee on Sections from the Liver in Dr. Hamilton Bell's Case of Puerperal Eclampsia (p. 253) . . . 310

On a Case of Primary Cancer of the Fallopian Tube, by Mr. J. BLAND-SUTTON . . . 311

Report on ditto 313

On Two Cases of Extra-uterine Gestation which went to Term, by Mr. J. BLAND-SUTTON . . 316

A Case of Spontaneous Expulsion, by Dr. COMYNS BERKELEY 320

Case of Ruptured Tubal Gestation, by Mr. J. H. DAUBER 321

Report on ditto 322

"Paratubal" Hæmatocele, by Dr. R. H. BELL . 322

VIII. On Paratubal Hæmatocele, by Mr. W. SAMPSON HANDLEY 325

December 3rd, 1902—

A Dermoid Cyst containing a large number of Epithelial Balls, by Dr. W. F. VICTOR BONNEY . 354

A Specimen of Fibroma of the Ovary, by Dr. A. E. GILES 360

Report on ditto 361

PAGE

Pyosalpinx with Twisted Pedicle, by Dr. A. H. N. Lewers 362

Fibroid of the Broad Ligament, weighing four and a half pounds, with Twisted Pedicle, by Dr. A. H. N. Lewers 364

Sarcoma of the Body of the Uterus with Complete Inversion, by Dr. W. C. Swayne . . 366

Report on ditto 367

Cystic Fibroid of Uterus, by Dr. W. C. Swayne . 369

Icterus Neonatorum, by Dr. A. W. Sikes . . 369

IX. A Contribution to the Natural History of Dysmenorrhœa, by Dr. G. Ernest Herman and Dr. H. Russell Andrews 371

Index 397

Additions to the Library 421

PLATES.

PLATE — PAGE

I.—Chorio-epithelioma with Pulmonary Metastases (Dr. Cuthbert Lockyer) . . . 26

II.—Ditto ditto:

Fig. 1.—Surface of lung, showing the secondary growths in their natural colour and size.

Fig. 2.—Transverse section of lung, showing invasion by two secondary nodules . . 28

III.—Teratoma of the Fœtal Head. Sketch of the whole fœtus, showing two of the tumours and the hydrocephalus (Mr. H. S. Stannus) . . 78

IV.—Ditto ditto:

Sketch to show the relations of the bones and pericranium on the posterior surface of the specimen to the tumours . . . 80

IVa.—Gangrenous Sarcoma of Uterus removed by Abdominal Hysterectomy from a Patient suffering from Glycosuria (Dr. Walter Tate) . . 166

V.—Five specimens of Fibroid Tumour of the Ovary, with observations on their pathological anatomy (Dr. J. S. Fairbairn):

Specimen No. 2, showing the relation of the fibroma to the ovary . . . 184

VI.—Ditto ditto:

Specimen No. 3, showing a fibroma arising in the ovary and contained within a capsule formed of the expanded ovary and its tunica albuginea 185

VII.—Uterus removed by Abdominal Pan-hysterectomy for Primary Carcinoma of the Body (Dr. A. H. N. Lewers) 290

VIII.—A case of "Deciduoma malignum" after the Menopause (Dr. F. J. McCann) . . . 295

IX.—Ditto ditto:

Fig. 1 shows a multinucleated cell-mass in the centre of the field, together with cells possessing large nuclei.

Fig. 2 shows elongated multinucleated cell-masses exhibiting many vacuoles, so as to give a retiform appearance . . . 296

ILLUSTRATIONS.

PAGE

Primary Tuberculosis of the Cervix simulating Cancer, and treated by Vaginal Hysterectomy (Dr. Lewers):

Figs. 1, 2 148

Fig. 3 149

Primary Ovarian Gestation (Mr. A. N. Mayo Robson):

Fig. 1.—Ovary with ovum and clot, as discovered at time of operation.

Fig. 2.—Clot containing ovum removed from the top of the ovary.

Fig. 3.—Fallopian tube with small cysts attached.

Fig. 4.—Ovary with cavity that lodged the ovum . 218

Pregnancy after Removal of both Ovaries for Cystic Tumour (Mr. Alban Doran):

The rounded stump of a Fallopian tube two years after oöphorectomy 245

On Paratubal Hæmatocele (Mr. W. Sampson Handley):

Fig. 1A.—Paratubal hæmatocele, specimen 2840, St. Thomas's Museum 330

Fig. 1.—Diagram of a typical peritubal hæmatocele . 338

Fig. 2.—An unusual form of peritubal hæmatocele . 339

Fig. 3.—Hæmatocele which may be classed either as peri- or paratubal 340

Fig. 4.—Paratubal hæmatocele . . . 341

Fig. 5.—Typical paratubal hæmatocele . . 342

ADVERTISEMENT.

The Society is not as a body responsible for the facts and opinions which are advanced in the following papers and communications read, nor for those contained in the abstracts of the discussions which have occurred at the meetings during the Session.

20, Hanover Square, W.

LIBRARY AND MUSEUM,

20, Hanover Square, W.

Hours of Attendance: Monday to Friday, 1.30 p.m. to 6 p.m.; Saturday, 9.30 a.m. to 2 p.m.; and in the evenings on which the Society meets, from 7.15 p.m. to 7.45 p.m.

AGNES HANNAM, F.R.S.L.,
Secretary and Librarian.

OBSTETRICAL SOCIETY

OF

LONDON.

SESSION 1902.

JANUARY 1ST, 1902.

ERRATA.

P. 179, line 9 from the bottom, *for* "dermoid" *read* "desmoid."

P. 183, line 10 from the top, *for* "being fairly" *read* "was fairly."

P. 199, line 2 from the bottom, *for* "any series" *read* "my series."

P. 201, line 3 from the top, and footnote, *for* "Dartiques" *read* "Dartigues."

OBSTETRICAL SOCIETY

OF

LONDON.

SESSION 1902.

JANUARY 1st, 1902.

Peter Horrocks, M.D., President, in the Chair.

Present—20 Fellows and 1 visitor.

A book was presented by Dr. Frommel.

G. MacLellan Blair, M.B., B.S. (Ratho Station, N.B.), was declared admitted.

Wyndham Anstruther Milligan, M.B., C.M.Aberd., was elected a Fellow of the Society.

A CASE OF (?) PARASITIC CYST OF THE VULVA.*

By Lieut.-Col. A. J. Sturmer, M.R.C.S., L.R.C.P.

The patient from whom the specimen was removed was a native Christian, aged 30, who had been married sixteen years, and had had three children, the last six years ago.

First confinement was easy, second was difficult, and the third was instrumental, and the patient had to keep in bed for thirteen days.

Abortions.—One, 2½ months, in July, 1899.

Complaint.—Pain in the vagina, dyspareunia, red discharge since March, 1900, and fæcal matter passing *per vaginam.*

Duration.—Pain and discharge (red) since March; fæcal fistula since the birth of the second child, twelve years ago.

Periods regular until last March, no pain, lasting five days, no clots and no shreds. Since March a more or less continuous flow. She was sent to the Government Maternity Hospital, Madras, because of this continuous discharge. There was great pain on intercourse and on attempts made to examine her, and she was not thoroughly examined.

May 7th.—She was seen by me on this day. A great tear was found in the recto-vaginal septum, extending high up. The examination was said to be most painful, but no sign of any red discharge could be made out. The tear involved the sphincter ani. She was in most wretched health, and much wasted.

May 18th.—Under chloroform the posterior vaginal wall was dissected up, the rectal walls were brought

* Read May 1st, 1901. See 'Trans. Obstet. Soc.,' vol. xliii, p. 148.

into apposition—after incision had been made at the side,—and the raw surfaces grafted after Thiersch's method.

May 22nd.—She was seen again on the table this day. In the meantime a dose of oil had been given, the bowels had acted naturally, and flatus had been passed. The grafts looked healthy, and I was congratulating myself on a very successful operation. I noticed a small dark blue spot on the right of the vestibule, and attributed this to the pressure of the speculum at the time of the operation. The iodoform gauze with which the vagina had been packed was removed, and sterilised water was injected over the grafts. She was lifted into the sitting posture in order to get rid of the surplus water, when I suddenly noticed a discharge of very bright blood. She was at once laid flat on the table, and then I saw that the dark blue spot had disappeared, and blood—as from an artery, but not in jerks—was issuing from this spot, which was the size of a pea. A finger was introduced into the hole and a cyst came away, followed by two more; they were attached to each other, as in a hydatidiform mole. Hot water, 115° F., was injected into the hole with no effect. The abdomen was next opened, one finger being kept in the hole which was the outlet of a cavity. The cavity appeared to have no communication with the interior of the abdomen; no large or small vessels could be seen supplying the cavity with blood, and the cavity did not communicate with the uterus or vagina or bladder. The cavity was then stuffed very firmly with iodoform gauze, and the abdominal wound closed. Liquor Strychniæ ℥v was injected, and a few ounces of saline solution under the breast; but the pulse, which had become weak at the onset of bleeding, gradually grew fainter, and she died whilst the saline was being injected. I send the specimen for favour of report. There is a large, ragged cavity, from which five cysts (? hydatids) have been removed; one cyst is still adherent, although it is ruptured. Whether it is an

angeioma or a wrongly placed hydatidiform mole I am unable to say, and I should be much obliged if the Society will help me to an elucidation. Of course, the woman was in a very bad condition at the time of the operation, but such bleeding I have seldom seen; it was like that of a dammed-up stream breaking through the dam. The recto-vaginal fistula extended nearly up to the fundus vaginæ, and how intercourse could have taken place and she could have become pregnant seems very remarkable.

Report on Lieut.-Col. A. J. Sturmer's Specimen of Parasitic Cyst of the Vulva.

We, the undersigned, have met this day, and after examining the specimen named above, have drawn up and signed the following report:

The specimen consists of the uterus and its appendages with the bladder and urethra. There is a ragged cavity in front of the vagina and on the right of the urethra, extending backwards along the base of the bladder. This cavity is almost spherical and about two inches in diameter. Its outer surface is blended with the surrounding tissues, but its inner surface is covered with fragments of clot, and is marked by trabeculæ of fibrous tissue. There are also a few pedunculated cyst-like bodies attached to the wall. On dissecting the tissues behind the bladder towards the base of the right broad ligament many tortuous channels are found, resembling venous sinuses, and these can be traced into the above-mentioned cavity. One or two of these sinuses were found to contain cyst-like bodies similar to those in the main cavity.

These cysts, as well as the smaller cyst-like bodies found in the venous sinuses, are probably parasitic in nature, but have not the characters of hydatids, and the degeneration

of the tissues prevents their exact identity from being established.

The fact that the large venous sinuses communicated with the tumour will explain the fatal hæmorrhage which occurred when it ruptured.

AMAND ROUTH.
C. HUBERT ROBERTS.
T. W. EDEN.
J. H. TARGETT, *Convener.*

November 14th, 1901.

A CASE OF PRIMARY PNEUMOCOCCUS MENINGITIS SIMULATING PUERPERAL ECLAMPSIA.

Shown by THOMAS WILSON, M.D., F.R.C.S.

PNEUMOCOCCUS meningitis, in the absence of inflammation of the lungs, is not a common affection, and its occurrence in the later months of pregnancy is, it may be presumed, of extreme rarity. Eclampsia, on the other hand, is relatively common, occurring, according to different statistics, with a frequency varying from 2 in 1000 to 6 in 1000 cases of pregnancy. As a general rule eclampsia presents a collection of phenomena that makes it tolerably easy to recognise. The sudden onset of epileptiform convulsions, with or without clear prodromal symptoms, in a pregnant, parturient, or puerperal woman immediately gives rise to suspicion; the repetition of convulsions associated with coma more or less marked and persistent, and the observation that the urine is diminished in quantity and contains a notable amount of albumen, converts the suspicion almost into certainty. The diagnosis from hysterical convulsions is, as a rule, readily made by observing the character of the convulsions and of the attendant symptoms. From ordinary epilepsy the distinction is made by a reference to the patient's history

and to the condition of the urine. Convulsions due to meningitis may be differentiated from eclampsia by the history of the affection, the presence of hemiplegia or other paralyses, and by the fact that the urine is not diminished in quantity and does not contain albumen. The following case shows the insuperable difficulties that may sometimes be met with in the present state of our knowledge in making a correct diagnosis during life between eclampsia and meningitis. In a woman in the seventh month of pregnancy the onset of severe and continuous headache, the occurrence of coma and epileptiform convulsions five days later, the co-existence of albuminuria, and the rapid termination in death—all these, taken together, appeared to make the diagnosis of eclampsia certain. For the notes of the case and of the autopsy I have to express my indebtedness to Mr. F. V. Milward, F.R.C.S.Eng., formerly Resident Surgical Officer; and to Mr. J. G. Emanuel, M.B., B.S.Lond., Pathologist to the Birmingham General Hospital.

The patient, R. S—, a married woman aged 35, was admitted to the General Hospital, Birmingham, under the care of Dr. Thomas Wilson, at 4.25 p.m. on April 5th, 1901, with the diagnosis of eclampsia of pregnancy.

On admission the patient was comatose and cold, the pulse 140 to the minute and very small, respirations 38, and temperature 100·8° F. After being put to bed the extremities gradually became warm, but pallor turned to cyanosis, the respirations became slower and slower, and one and a half hours after admission the woman died, never having recovered consciousness. Rapid examination showed that the patient was a multipara between six and seven months pregnant. The heart and lungs showed no abnormal physical signs, and there was no œdema. Urine drawn off by the catheter was of acid reaction, and specific gravity 1032; it contained a cloud of albumen and 1·5 per cent. of sugar. Microscopic examination failed to reveal casts or blood-corpuscles.

The following history was obtained from the patient's aunt:

The woman had had seven children, all born by natural labours, all healthy except the second, who was an idiot; she was not known to have suffered from any previous kidney trouble. At the time of admission she was supposed to have been about six months pregnant, and she had been quite well until March 31st, five days before admission, when she began to complain of severe headache and of not feeling well. The headache gradually became worse, and on the morning of April 4th a doctor was called in for the first time. On the following day (April 5th) the patient was found unconscious in her bedroom, and passed through a succession of fits in which the arms and legs twitched and the face was drawn to the right; urine and fæces were voided during the attacks. The convulsions continued incessantly until the patient was put under the influence of chloroform. The medical man who was called in found albumen in the urine and made the diagnosis of puerperal eclampsia. There was no illness of any kind in the house.

Post-mortem examination showed that death was due to a purulent meningitis occurring in a pregnant woman, that the meningitis was caused by the pneumococcus, and that there was no disease of the lungs or kidneys. The body was well developed and well nourished; there was no œdema or glandular enlargement. The pregnant uterus extended as high as an inch above the umbilicus; it contained a healthy fœtus of about six and a half months' development, 29 oz. in weight, and 13 inches in length. The placenta, placed anteriorly and to the left, was normal in appearance, and so were both ovaries and Fallopian tubes. There was no pericarditis, pleurisy, or peritonitis. The heart weighed 11 oz. and showed slight hypertrophy of the left ventricle, but was otherwise healthy. The right lung weighed 19 oz. and the left 15 oz.; in each the upper lobe was œdematous, and the lower lobe congested and œdematous. Œsophagus, stomach, and intestines

were all healthy; the liver, large and fatty, weighed 80 oz.; the spleen was large and diffluent, and weighed 12 oz.; the pancreas and supra-renals were normal. The kidneys, each weighing 5½ oz., were very congested, but otherwise appeared quite healthy; the ureters, bladder, and urethra showed no abnormal appearances.

The brain was small, weighing 41 oz.; its surface was covered by a dense layer of yellowish creamy pus, which completely invested the whole cerebrum, vertex as well as base, the cerebellum, the pons, and the medulla. On section neither the grey nor the white matter showed any naked eye changes; the ventricles were not unduly distended; there were no signs of tubercle, middle ear disease, or pneumonia; nor was there any septic focus.

A stained film, made from the purulent exudate on the meninges, showed among the pus cells numerous diplococci, here and there joined to form short chains of two or three pairs; the individual cocci were pointed, their long axes being from end to end; they were encapsuled, and retained Gram's stain. A stroke culture on agar after twenty-four hours' incubation at 36° C. showed a nearly transparent film, consisting of minute spherical colonies very closely set in the centre of the film, but more discrete at the edges. The colonies were found to be composed of diplococci, having the same characters and giving the same staining reaction as those seen in the preparation of the pus. The diplococci found both in the stained film and in the culture resembled in size and shape Fraenkel's pneumococcus.

Remarks.—This case emphasises the importance of making an autopsy complete, and especially of never omitting the examination of the brain in any case where cerebral symptoms have been present during life. It would have been easy for a hasty and incomplete examination to have led to the conclusion that here had been a case of eclampsia. There is, so to speak, no constant morbid anatomy for the affection. The changes that are most commonly found affect the kidneys, but in some

cases even the most careful examination fails to discover any lesion of these organs, while in many others the changes are insignificant. As a matter of fact, eclampsia is accompanied or caused by a sudden break-down of kidney function, and this may take place in organs that have apparently been previously healthy, or in those that have long been known to be organically diseased. The slightness of the renal affection that was found after death in this case would therefore have presented no difficulty in accepting the diagnosis of eclampsia.

The relation of the presence of sugar observed in the urine obtained just before death is obscure. Was the glycosuria an independent co-existing affection? was it caused by the meningitis? or was it an example of the glycosuria sometimes found in the later months of pregnancy? The glycosuria occasionally found in pregnancy is due to absorption of sugar from the breasts, and is usually in small quantities. The notable amount found in the present case was, in all likelihood, dependent upon the meningitis, and connected in some way with the enlarged and fatty liver. What stress, if any, should have been laid upon the observation of such a degree of glycosuria I am unable to say, and this is a point that deserves attention in future observations.

Finally, an important principle of special interest from the obstetrical point of view is illustrated by this case. If any particular form of treatment, as, for instance, by saline infusion or by morphia, had been undertaken, and if no autopsy had been made, the failure of the measures undertaken might seriously have shaken one's confidence in their utility. Too much importance, therefore, must never be attached to conclusions as to the futility of any form of treatment based upon cases of the affection in which no *post-mortem* examination has been made.

The PRESIDENT quite agreed with the author that in every fatal case a thorough autopsy ought to be made, in order to eliminate or discover any cause of fits other than the albuminuria.

Dr. Amand Routh thought that this case was of great importance, if only to remind obstetricians that essential conditions might be the cause of convulsions during pregnancy. He was much interested in the glycosuria found in this patient, and wondered if it were due to the cerebral disease. He pointed out that the glycosuria could not have been due to absorption from the mammary gland.

Dr. Herbert Spencer said that this important case emphasised the necessity of great care in the diagnosis of "eclampsia." Absence, or a small amount of albumen, should especially put us on guard. He had seen two such cases in which there was no history of epilepsy and no sign of hysteria. One of the patients had always a severe convulsion with the loss of consciousness during coitus; they ceased entirely after the birth of the first child, and the patient had recently borne a child normally. He also had known septic meningitis give rise to fits in a glycosuric patient, from whom a pyosalpinx had been removed.

TWO UTERI REMOVED BY ABDOMINAL PAN-HYSTERECTOMY FOR CANCER OF THE BODY.

Shown by Dr. Lewers.

Dr. Lewers said that in cases of cancer of the uterus which come under observation at a time when operative treatment of a radical nature is indicated, there could be no doubt that for the large majority the vaginal route was the most suitable for the removal of the uterus. As regards cancer of the cervix, almost all the advantages appeared to be on the side of vaginal hysterectomy. Thus, in the latter operation, the exact position and extent of the growth were clearly visible, and the incisions in the vaginal mucous membrane could be made as far as possible from the edge of the growth. Another advantage, which he himself believed to be of some importance, was that the cut edges of the vaginal mucous membrane and the adjacent submucous connective tissue could, in vaginal hysterectomy, be freely seared with the cautery. Apart from some coincident pathological condition, such as the presence of fibroids, the body of the uterus was not en-

larged in cancer of the cervix, so that in vaginal hysterectomy there was usually no difficulty in removing the body of the uterus on account of its size. Again, there was, as a rule, less general disturbance after vaginal hysterectomy,—less tendency to vomiting, distension, rapid pulse, and less pain,—than in operations involving opening the abdomen in the usual position. In a purely abdominal pan-hysterectomy for cancer of the cervix the vagina had, of course, to be opened into from above, and the incision might or might not clear the malignant growth. Some portion of it was almost certain to be left behind, and the operation thereby be rendered useless. It was true that this objection might be met by performing a combined operation, partly from below, freeing the cervix as in the first stage of a vaginal hysterectomy, and then completing the operation from above. This procedure would, he thought, be generally admitted to be at least inconvenient, owing to the loss of time in altering the position of the patient, and having again to go through the processes for disinfecting the hands prior to opening the abdomen. At least this had seemed so to him in the few cases—some of them for uterine fibroids—in which he had adopted it.

Again, in abdominal hysterectomy it was far easier to remove the upper portion of the broad ligament with the tubes and ovaries than when the operation was performed from below, but in cancer of the cervix this was a matter of little or no importance, since the disease had no tendency to spread in the direction in question, at all events at a stage of the disease when hysterectomy was likely to be performed.

Another point was that if ligatures were used to secure the vessels, these could be tied, as a rule, much more securely in abdominal than in vaginal hysterectomy. Still, as a matter of experience, there was rarely any difficulty in sufficiently securing the vessels in the latter operation, either by ligatures or pressure forceps.

There was one more question to be thought of in considering the operation to be chosen in cases of cancer of

the cervix. He referred to the infection of the lymphatic glands. If it were the fact, as was maintained by some authorities,* that the glands were always or generally affected in those cases of cancer of the cervix in which, as far as physical examination could ascertain, the disease had not spread beyond the limits of the uterus, no operation would be satisfactory by which these glands were not removed; and hence abdominal hysterectomy with removal of the glands would have to be the routine operation in all cases of cancer of the uterus, whether of the cervix or of the body, when any radical operation was to be done at all. But it was certainly not the fact that the glands were always affected at a stage of the disease when hysterectomy would be contemplated, nor did he believe it to be anything but a very unfrequent occurrence at the stage of the disease in question. The proof of this lay in the after-histories of cases operated on for cancer of the uterus in which the glands had not been removed. Among his own cases he had recorded a series of forty vaginal hysterectomies for cancer in the 'Transactions' of the Royal Medical and Chirurgical Society of London.† The specimens and sections of them were shown at the meeting at which the paper was read, and the malignant nature of each was admitted. Yet among them he was able to point to twelve cases out of forty in which the after-history of the patient was known, and in which the disease had not recurred. Two of these remained well seven years after the operation, one six years, one five years and a half, one five years, one nearly five years, one nearly four years, one more than three years, two nearly three years, one more than two years, and one more than one year. He might instance, also, several cases from an earlier series of operations for cancer of the cervix in which he merely performed the supra-vaginal amputation of the cervix. Some of the patients were

* *E. g.* by Dr. Jacobs, of Brussels.

† At the meeting in November, 1900.

known to be well many years after the operation. In each case the specimen and sections were exhibited at the meeting* of the Royal Medical and Chirurgical Society at which the paper recording the cases was read, so that there could be no doubt as to the disease being cancer. It was clear that the after-histories of these cases sufficiently proved that the glands were not by any means always affected in cases of cancer of the uterus at an operable stage. His own belief was that when the glands were affected the disease had usually already advanced beyond the limits of the uterus, either to the vagina or connective tissue round the cervix, and any operation having for its object the cure of the disease, or even prolonged freedom from recurrence, was already *ipso facto* contra-indicated.

We might therefore conclude that for cases of cancer of the cervix requiring removal of the uterus the operation of election should be vaginal hysterectomy.

When, however, we came to consider cases of primary cancer of the body of the uterus, we were on much more debatable ground. In cancer of the body of the uterus the cervix, and especially the vaginal portion of the cervix, was generally altogether unaffected. At times, in rare instances, the malignant growth had spread a variable distance down the cervical canal, and it might even show at the external os uteri. This was a very rare event, and even when it occurred the outer surface of the vaginal portion was not involved. Hence in performing abdominal pan-hysterectomy, when the vagina was opened into from above, so long as the incision cleared the cervix—and it was a matter of no particular difficulty to make sure of this,—there was no risk of leaving some of the malignant growth behind. Again, the body of the uterus was considerably enlarged, and, on the other hand, as the subjects of this disease were for the most part elderly women, and between fifty and sixty, or older, the vagina was narrow from the contraction due to the

* At the meeting in December, 1892.

senile atrophy occurring after the menopause. As many of the patients were sterile, the vagina had, even before the menopause, not been dilated to the capacity found in parous women. Both on account of the size of the uterus and of the narrowness of the vagina, removal of the uterus from below was a more difficult matter than from above. In abdominal hysterectomy, also, the fact that it was an easy matter to remove the ovaries and tubes with a good width of the upper part of the broad ligament on each side of the uterus was, in primary cancer of the body, a distinct advantage. An objection to the abdominal route deserving mention was the risk of fouling the peritoneum with the discharge escaping from the os uteri as the uterus was brought upwards. This might, however, be avoided by passing a stout ligature through the vaginal portion of the cervix, so as to encircle the os, and tying it tightly.

One more important question was the relative mortality of the two operations. Soon after Czerny had reintroduced vaginal hysterectomy in 1879, Freund began to remove the uterus by abdominal section. The mortality, as stated in Greig Smith's work on abdominal surgery, was nearly 70 per cent. The mortality of vaginal hysterectomy for cancer about the same time, or within the next five years, was in the neighbourhood of 30 per cent. Thus, the abdominal method being so much the more dangerous, gradually fell into complete disuse, and for some years vaginal hysterectomy was alone practised. Though the operation for cancer had been abandoned, the technique of abdominal hysterectomy for fibroids continued to receive the closest attention from many operators. In this way were evolved the two operations for fibroids now in favour: first, abdominal hysterectomy, with intra-peritoneal treatment of the cervical stump, the essential point in the operation being the ligature of the uterine arteries outside uterine tissue; and next, abdominal pan-hysterectomy, or removal of the whole uterus by an operation conducted entirely from

above. Both these operations had now a very low mortality, probably not exceeding 5 per cent. He was led to perform abdominal pan-hysterectomy for fibroids by reading Martin's paper in the 'Transactions of the Edinburgh Obstetrical Society for 1896,' and he had adopted it in five cases, all of which made uneventful recoveries, though in most of his hysterectomies for fibroids he had been quite content with abdominal hysterectomy, with intra-peritoneal treatment of the stump. Of course, it must not be forgotten that during the period in question the mortality of vaginal hysterectomy for cancer had also been greatly reduced. In his own series of forty cases, already referred to, the mortality, for instance, was 7½ per cent.

It was probably not far from the truth to say that at the present time, in the case of an operator who had had experience in both operations, there was not much difference in the mortality of abdominal pan-hysterectomy and vaginal hysterectomy for cancer.

On the whole, therefore, it seemed to him that for cancer of the body of the uterus abdominal pan-hysterectomy had in many cases preponderating advantages.

Although, as above mentioned, he had performed abdominal pan-hysterectomy for fibroids, he had as yet only performed the operation for cancer of the body of the uterus in two cases, the notes of which were as follows.

Case 1.—Mrs. R—, aged 54, came to see me on February 12th, 1900. She had been married fifteen years, but had never been pregnant. She had been quite regular up to the age of fifty, when she had synovitis, and stayed in bed for some time, after which menstruation ceased altogether. In July, 1899, she began to have some vaginal discharge. It was at first colourless, but afterwards sometimes yellow and sometimes of a brown colour, and continued up to the time I saw her. She had had no pain at all, and did not think she had lost weight. The discharge had at times had an unpleasant smell.

There was nothing else in the history of any special interest. Nothing abnormal was detected on examining the abdomen. On vaginal examination the external genitals were redder than normal, and slightly sore-looking, and there was some yellow discharge at the vaginal orifice. The vagina was extremely narrow, and examination with one finger caused a good deal of discomfort. The examination was not very satisfactory on this account, but as far as could be made out the uterus was freely movable, and the internal os rather small. There was nothing abnormal as regards the vaginal portion of the cervix. The extreme narrowness of the vagina was shown by the fact that the patient could not bear the smallest Fergusson's speculum to be passed. A small rectal speculum was, however, passed into the vagina, but as it was rather less than half the length of an ordinary Fergusson's speculum it only showed the lower two inches of the vaginal walls, which were thickly covered with the yellow discharge above mentioned. I advised the patient to have the cervix dilated sufficiently to allow the interior of the body of the uterus to be examined with the finger. She consented to have this done, but as she wished to return to the North of England for a fortnight, it was not till March 1st that she entered Fitzroy House. The next day, March 2nd, with the usual antiseptic precautions, a specially prepared laminaria tent was inserted into the cervix. To do this, owing to the narrowness of the vagina, it was necessary to have the patient anæsthetised. Speaking from memory, I believe I have only once before found it necessary to have a patient anæsthetised for the insertion of tents, so that it would be seen that the narrowness of the vagina is such as to cause real difficulty in dealing with the case. On the next day, March 3rd, the dilatation of the cervix was completed under an anæsthetic with Hegar's dilators. A growth was found high up in the endometrium; a portion of it was removed for microscopic examination, though I felt little doubt after the

digital examination of the endometrium that the growth was malignant. The portion of growth removed was sent to the Clinical Research Association, and Mr. Targett reported that it was carcinomatous. The patient was accordingly advised to have the uterus removed, and to this she consented.

Operation (April 11th, 1900).—The preliminary dilatation of the cervix for diagnosis had been so difficult on account of the narrowness of the vagina, that I decided

to remove the uterus by abdominal pan-hysterectomy. The method was the same as that I adopted in four cases of pan-hysterectomy for fibroids, an account of which was published in the 'Lancet.'* In this case the vagina was douched with 1 in 1000 perchloride of mercury just before the operation, but I did not make any attempt to occlude the cervix by a suture, or to pack it, before beginning the abdominal section. The right

* 1899, vol. ii, p. 82.

uterine appendages were removed with the uterus, but the left appendages were not removed. The ligatures on the uterine arteries and on vessels in the cut edges of the vaginal walls were left long and drawn down into the vagina by long Wells' forceps passed up from the vagina by an assistant. A gauze drain was drawn down from above into the vagina, about an inch of it being left projecting into the peritoneum. The abdominal wound was completely closed. The patient made an uninterrupted recovery, and the ligatures came away at the end of the fifth week.

Description of the specimen in Case 1.—The uterus has been laid open by an incision from the external os to the fundus through the anterior wall. The extreme length of the uterus is 3 inches. At the extreme highest point of the endometrium, and extending downwards for an inch and a quarter on the posterior wall, is a new growth projecting only slightly above the general surface of the endometrium. Its surface is faintly papillary. A sagittal section has also been made through the growth and the wall of the uterus from which it springs. This shows that the growth penetrates deeply into the uterine wall, the limit of its penetration, to the naked eye, being marked by a sinuous, irregular, whitish border.

A portion of the growth was sent to the Clinical Research Association. The report on it is as follows: —"The wall of the uterus is deeply invaded by a very soft columnar-celled carcinoma. The growth is much degenerated, and therefore stains badly. It is a primary carcinoma of the body of the uterus."—(Signed) J. H. Targett.

Case 2.—H. J—, aged 57, was admitted under my care into the London Hospital on October 5th, 1901, at the request of Dr. Taylor, of 285, Victoria Dock Road, E.

Previous history.—She had been married thirty-six years, and had had six children, the last twenty-one years ago, and two miscarriages, the last nineteen years ago.

Menstruation began between sixteen and seventeen, and occurred regularly every four weeks without any pain. Two years and a half ago menstruation ceased for ten months, then the periods came on at monthly intervals for three months. Each of these periods was like what she had always had, except that she lost a larger quantity than formerly, and clots were passed.

Previous health.—She had been subject to bronchitis

and asthma up to last year; she used to have quinsy twenty years ago. There was no history of syphilis. She had never had any severe illness. Her family history was good.

Present illness.—Two years and a half ago the "periods" ceased for ten months. Then they recurred at monthly intervals for three times; after that, however,

the loss of blood became more or less continuous. Sometimes clots were passed, but the discharge had never been offensive. The discharge during the last three months had not been quite so profuse as before, but she had constantly had to wear a diaper. Since April this year (1901) she had had pain on the right side running from the back to the right groin, and also aching in the right thigh. It was not constant, sometimes she was free from pain for twelve hours. When present it was aching, with an occasional severe shooting or cramping feeling. Sometimes the pain had made her sick and caused her to perspire, especially at night. It was relieved by sitting up or by walking about, and sometimes by alcohol.

She had had no trouble with micturition. The bowels had been constipated, and she took aperients frequently.

During the eight months before admission she had lost 2 st. in weight.

From the above account it appeared that there had been a more or less constant blood-stained discharge for about seventeen months, and that she had had pain for six months prior to her admission to the hospital.

State on admission (October 5th, 1901).—She was not anæmic; she had a rather worried expression; her weight was 9 st. 2 lbs.

October 7th.—She was anæsthetised, and a careful examination was made with the patient in the lithotomy position. With Sims's speculum it was seen that the vaginal portion of the cervix was healthy, except for a slight erosion of the posterior lip. The cervix when drawn upon with a volsella did not come down well. Bimanually the uterus was found to be enlarged, but only fairly movable; the sound passed 3½ inches. The cervix was dilated up to No. 19 Hegar without any difficulty, there being only slight resistance as each dilator was passed, and that at the external os. The finger passed into the uterus came upon a growth chiefly on the posterior wall; it was not of the soft papillary variety. It terminated below by a raised, somewhat rounded

border. The growth extended so low in the body of the uterus that it was not quite certain at this examination that the growth had not extended into the cervical canal. (Subsequent examination of the specimen, however, showed that it had not involved the cervix.) There was no offensive smell about the examining finger.

Operation (October 14th, 1901).—The patient was anæsthetised and put in the lithotomy position. After disinfecting the vagina as well as possible with 1 in 1000 perchloride of mercury lotion, the cervix was exposed and seized with a volsella. A stout silk ligature was passed through the vaginal portion with a strong needle in a handle, from behind forwards on the left side of the os uteri. The needle, unthreaded, was then passed similarly on the right side of the os, threaded with the anterior end of the ligature already passed, and withdrawn. The ligature was then tied as tightly as possible, thus occluding the external os.

The patient was then put into the Trendelenburg position, and abdominal pan-hysterectomy was performed. The right uterine appendages were removed, but the left appendages were not removed. There were some adhesions on the left side which had to be separated before the uterus could be drawn up freely. The limited mobility of the uterus observed at the previous examination was no doubt due to these adhesions. When the uterus had been removed, all the ligatures were drawn into the vagina, and a strip of iodoform gauze was also drawn from above into the vagina. About one inch of it was left projecting into the peritoneal cavity. The abdominal wound was then completely closed. The subsequent progress of the case was uneventful. The ligatures were not loose when she left the hospital; they were cut a good deal shorter a few days before she went away, so that it would be impossible for any of them to project from the vagina. She went to a convalescent home on November 9th.

Description of the specimen in Case 2.—The uterus has

been laid open from the front. Its extreme length is 3¾ inches. The cervix, to the naked eye, appears quite healthy, and is very short. Almost the whole of the endometrium is occupied by a new growth. This is raised about a quarter of an inch above the general level, and its edge distinctly overhangs the adjacent apparently healthy endometrium. In the downward direction the growth extends very nearly to the internal os, and terminates by a semicircular border, convex downwards.

A portion of the growth was sent to the Clinical Research Association. The report on it is as follows :— "This is a columnar-celled carcinoma of the body of the uterus, originating in the endometrium and invading the muscular coat. The tubular arrangement of the cells is very distinct."—(Signed) J. H. Targett.

Note.—Sections of the growth in each case were exhibited under the microscope at the meeting at which the uteri were shown.

Dr. McCann referred to the case of a patient upon whom he had operated for cancer of the body of the uterus who gave a history similar to that of Dr. Lewers' patient, viz. brown vaginal discharge for some months with complete absence of pain. At the operation a hæmatometra was discovered, together with a cancerous growth situated in the upper part of the body of the uterus. He thought that in operating for cancer of the body of the uterus the ovaries, tubes, and broad ligaments should be removed in every case in order to minimise the chances of recurrence.

Dr. Amand Routh much preferred the combined abdomino-vaginal route for cases of cancer of the uterus, which was too large to be removed *per vaginam*, freeing the cervix from below, tying off the bases of the broad ligament, separating the bladder, and opening Douglas's pouch, thus leaving very little to be done from above, and making sure that all vaginal disease was removed. He thought the tubes should always be removed if the growth had invaded the uterine cornua.

Dr. Herbert Spencer asked Dr. Lewers for the name of the authority who stated that the glands are always affected in operable cases of cancer of the cervix. He (Dr. Spencer) was not aware that anyone had made such a statement. What Lameris and Kermauner had shown was that in 57·5 per cent. of such cases the hypogastric and iliac glands are affected

('Centralblatt für Gynäkologie,' 1901, p. 590). Wertheim also has found cancerous glands in 31·7 per cent. of all cases operated on, and in 15 per cent. of the early and moderately advanced cases ('Archiv für Gynäkologie,' vol. lxv, Heft 1, p. 1). These important observations received support from the cases in which occasionally growth appeared in the iliac glands soon after the removal of the cervix or uterus for cancer, which appeared to be in the early stage. It did not follow that abdominal hysterectomy with removal of the ligaments and glands was to be performed in every case. That operation had a high rate of mortality, and excellent results followed high amputation with the cautery; but it was to be hoped that the researches alluded to would lead to some means of recognising the cases in which the glands were infected, for which abdominal hysterectomy with removal of the glands was the only rational operation. He feared, however, that it was a hopeless task to completely remove the iliac glands, and, as far as he knew, no case had yet been operated on by this method and watched afterwards for a period of five years. He had removed the uterus by the abdomen, after preliminary separation of the cervix *per vaginam*, for cancer of the body in three cases, and he thought the operation should be done in preference to vaginal hysterectomy in all cases where the uterus was large or the vagina small. He had always closed the cervix with stitches, but thought the ligature as used by Dr. Lewers was preferable; it was advisable, in addition, to pack the uterus with dry gauze. He (Dr. Spencer) advocated the abdominal route in preference to the vaginal in the cases mentioned, because, although the vagina could be easily enlarged by Schuchardt's incisions, the uterus was very difficult to remove absolutely entire through the vagina, and any laceration of the organ would give rise to risk of cancer implantation on the cut surfaces; the operation was, however, certainly more dangerous when performed by the abdominal than by the vaginal route. He was in favour of completely closing the peritoneum in abdominal pan-hysterectomy; leaving a piece of gauze in the peritoneum would be more likely to give rise to intestinal adhesion and obstruction than complete closure of the peritoneum by suture.

A CASE OF CHORIO-EPITHELIOMA WITH PULMONARY METASTASES.

By Cuthbert Lockyer, M.D., F.R.C.S.

(Received December 9th, 1901.)

(*Abstract.*)

In this case the evidence of an abortion lay in the fact that the patient lost blood freely four months before admission, the loss continuing until the case was sent to hospital.

The patient was forty-two years of age. She had given birth to seven children. The last confinement took place three and a half years before admission into the Samaritan Hospital. Three abortions are recorded, the last being thirteen years before the patient was sent to the above hospital.

The patient was admitted with evident uterine enlargement, and in a condition which prohibited operative interference. The uterus was perforated by a new growth in its walls, and secondary deposits were found in the lungs.

The pathological characters of the primary and secondary growths are described at length in the paper.

Pathological proof of the occurrence of chorio-epithelioma immediately following on the removal of hydatidiform mole is also added.

I am indebted to my senior colleague, our late President, for allowing me to bring this case before the notice of the Obstetrical Society. Mr. Doran has further given me free access to his clinical notes of the case.

The following is an extract of these notes:

A. D—, aged 42, was admitted into the Samaritan Free

Hospital on November 20th, 1900, complaining of an abdominal tumour and of having lost blood freely since June 4th of the same year. The patient had been married for twenty years, was the mother of seven children; the last confinement took place three and a half years before admission, when she gave birth to "pigeon twins." Three premature labours had previously occurred, before one of which she bled all through the pregnancy (*i.e.* for six and a half months), and at the end of this long period of bleeding "a false conception" came away. This happened thirteen years prior to admission. Details of the other two premature confinements are not given. All labours were instrumental. Until June, 1900, her periods used to occur every three weeks, the show lasting four days, and eight to ten towels were used.

The patient had typhoid fever when nineteen years of age; she married at the age of twenty-two, and during her married life suffered from ulcers of the left leg and "swollen veins"—a point of interest, as will be presently explained. The case was sent to Mr. Doran by Dr. Anty, of Willesden, who wrote on November 13th saying that he was sending a woman suffering from a uterine tumour which had been diagnosed on October 10th by an obstetric physician as pregnancy at four and a half months. He himself rightly suspected malignancy. Two days later (October 12th) she was taken much worse, and flooded so severely that she was confined to her bed for a time, but at the date of writing (November 13th) she was able to get about. No definite history of a recent abortion could be obtained from the patient nor from her doctor. Examination on admission revealed an irregular elastic mass occupying the hypogastrium and rising into the umbilical region, ascending higher on the left than on the right side of the mid-line. The os uteri was patulous, and the uterine cavity measured 5 inches; nothing could be felt in the fornices. On consultation it was agreed that the patient was not in a fit state for any operation.

On December 19th much tympanites and tenderness were first noted ; this subsided by the next day, when the uterus was felt to be freely movable on bimanual palpation. She had lost much flesh since admission, and there had been much blood and foul discharge *per vaginam*. The nocturnal temperature was always high, especially since December 1st, from which date it varied from 100·8° F. to 102·8° F. She had several rigors and frequent attacks of pelvic and abdominal pain. The urine was always loaded with urates, and contained a large trace of albumen, but no sugar. On January 24th the patient had a rigor and a pulse rate of 160 ; this fell to 96 in a few hours, and death occurred on January 25th at 9.25 a.m. A post-mortem examination was made by Dr. Cecil Bosanquet, the pathologist to the Samaritan Hospital, who reported as follows :—The body was considerably emaciated ; rigor mortis was feeble, but present twenty-four hours after death. There was no general peritonitis. The coils of small intestine were adherent to the top of the uterus and to one another, forming to some extent a roof to the pelvis. Here there was much old and recent peritonitis, chiefly recent, with effusion of lymph and of some blackish fluid, the latter being derived from a sloughy-looking ragged aperture situated upon the posterior wall close to the fundus of the uterus, with the cavity of which it communicated. Most of the adhesions were easily broken down, so that the uterus was practically free. The liver weighed 4 lbs. 12 oz., was "nutmeg" in appearance, but otherwise normal. No secondary deposits were discovered in the abdomen. The spleen was normal, and weighed 6½ oz., the left kidney weighed 6½ oz., the right 5½ oz. ; their capsules were somewhat adherent, and there was cloudy swelling of the tubules. The adrenals and pancreas were normal, as were the stomach and intestines, except for the adhesions in the pelvic region already mentioned.

The uterus was large—nearly 6 inches in length,—not adherent to neighbouring structures (except to the

DESCRIPTION OF PLATE I.

Illustrating Dr. Cuthbert Lockyer's specimen of Chorio-epithelioma.

Uterus opened from behind, showing the growth invading the body as far as the internal os.

Illustrating Dr. LOCKYER's Paper on Chorio-Epithelioma with Pulmonary Metastases.

Engraved and Printed by Bale and Danielsson, Ltd.

omentum and some coils of intestine roofing over the pelvis). At the upper portion of the body of the organ on its posterior aspect was an aperture with blackish, ragged, sloughy walls, communicating with the cavity of the uterus. The organ was preserved for further examination. The appendages were not diseased, the pleural and pericardial cavities were free. Both lungs were studded throughout with nodules of new growth, very vascular in appearance, varying in size from that of a large walnut to that of a cherry-stone; the lower lobes were deeply congested. The heart weighed 11½ oz., and appeared normal; its cavities were full of blood-clot, and the right side was somewhat dilated. The brain and spinal cord were not examined. Dr. Bosanquet sent me the uterus and appendages, with portions of the lungs. The specimen, as I received it forty-eight hours after death and twenty-four hours after removal from the body, was in a decomposing condition, and consisted of the uterus, vagina, rectum, bladder, and ureters, and the external and internal iliac arteries, to the latter of which were attached, on the left side, some enlarged iliac glands. The lung was better preserved, having been at once put into Kaiserling's solution. The broad ligaments were quite free of exudate, and showed no sign of adhesions, old or recent. The vessels, both arterial and venous, were enlarged, the veins of the left broad ligament especially so, being tortuous and varicose; an attempt to inject these veins with coloured size failed, as they were "button-holed" in many places in their removal from the body. Two small glands the size of cherry-stones were found in the left broad ligament; these shelled out with ease from the surrounding connective tissue. The enlarged iliac glands were very different, being adherent to the left external iliac vessels; the largest measured 2 cm. by 1 cm. On section they presented no necrotic areas nor hæmorrhages to the naked eye, having only the appearance of chronic inflammation. The enlargement seemed clearly due to the old ulcers on the corresponding

lower extremity. The round ligaments of the uterus were thickened. The right Fallopian tube measured 10 cm., was pervious throughout, and was not thickened. The right ovary was normal, measuring 2 by 2 cm.; its ligament was thickened and short.

The left tube measured 8 cm.; its lumen was patent, and its walls somewhat thickened. The right ovary measured 5 cm. in its long diameter; it was enlarged owing to a thin-walled cyst in its outer part, which measured 2·6 cm. in long diameter and contained clear golden fluid. The ligament of the right ovary was reduced to a mere stump, so that the ovary was close to the uterus. The bladder was normal in size, was quite free from the surrounding structures, the vesico-uterine pouch being quite empty. The walls were healthy and of normal thickness, and the mucosa was not injected. The vaginal mucous membrane was healthy. The rectum, urethra, and ureters were all normal. The enlarged uterus had a lateral deflection to the right side, and was somewhat club-shaped. Its vertical measurement was 13·5 cm.; its fundus rose 5·5 cm. above the level of the attachments of the Fallopian tubes, the latter being 10·5 cm. apart. The vaginal cervix was œdematous, and the lips eroded; the os was very patulous, and from it a fœtid dark discharge escaped. The posterior lip was elongated, and the cervical canal measured 6 cm. in length; its mucous membrane was florid in colour and spongy in consistence. The cervical wall measured 1·5 cm. in transverse section. There was no growth in any part of the cervix. The corpus uteri measured 7 cm. vertically. It was occupied in its entire extent by a growth, the characters of which are given below. The posterior surface of the body had been perforated close to its upper extremity by ulceration of the growth. The edges of the perforation are extremely thin (2 mm.), ragged, irregular, deeply pigmented, and sloughy. The perforation ran across the transverse diameter of the organ and measured 6 cm. The growth consisted of a

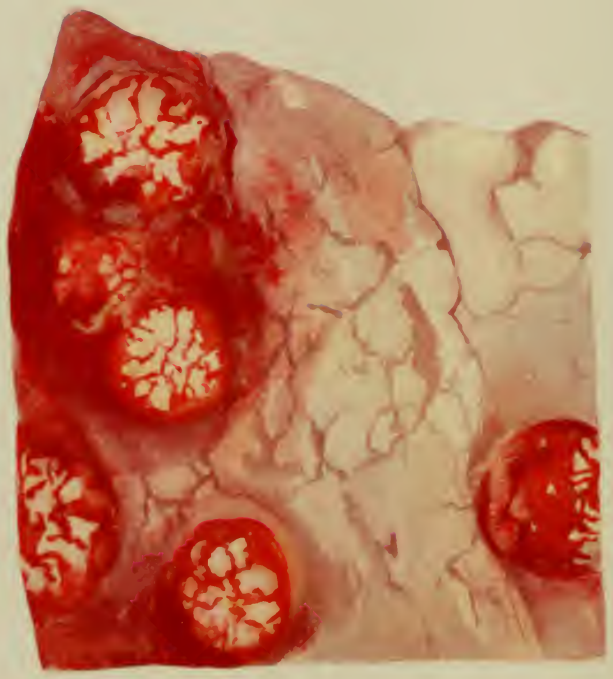

Fig. 1.

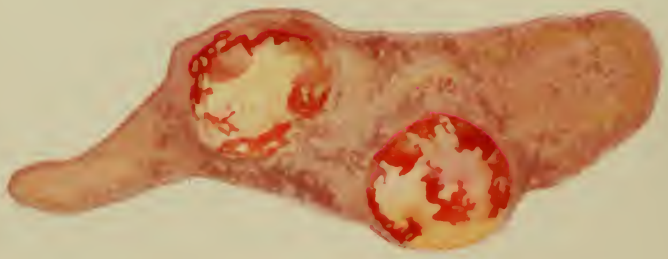

Fig. 2.

Illustrating Dr. LOCKYER'S Paper on Chorio-Epithelioma with Pulmonary Metastases.

Cassell Printed by Arthur Cox Dorchester, Ltd.

DESCRIPTION OF PLATE II.

Illustrating Dr. Cuthbert Lockyer's specimen of Chorio-epithelioma.

Fig. 1.—Surface of lung, showing the secondary growths in their natural colour and size.

Fig. 2.—Transverse section of lung, showing invasion by two secondary nodules.

congeries of rounded and oval bosses fused together, and of a deep sepia colour. It formed the entire lining of the body of the uterus, but ended abruptly at the os internum. The largest bosses of growth occupy the uterine cornua on either side, that on the left being spherical in shape with a diameter of 2 cm., that on the right side oblong with a long diameter of 2·5 cm. ; the rest of the growth, though tuberous, was more sessile. The thickest part of the uterine wall—that just above the internal os—measured ·75 cm. in section ; proceeding upwards the wall gradually thinned away towards the perforation. The uterine cavity was distended into a large sphere by the growth, its dimensions being 6·5 by 5 cm.

The lungs were studded throughout with rounded nodules, most numerous immediately beneath the visceral pleura ; these nodules varied in size from one measuring 5 by 4 cm. to others the size of a pea ; they were flattened and discoid as seen from the surface, but oval on section. The surface of the growths was of a deep maroon colour, and on section this hæmorrhagic area formed a peripheral ring around a pale grey centre which cut like a soft sarcoma, and presented a smooth homogeneous surface. Where the lung was thinnest the nodules extended nearly through its entire thickness. Some nodules were hæmorrhagic throughout. The bronchial mucous membrane appeared healthy. The bronchial glands were small and filled with particles of carbon.

Microscopic sections of the primary uterine growth were taken from six different levels, beginning above at the margin of the perforation and extending down to the thickest muscular part at the margin of the internal os.

Sections were also made of the two small glands found in the left broad ligament, of the larger iliac glands adherent to the left iliac vessels, and of several pulmonary growths. The main features revealed in sections of the primary growth may be summed up as follows :

1. The uterine mucosa ceases to be distinctly recognisable where the growth begins, that covering the muscle in

the neighbourhood of the growth (*i. e.* at the internal os) being infiltrated and degenerate.

2. The muscularis is deeply invaded by a small-celled infiltration, and the venous channels contain cellular emboli at a considerable distance from the growth.

3. The muscularis is invaded by protoplasmic masses in which no differentiation of individual cells is possible, and also by large cells of various shapes and sizes containing either a single large granular nucleus or two or more smaller nuclei.

4. The individual muscular bundles are widely separated, the intervals being sometimes filled by the above cellular elements or by leucocytes, but in other cases being empty, having been probably filled originally by œdematous fluid.

5. Large hæmorrhagic areas occur in the muscularis; these areas have no endothelial lining and lie apparently free between the widely separated muscle-fibres.

6. The muscle-cells are in every stage of atrophy and degeneration; their nuclei are swollen and granular, but for the most part maintaining their spindle shape; their protoplasm in some cases stains badly or refuses to stain at all.

7. The walls of the uterine arteries are thickened, and the lumina (as also those of the veins) are filled with thrombi, in which an undue proportion of white cells are seen deeply stained with hæmatoxylin, appearances suggesting the presence of acute inflammation of the muscle tissue coupled with degeneration.

The sections of the growth itself show that it is largely made up of necrotic tissue and remains of hæmorrhage, the latter consisting of strands of fibrin arranged in alveolar spaces, which have no endothelial lining or wall of any kind, but around which are often grouped large uni- and multinuclear cells and masses of multinuclear protoplasm. No red discs are seen in this fibrinous meshwork, but they are invaded by an abundance of leucocytes sufficient in number to obscure in

parts the fibrinous matrix in which they lie embedded. Where the leucocytes are absent the meshes of fibrin are filled up with granular *débris*. A section of the most prominent nodule presents nothing but a mass of fibrin, with here and there a large necrotic cell devoid of a nucleus, and which stains with eosin only. These cells, when present, are arranged along the thicker strands of fibrin which divide the area into more or less complete compartments. No leucocytes are seen invading this nodule, and the entire section of 2 cm. in extent stains with eosin only. In a section made to include the superficial layers of the muscular wall and the deeper portions of the growth, large fibrinous areas are still seen, but the growth becomes more cellular and protoplasmic. The larger cellular areas present an alveolar structure with clear empty spaces like those seen in connective tissue distended with fat. These empty spaces have walls of varying thickness; between some of them the walls have given way and two spaces become fused into one. This condition seems akin to that figured in Cullen's work, 'Cancer of the Uterus,' p. 607, as a feature of the growing neoplasm. It is, however, the result of degeneration, and perhaps the work of some gas-producing organism. Adjacent to such areas are seen columns of protoplasm spreading out amongst hæmorrhages as solid bands; in them are seen polymorphic nuclei, which, in some instances, are undergoing karyokinesis. In other areas the protoplasm occurs in extensive plates from which proceed columns of various shapes and sizes which join up to form other smaller masses, and also to include other hæmorrhagic areas. The protoplasmic plates are vacuolated, as also are the larger bands, whilst in the protoplasmic plates the nuclei are arranged without any definite order, being in some places close together and in others more widely separate; in the columns they are seen arranged in single or in double rows. There are outlying cells adjacent to the columns which appear as buds of the same; these are

epithelioid in character, containing large nuclei which occupy the greater part of the cell, and which stain deeply with logwood; the nuclear protoplasm is for the most part granular, and shows a chromatin network; now and then a distinct nucleolus is visible. Such tissue as that just described occurs only in the deeper parts of the growth, lying between the more superficial necrotic tissue and the large hæmorrhagic areas on the one hand, and the muscularis on the other; in other words, at what might be called the attached portion of the growth, which is the most recent in origin. Here the growth is better nourished, as lying nearer the uterine circulation, and is consequently more typical.

There is, however, between this area and the muscularis no marked line of demarcation, for the columns previously described run in between the muscle-fibres, as do also the free isolated epithelioid cells and the fibrinous masses, so that the more superficial muscular strands present muscle-cells which are atrophied by pressure and degenerated, and which intermingle with the cells of the growth now as narrow spindles and now as granular oval cells, whose protoplasm stains but feebly if at all with hæmatoxylin. Deeper in the substance of the muscular wall the cells of the latter gradually assume a more normal appearance; the bands of new growth disappear, the discrete polymorphonuclear cells are less numerous, and instead of single muscle-cells muscular bundles are met with. Here, too, another phenomenon appears in the shape of an extensive infiltration of small round-cells, which is so dense in parts as to obscure all other structures from view. If a hæmorrhage occurs in this neighbourhood it is also densely invaded by leucocytes. Still deeper in the uterine wall large venous spaces, with distinct but perhaps imperfect walls, are seen; these are filled with red discs in a good state of preservation for the most part, and amongst the blood-cells appear the epithelioid cells with their large deeply stained nuclei, doubtless on their way to form metastases in the selective

viscera. The arrangement of the plasmodial cells in the neighbourhood of hæmorrhages is sometimes suggestive of the formation of a villus (*vide* drawing A),—that is to say, one finds now and again a circular or oval clear space, walled in more or less completely by syncytium, from which uninuclear cells proceed; there are, however, no vessels or stroma within such spaces, and the resemblance to a villus lies wholly in the shape and in the limiting plasmodial band. But cells within hæmorrhages are so modified in shape and size by imbibition of fluids that it is not an easy matter to settle clearly their histogenesis. I am therefore inclined to regard such a structure as accidental, and I should like to add, in passing, that the discovery of a typical villus within the elements of the uterine growth now under discussion is not at all essential to the acceptance of the view that it has its origin in the fœtal or chorionic portion of a previously shed placenta. To expect a morbid growth to reproduce the minute anatomy of the structure from which it arose in every detail is unreasonable. If, in examining a tumour of the breast, we find alveolar spaces full of glandular spheroidal cells, confined within the limiting basement membrane, we accept this as an imperfect mimicry of glandular tissue, and make the diagnosis of adenoma—a diagnosis at which we should never be able to arrive if we waited until we found perfect acini reproduced.

To return to the microscope. The pulmonary metastases will now be considered. Here one finds at the outset that the part which promised macroscopically to yield the best results, namely, the pale homogeneous centre of a button of growth, is, in fact, made up of degenerate hæmorrhagic and cellular *débris*. Coming, however, to the periphery of the growth, columns of large cells and vacuolated protoplasm are found, the cells resembling the large clear cells of the second layer of a villus wall (Langhan'sche Zellschicht). In my sections these cells are far better seen in the pulmonary growths than in the primary focus. Intermingled with these cells are particles

of carbon, often in large amount. The enlarged lymphatic glands show signs of chronic and recent inflammation, but they contain no evidences of new growth.

Nomenclature.

I have called this specimen a chorio-epithelioma for the following reasons :

The multinucleated protoplasm, arranged now in bands and now in masses, is similar in microscopic structure to the elements found in the walls of a chorionic villus. A villus wall, it will be remembered, is composed of a superficial layer of undifferentiated nucleated protoplasm and of a deeper layer of large epithelial cells called Langhans' layer. Of the histogenesis of the latter no doubt is expressed—it is of fœtal origin. As to whether the outer layer is maternal or fœtal authorities differ. For my purpose it is sufficient to accept the latest theory—an acceptance shared by Dr. Eden, van der Hoeven, Cullen, and others,—to regard it as fœtal epiblast, and to use for it the term syncytium (since it bounds a hollow space). Now the plasmodial tissue seen in the growth, being identical in character with the syncytium of a villus, may be termed syncytial masses, and in order to afford proof of this identity sections have been made of three placentæ which have undergone hydatidiform degeneration. In these one sees what may be regarded as the starting-point of epithelial new growth from the syncytium of the villi. Under the microscopes on the table are to be seen the vesicular villi, with buds and masses of protoplasm proceeding from the syncytium, pushing in a malignant manner through that loose fibrinous layer which intervenes between the syncytium and the decidual cells of the mother (Nitabuch's layer) towards the maternal tissues. How far this trespassing has taken place into the placenta may be seen in the sections—quite far enough to pronounce the process as incipient malignancy, and to justify the belief that under given conditions it may proceed

beyond the placenta into the uterine wall, and from thence by the blood-stream to other organs.*

There is, moreover, a proliferation of the cells of Langhans' layer seen better in some of the villi than in others. Now the only point of distinction between the overgrowth which one finds in a vesicular mole and a typical bit of a chorio-epithelioma is that in the former the villi from which the overgrowth proceeded are unmistakably present, whereas in the chorio-epithelioma, at least in my case, they are not. Although the *fons et origo* lacks demonstration in the latter, the new growth is identical in microscopical characters in each case. Since, then, we have a new growth, the elements of which are so identical with the two layers of a chorionic villus as to form an exact reproduction of it, it seems quite logical to regard the growth as arising in such a situation; the villus may never itself trespass beyond the placental domain, but its syncytial outgrowths do.

Before Mr. Doran sent me this specimen to examine I had seen two other cases of deciduoma malignum at the Samaritan Hospital. The clinical features in all three were similar. As Mr. Corrie Keep intends to bring forward these cases, I will not forestall what he has to say, but a point of importance is brought out by comparing the sections of Mr. Keep's two cases with the one I have had the pleasure of working at. In the former two cases the new growths are very similar; they are both made up of large modified connective-tissue cells like those found in a normal decidual membrane or in the maternal part of the placenta. No syncytium can be found on most careful examination, and both cases appear to me to be examples of a condition first described by Sänger as *sarcoma*

* Since writing this paper I have had an opportunity of demonstrating the fact that syncytial masses are capable of proceeding from a vesicular mole, not only through the placenta but into the substance of the uterine muscle. The sections proving this point are taken from a uterus removed within a few weeks of the delivery of a hydatidiform mole. I refrain from saying more about this case, as it will shortly be brought before the notice of this Society by one of my colleagues.

deciduo-cellulare, the origin of which is considered to be the maternal decidual cells.

This marked difference in the microscopic features may be in great part the cause of the prevalent diversity of views as to the real nature of these extremely malignant uterine growths. Those observers who claim for the growth a mesoblastic origin may have worked solely with growths like Mr. Keep's two cases. The supporters of the theory of an epiblastic origin may have studied only growths like the one before us to-night. However that may be, I would point out that two varieties of tumour, histologically very distinct, are passing under the collective designation of deciduoma malignum, and that whilst this nomenclature may be convenient for compilers of indices, pathologists should draw a sharp distinction between the chorio-epithelioma or syncytial carcinoma on the one hand, and the mesoblastic sarcoma of the decidua on the other, although no clinical distinctions such as a history of a previous hydatidiform degeneration is obtainable. The malignant sequela of the vesicular mole is invariably a syncytioma.

The PRESIDENT remarked that at the present time it was quite impossible to prove definitely whether these malignant growths were of maternal or of fœtal origin. Even if it could be shown that they were developed from the outer epithelial layer of the villi of the chorion, that would not settle the question, simply because it was still disputed whether that layer was maternal or fœtal. It was for this reason that he had named his own specimen, shown at this Society some months ago, deciduoma malignum, the name given by Sänger, who first described it. Of course Dr. Lockyer had as much right to call it chorio-epithelioma, but at the same time it might be more convenient to continue the original name until more was known. He could not help leaning to the view that it was fœtal in origin, and he did not see how those who believed in its maternal origin could get over the fact that it so often followed upon hydatidiform mole. The point raised by Dr. Lockyer that there were two sorts, one without syncytial elements, probably maternal in origin, and to which the term deciduoma malignum would be appropriate, and one with syncytial elements of fœtal origin, for which the term chorio-epithelioma would be better applied,

was no doubt very important, but it had to be proved. Could, for instance, Dr. Lockyer say that in all cases of this malignant growth which had followed vesicular mole there had been syncytial elements? In every instance of this malignant growth it was very desirable to thoroughly investigate the question of a recent pregnancy, miscarriage, or parturition. In his own case this had been very difficult to ascertain, and, indeed, although the patient was sent into hospital to have the supposed remains of a miscarriage cleared away, yet it had been found impossible to prove that she had had or had not had a miscarriage at the time alleged. She was forty-eight years of age, and had had a child two or three years previously. The growth was typical, and contained syncytial elements.

Mr. Alban Doran stated that when the patient was admitted into his wards she was too ill for any operation. At first sight sloughing fibroid seemed probable, but on further examination extensive malignant disease was evident. It was remarkable that she lived so long. Dr. Lockyer was to be congratulated for his excellent report of the pathology of this case. Many similar cases must have been overlooked or misinterpreted.

Dr. Herbert Spencer said that while he agreed with the main views of the author, he thought it would, for the present, be better to use the term deciduoma malignum until we knew a little more about the pathogenesis of the disease. There was no doubt that two distinct classes of growth had been described under this name; but Klebs, who was, he thought, the first pathologist to investigate the disease, had hesitated whether to describe it as a cancer or a sarcoma; and the late Dr. Kanthack had stated his decided opinion that his (Dr. Spencer's) case, which showed large masses of typical syncytium, was a sarcoma. He thought, therefore, it was a little premature to style it a chorio-epithelioma, though personally he was inclined to regard the syncytial growth as of that nature.

Dr. Lockyer stated that the patient's history afforded no proof of a period of amenorrhœa prior to the onset of hæmorrhage. The latter began suddenly in June, 1900, and continued until admission in November, 1900. In reply to a further question as to whether the uterine growth represented the fœtal or maternal structures of the placenta, he stated that the syncytial masses were of chorionic origin, and if the recent view that a chorionic villus is entirely composed of fœtal tissue be correct, it follows that any neoplasm arising therefrom must likewise be of fœtal origin. In reply to Dr. Spencer, Dr. Lockyer stated that he had adopted the nomenclature of chorio-epithelioma for his specimen after accepting the view that the syncytial envelope of a chorionic villus is an epiblastic fœtal structure. The term syncytial carcinoma would be equally applicable in the case of these new growths.

ANNUAL MEETING.

FEBRUARY 5TH, 1902.

PETER HORROCKS, M.D., President, in the Chair.

Present—45 Fellows and 2 visitors.

Books were presented by the Radcliffe Librarian and the Medical Society.

Edward James Ambrose Haynes, F.R.C.S.I. (Perth, Western Australia), was declared admitted.

The following gentlemen were proposed for election :— Henry J. F. Simson, M.B., F.R.C.S.Ed ; Evan James Trevor Jones, M.D.Brux., L.R.C.P.Lond. ; John Tennant, M.A., M.B., C.M.Edin. ; H. Simpson Newland, M.B.Adelaide, F.R.C.S.Eng.

DERMOID CYST OF OVARY REMOVED BY POSTERIOR COLPOTOMY.

Shown by AMAND ROUTH, M.D.

THE patient was a multipara aged 53, who had been treated by Dr. Booth, of New Cleethorpes, Grimsby, for metrorrhagia of eight months' standing. Dr. Booth sent

her to Dr. Routh with special reference to a pelvic tumour. It seemed to Dr. Routh that the semi-solid pelvic tumour was an ovarian cyst the size of a cocoa-nut (3·25 inches in diameter), and that it could be removed *per vaginam;* and, whilst prepared to operate by the abdomen, he decided to operate by the vaginal route if found practicable.

This proved to be the case, and he removed it on January 9th last *per vaginam*, with Dr. Eden's assistance, no difficulty being experienced during the operation. The convalescence, except an attack of heart failure in the second week, was uneventful.

Dr. Routh showed the specimen mainly to ask Fellows present how they dealt with the vaginal incision after the removal of such a tumour. After opening a pelvic abscess, a pyosalpinx, or a pelvic hæmatocele, drainage by means of an india-rubber tube stitched to the vaginal wound was advisable, but in these cases three other methods were advocated. One was to leave a long ligature on the broad ligament, as after vaginal hysterectomy for cancer. This method he had discarded. The other two methods were—after cutting the ligature short, as in abdominal ovariotomy, either to completely close the vaginal incision by continuous sutures, or to leave a small piece of gauze in the pelvis to drain through a corner of the vaginal incision. He thought the latter safer, but had closed the wound completely several times without trouble arising. After both methods of treating the vagina he had noticed in a few cases, in the second week, a painless swelling, sometimes of a considerable size, in the region of the broad ligament ligature, apparently of the nature of a parametric phlegmon, accompanied for some days by two or three degrees of pyrexia, but invariably terminating by complete resolution.

The PRESIDENT said that although Dr. Routh had not entered into the question, yet it might be questioned whether posterior colpotomy was as good as abdominal section for the removal of tumours in general, and dermoids in particular. It

was true that it might be an easy matter to remove a dermoid through the vaginal roof, but one could never tell beforehand that it would be easy; and if the abdomen had to be opened to complete the operation after the cyst had been opened from below, there would be increased risk of soiling the peritoneum with the dermoid contents, and it had struck him sometimes that the contents of a dermoid were occasionally more virulent than the contents of ordinary ovarian tumours. Bacteriological investigations, however, had not resulted in the discovery of any specific or specially pathogenic microbe. He preferred after a posterior colpotomy not to close the opening in the peritoneal cavity, but to drain with sterilised gauze; if the opening were very large it might be partially closed by a stitch, or, better still, by forceps.

Dr. F. H. Champneys thought that the treatment of the vaginal wound should depend upon its size. If large it should be partially closed, and a gauze drain put through the remainder; if small no suture was necessary. He now treated the pedicles of cysts removed by colpotomy by pressure forceps and gauze drainage, without ligature, and found the results very satisfactory, the forceps (left on for 36 to 48 hours) assisting drainage.

Dr. Herman thought that the special danger attending the fouling of the peritoneum with the contents of dermoid cysts was due to the proneness of dermoids to suppuration. The contents of dermoids that had not suppurated were but slight irritants to the peritoneum. If a dermoid had not suppurated, its contents had not fouled the peritoneum, and its pedicle had been securely tied, he could see no necessity for drainage, but would cut the ligature short and close the peritoneal cavity.

Dr. Routh said, in reply, that he preferred not to use a clamp for the pedicle, but to draw the cyst outside the vulva, retroverting the uterus during that procedure, and then to ligature the pedicle at leisure, all tension of the tissues being thus easily avoided.

UTERUS REMOVED AT EIGHT AND A HALF MONTHS OF GESTATION BY ABDOMINAL HYSTERECTOMY FOR FIBROID OBSTRUCTING LABOUR.

Shown by Amand Routh, M.D.

The patient, Mrs. M. P—, had been married fifteen months, and was sent into Chandos Ward, Charing Cross Hospital, by Dr. Eden, who, in the out-patient department, had diagnosed a five months' pregnancy with intra-pelvic fibroids.

When admitted, the five months uterus was a hand's breadth above the umbilicus, and a fibroid nodule was felt in the left iliac fossa.

Per vaginam the sacral hollow and right side of pelvis were found to be filled with a hard irregular tumour, and the cervix could only just be reached high up and to the left, behind the pubic symphysis.

Efforts were made to push up this retro-uterine mass under ether, and some success was obtained, and it is evident now that the fibro-cystic tumour growing on the right side of the uterus was then elevated, but the retro-uterine tumour could only be pushed up a little way, and gave the impression that it was a retro-peritoneal fibroid growing from the supra-vaginal cervix.

The patient saw Dr. Routh at intervals, and was finally admitted on January 20th last when, for the first time, the fœtal heart was heard. Finding that the fibroid still narrowed the obstetric diameter to about 1½ inches, it was decided, after consultation with Dr. Eden, to operate on January 31st, ten days before labour was due.

On that day, assisted by Dr. Eden, Mr. Bellamy Gardner producing anæsthesia, Dr. Routh operated.

He incised the uterus in the mid-line, cutting through the edge of the placenta, and extricated the child, which

presented by the shoulder, by podalic version. The obstetric assistant, Mr. Hammond, took charge of the child, a vigorous female.

An elastic ligature was then placed round the cervix, as bleeding was free. The ovarian arteries, Fallopian tubes, and ovarian ligaments were then tied, and divided on the uterine side of each ovary. Both ovaries were retained. The round ligaments were similarly treated, and the peritoneum was incised from one broad ligament to the other along the front of the uterus, and stripped off downwards. The retro-uterine fibroid at this stage felt as if it were covered in by peritoneum, but after removing the elastic ligature and stripping off more peritoneum it was found easy to pass the fingers below it from the right side. It was then found to be bound down by numerous fibrous adhesions to the floor of the pelvis, and by more recent ones at the brim of the pelvis. When these were separated the fibroid was easily elevated. The uterine arteries were then tied low down on each side, and the cervix cut through three quarters of an inch above. There were no bleeding points, and the operation was completed by covering in the exposed surfaces of the broad ligament and the uterine stump by the available peritoneal flaps.

The child was delivered in nine minutes, the uterus was removed in another twenty, and the operation was completed in sixty-five minutes.

Both mother and child are convalescent, the highest maternal temperature having been so far (a week) 99·5° on second day.

The following is a report of the specimen, kindly furnished by Dr. Cuthbert Lockyer, Obstetric Registrar, Charing Cross Hospital:

Dr. Cuthbert Lockyer's Report.

The tumours attached to the uterus are six in number, four pedunculated subperitoneal, and two interstitial

fibroids. Three tumours lay on the right side of the uterus, one posteriorly, one anteriorly, and one on the left side. Of the three right-sided tumours one is felt in the substance of the uterine wall at the right cornu; this is completely interstitial, the other two are pedunculated subperitoneal growths; the larger of these is attached by a thin pedicle to the side of the uterus, two inches below the right cornu; it has the size and shape of a goose's egg, and presents a cyst at its extremity; upon section it is soft in the centre. The third fibroid on the right side is small, and lies quite close to the cornu.

The posterior tumour arises by a pedicle low down on the peritoneal surface; it was adherent to the pelvic floor by old and recent adhesions, it is covered by peritoneum, its surface is nodular, and shows the fibrous tags of torn adhesions. In circumference it measures 10 inches, its length from pedicle to summit is 4 inches. The circumference of the pedicle measures 4½ inches. It presents a myxomatous, spongy surface on section.

The anterior fibroid is a small interstitial nodule, seen at the bottom of the Cæsarean incision.

The left growth is the size of a pigeon's egg; it lies deep in the lower uterine segment at the level of the amputation; it is situated 1½ inches from the canal of the uterus.

Remarks by Dr. Routh.

The case resembles another described by Dr. Routh at a meeting of the Society in July, 1900 ('Trans. Obstet. Soc.,' vol. xlii, p. 244). There was no alternative to hysterectomy in this case, for with an available diameter of 1¼ inches, and an irreducible obstructing fibroid, emptying the uterus at any date after the fifth month when first seen was impossible *per vias naturales*.

Dr. Champneys said that the position of the fibroid behind the cervix would have rendered birth *per vias naturales* very

difficult, even after destroying the child. The position of the tumour also was very important (if in front it was pulled or could be pushed up, if behind it was pushed down during labour). He therefore thought Dr. Routh's treatment correct.

ON A CASE OF TUBAL PREGNANCY DIAGNOSED BEFORE RUPTURE, AND A CASE OF TUBAL ABORTION.

By J. Bland-Sutton, F.R.C.S.

The patient was the wife of a doctor, and as she had missed a menstrual period, pregnancy was suspected. At the end of three weeks she experienced severe pains in the pelvis, and this led to an examination and the detection of a swelling on the right side of the uterus. Tubal pregnancy was then suspected. A month later I saw the patient, confirmed the diagnosis, and removed the gravid tube. The specimen was shown at the Society because it had attained a larger size than usual without causing the tube to burst. The cœlomic ostium of the tube was completely closed. The inordinate size of the mole depended on the unusual bigness of the amniotic cavity. This cavity contained a misshapen embryo.

On a previous occasion I mentioned to the Society a case in which an artisan applied to have his wife admitted into the New Hospital for Women for an acute abdominal lesion, which he believed to be due to an extra-uterine pregnancy. He made this diagnosis after reading the account of tubal pregnancy in my book 'On Diseases of the Ovaries and Fallopian Tubes.' The case eventually proved to be a combined intra- and extra-uterine pregnancy. The gravid tube was removed by cœliotomy, and the uterine pregnancy went successfully to term.

The details of the case now to be related are even more remarkable.

A patient aged 36 was confined of a girl in 1891. Menstruation continued regularly for eleven years, and on July 5th, 1901, it was missed, and she realised that pregnancy had occurred, and though the patient felt certain that she had conceived, nevertheless she felt convinced that the pregnancy was extra-uterine. When the menstruation was four days overdue she took a cycle ride, and on the journey became suddenly seized with acute abdominal pain, and had to rest by the wayside. The patient (an extremely intelligent woman, who took great interest in medical matters, and had access to my book 'On Diseases of the Ovaries and Tubes') was now more than ever convinced that her pregnancy was tubal. On July 11th another short cycle ride gave rise to pelvic pain and led to a consultation. After an examination under an anæsthetic I confirmed the diagnosis, and on July 19th, the menstruation being then fourteen days overdue, I removed the left Fallopian tube and ovary. There were several ounces of fluid blood in the recto-vaginal pouch. The ampulla of the tube contained a clot as large as a walnut, but its cœlomic ostium, though contracted, was yet large enough to admit a goose-quill, and from this unclosed ostium bright blood leaked freely at the time of the operation. The clot in the tube was due to retained blood, and the walls of the tube in its neighbourhood were extremely thin. The mole was not found. As the pregnancy could not be older than twenty-nine days, and was probably much less, its non-detection was not a matter for surprise. The placental site was carefully examined microscopically, and a few typical villi detected.

The PRESIDENT thought that the explanation of the first specimen being so large without having ruptured was due to the fact that the embryo had perished early, and there had been slow hæmorrhage, with formation of and partial organisation of clot. With regard to the second specimen, he called attention to the ease with which a tubal gestation might be ruptured during examination or during straining by the patient, and gave details of an unsuspected case that had proved fatal in this way.

Dr. Herman pointed out that in the large tubal mole exhibited by Mr. Bland Sutton the clot was in different parts of different degrees of decolorisation. This indicated, he thought, different hæmorrhages at different dates. He asked if the patient had had successive attacks of pain. He had himself observed rapid increase in size in a tubal swelling, which on operative removal proved to be a tubal mole. In a condition of tube such as Mr. Bland-Sutton's specimen illustrated, the thick layers of fibrin which lined the tube would help to save it from rupture. The patient possessing such a tube was in danger of bleeding from its open end and from suppuration of the tube, and if neither of these occurred the patient would suffer long from pelvic pain. For these reasons it was well to remove such a tube. But there was not risk of great intra-peritoneal hæmorrhage from rupture of such a tube.

Dr. Cuthbert Lockyer said he thought the most noteworthy point in Mr. Bland-Sutton's specimen of tubal mole was the large size of the amniotic cavity; he had examined many entire specimens of ectopic moles before rupture, but had never found such a large amniotic space. In one specimen in his possession, which was larger than Mr. Sutton's, the cavity was indicated by an elongated cleft, from which projected an elongated flattened body, presumably the crushed fœtus. Dr. Lockyer asked Mr. Sutton if he had ever seen a similar specimen to the one he was showing.

Dr. Amand Routh asked why the amniotic cavity in tubal moles should be so much smaller than in uterine moles of the same date. He also asked if any Fellow had heard of a "hydatidiform" mole of the tube.

Mr. Bland-Sutton, in reply, said he had for many years kept a sharp look-out for a hydatidiform mole in tubal pregnancy; there were no reasons why it should not occur, and he felt sure that in time such a condition would come to hand. Hydatidiform moles in the uterus were rare in proportion to other forms of abnormal pregnancy, and though tubal pregnancies were common, yet they had not reached the total number in comparison with normal pregnancies to yield even one hydatidiform or myxomatous chorion. The President's remarks were of great practical interest, and Mr. Bland-Sutton had always so thoroughly realised the thinness of the walls of a gravid tube that when a patient came into the wards with a suspected tubal pregnancy he always took care that the dressers did not examine the patient. It was quite true what had been mentioned by Drs. Lockyer and Amand Routh, that a uterine mole had a large amniotic cavity and thin walls, whereas tubal moles had usually thick walls and a small amniotic cavity; he could endorse the statement of fact but could not explain it.

Annual Meeting.

The audited Report of the Treasurer (Dr. F. H. Champneys) was read.

On the motion of Dr. Walter Rigden, seconded by Dr. H. Russell Andrews, the Report of the Treasurer, Dr. F. H. Champneys, was received and adopted.

Report of the Honorary Librarian.

The high state of efficiency of the library has been well maintained during the year which is past, and the increasing number of Fellows who have made use of the periodicals and standard works is evidence of their appreciation.

The library now contains 5672 volumes, of which 129 have been added during 1901.

The difficulty of finding space for the rapidly increasing number of books has been overcome for the time by the great reduction which has been effected in the reserve stock of 'Transactions,' the Committee having decided that fewer copies should be printed and fewer retained on the premises.

By an arrangement with the Royal Medical and Chirurgical Society additional shelves have been arranged, which are calculated to accommodate another 500 volumes.

Before long, however, it may be advisable to still further increase our space for new and valuable works by sorting out some of the old and obsolete text-books which still crowd our shelves.

February 5th, 1902. M. Handfield-Jones.

The Report of the Hon. Librarian, Dr. M. Handfield-Jones, was received, and its adoption was moved by Dr. G. F. Macker, seconded by Mr. C. A. Goullet, and carried.

OBSTETRICAL SOCIETY OF LONDON.

Abstract of Receipts and Payments for the year ending December 31st, 1901.

1901.	RECEIPTS.	£	s.	d.
To balance from 1900 . .	£276 7 10			
On Deposit . . .	300 0 0			
		576	7	10
„ (1) 489 ANNUAL SUBSCRIPTIONS, realising .		513	9	4
„ (2) COMPOSITION FEES . . .		40	19	0
„ (3) MIDWIVES' EXAMINATION FEES . .		1045	16	0
„ (4) SALE OF 'TRANSACTIONS'				
(Longmans) . .	£67 15 2			
Do. do. (Society) .	3 0 0			
Do. Midwives' Questions .	0 14 0			
Do. Midwives' Regulations and Infant Rules . .	0 1 7			
		71	10	9
„ (5) INTEREST on Debentures .	80 7 9			
Ditto on Deposit .	11 4 1			
Ditto on Consols .	3 17 9			
		95		7

Audited and approved,

TOM MUNDY, F.C.A.

F. H. CHAMPNEYS, *Treasurer.*

January 29th, 1902.

£2343 12 6

1901.	PAYMENTS.	£	s.	d.
By (1) 'TRANSACTIONS,' Vol. XLII. Printing, Paper, Binding, Delivery, and Illustrations		286	4	9
„ (2) LIBRARY:				
Books purchased . .	£27 15 7			
Binding . . .	16 3 3			
		43	18	10
„ (3) MUSEUM AND LIBRARY:				
Rent . . .	200 0 0			
Librarian's Salary .	160 0 0			
Repairs to Furniture, Cleaning, Coals, Lighting, etc. . .	33 8 3			
		393	8	3
„ (4) EXPENSES OF MEETINGS . .		26	9	7
„ (5) STATIONERY, STAMPS, AND PRINTING .		12	2	9
„ (6) EXAMINATION OF MIDWIVES:				
Fees paid to Examiners .	473 1 0			
General Expenses .	167 9 10			
		640	10	10
„ (7) ACCOUNTANT'S FEE .		3	3	0
„ (8) PURCHASE OF £600 CONSOLS . .		559	11	0
„ (9) BANKING EXPENSES and Cheque-book .		0	11	11
„ BALANCE		347	11	7
		£2343	12	6

Report of the Chairman of the Board for the Examination of Midwives.

I have the honour to report that during the past year there were 980 candidates for the Certificate of the Society. Of these 769 passed, 195 failed, and 16 were absent from the examination.

The total number on the Register is now 6527.

The examination last month (January, 1902) was the largest yet held. There were 294 candidates, of whom 229 passed, 58 failed, and 7 were absent.

Since the last report was made a small modification has been introduced into the Rules for the admission of candidates to the examination. The alteration is intended to, and will, it is believed, ensure as far as practicable that proposing candidates have had personal responsibility in the cases they are certified as having attended during labour and the lying-in period.

A note relating to the designation to be used after the name of a holder of the Society's Certificate is added to the Rules. It is as follows:

N.B.—Successful candidates are entitled to use the designation "Certificated by the Obstetrical Society of London," or, in short, "Certif. Obst. Soc. Lond." No other designation and no further abbreviation of these words are authorised.

W. R. Dakin.

The Report of the Chairman of the Board for the Examination of Midwives was adopted on the motion of Dr. Thomas Stevens, seconded by Dr. Cuthbert Lockyer.

Dr. Galton said that he was glad to have the opportunity of proposing the change in the Bye-laws admitting women to the Society, as he had twenty years ago proposed the retention of the then Bye-laws. On that

occasion he had only six votes in favour of their admission, but he hoped for a very different result now. Since then much water had gone under the bridge, and opinions had changed greatly upon the subject. Fifteen years ago he had proposed at Nottingham the admission of women to the British Medical Association, and both at the Obstetrical Section at the General Meetings and at the Convocation of the London University ladies had shown themselves capable and useful members. He would only mention one of the many arguments in favour of the proposal, and that was that every one who had suffered from any malady took greater interest in that malady, and mastered its symptoms and treatment, so that he became of more use in the subsequent treatment of the same disease in others. Was it possible, then, that the diseases of women should not more largely interest those subject to them, and on that account they would be more likely to fulfil the *raison d'être* of that Society—the advancement of the science and art of obstetrics? Could they logically persist in the exclusion of those so likely to further its aims? In fact, it was a wonder to him that they were men discussing the admission of women to the Obstetrical Society, and not a meeting of women discussing the admission of men. He had been proud, as a member of the Society, of the manner in which the Council had persisted, in face of much obloquy and misrepresentation, in their efforts to improve the training of midwife nurses, and no one who had not attended general meetings of the profession, especially in the North, had any idea of the ill-feeling which the action of this Society had stirred among many of the profession. However, the action of the Council had been the means of increasing the reputation of the Society among the general public, and he was quite sure that the removal of an injustice such as these Bye-laws inflicted would further enhance that reputation, and add to the utility of the Society by admitting as members a patient, hard-working, and estimable class of practitioners.

The following alterations in the Laws were carried :

(*Present Laws.*)	(*Proposed Laws.*)
CHAP. I, § 3.—All Medical *Men*, possessing a qualification registrable in the United Kingdom, shall be eligible for election as Ordinary Fellows of the Society.	CHAP. I, § 3.—All Medical Practitioners, possessing a qualification registrable in the United Kingdom, shall be eligible for election as ordinary Fellows of the Society.
CHAP. IX, § 5.—The President or a Vice-President, one Secretary, and three Fellows of the Society, nominated by the President at some meeting of the Society previous to the Annual Meeting, shall audit the accounts of the Treasurer. Three shall form a quorum.	CHAP. IX, § 5.—To be left out as a professional auditor has been appointed.
CHAP. XVI, § 7.—All papers read before the Society shall be considered the property of the Society. If published elsewhere they shall not appear in the 'Transactions.' Papers rejected for the 'Transactions' shall be returned to the authors, and shall no longer be considered the property of the Society.	CHAP. XVI, § 7.—All papers read before the Society shall be considered the property of the Society ; but authors of papers accepted for reading before the Society are at liberty to publish them in any scientific periodical after they have been read, provided that acknowledgment of the fact of their having been read before the Society is made in such other periodical.

The following gentlemen were declared elected to serve on the Council of the Society for the Session 1901—1902 :

President.—Peter Horrocks, M.D.

Vice-Presidents.—John W. Byers, M.A., M.D. (Belfast) ; Edward Malins, M.D. (Birmingham) ; John Phillips, M.A., M.D. ; Herbert R. Spencer, M.D.

Treasurer.—Francis Henry Champneys, M.A., M.D.

Chairman of the Board for the Examination of Midwives.—W. R. Dakin, M.D.

Honorary Secretaries.—Amand Routh, M.D. ; Montagu Handfield-Jones, M.D.

Honorary Librarian.—Robert Boxall, M.D.

Other Members of Council.—Comyns Berkeley, M.B., B.C. ; Henry Briggs, M.B. (Liverpool) ; Thomas Vincent Dickinson, M.D. ; Charles Owen Fowler, M.D. ; Charles Arthur Goullet ; Walter Spencer Anderson Griffith, M.D. ;

David Berry Hart, M.D. (Edinburgh); Arthur Corrie Keep, M.D., C.M.Edin.; Arthur H. N. Lewers, M.D.; Thomas Robert Lombe, M.D. (Torquay); William Rivers Pollock, M.B., B.C.; Harry Campbell Pope, M.D.; Edward Reynolds Ray; William Loudon Reid, M.D. (Glasgow); William Japp Sinclair, M.D. (Manchester); Thomas George Stevens, M.D.; Francis T. Tayler, M.B.; John William Taylor, F.R.C.S. (Birmingham).

Dr. John Galton proposed, and Dr. Drummond Robinson seconded, a vote of thanks to the retiring Vice-President, Dr. Dakin, and to the other retiring members of Council, Mr. C. E. Adams, Dr. Barbour, Dr. Blacker, Dr. Boxall, Dr. Champneys, Dr. Gow, Dr. Herman, Dr. Stabb, and Dr. G. P. White.

Dr. F. H. Champneys moved, and Dr. W. H. Tate seconded, a vote of thanks to the retiring Hon. Secretary, Dr. Herbert Spencer, and the Hon. Librarian, Dr. M. Handfield-Jones, and Dr. Spencer briefly replied.

The President then delivered the Annual Address.

ANNUAL ADDRESS.

Gentlemen,—At a recent meeting of the Council it was suggested that it might be an improvement if, instead of the President giving a *résumé* of the work done during the past twelve months, he confined himself to a few remarks, in addition to any obituary notices required, so that the rest of the evening might be spent in the usual happy way, namely, by the reading of and subsequent discussion on a paper. Lord Rosebery said some time ago that the sermon that was too short had yet to be written, but it was my intention to make an attempt to accomplish this object in regard to annual addresses; but from that peaceful state of rest I was rudely awakened by your ever alert senior secretary, who informed me there was no paper for the February meeting, and would I therefore give a full address?

It is for this reason, therefore, that I must solicit your patient hearing, whilst on my part I promise to make my remarks as little tedious as possible.

In the first place you will be interested to know that during the past twelve months we have lost 6 Fellows by death and 29 by resignation, but 24 new Fellows have been elected. The number of Honorary Fellows remains the same, namely, 14. Hence our total number has fallen from 665 to 654.

It is only by filling up the ranks that we can hope to maintain the high position we now hold, and it behoves every Fellow to assist in getting others to join us. Any practitioner who wishes to keep abreast of the times in midwifery and diseases of women could not do better than join our Society, and attend its meetings regularly. He would see the specimens shown, hear the papers read,

and listen to the discussions, and, perhaps, join in them or show a specimen himself, or read a paper. The fact that all the teachers in obstetrics at all the medical schools in London are Fellows guarantees that our work is of the highest standard, reflecting the latest opinions as to theory and the most modern methods in practice. If a practitioner living too far away, or too busy to attend the meetings, joined our Society, he would, at all events, obtain the 'Transactions,' which contain full reports of both specimens and papers, with the discussions upon them, often accompanied by excellent illustrations. The reports of our 'Proceedings' which are published in the medical papers are of necessity greatly abbreviated, and so cannot compare with the carefully prepared and unabbreviated reports given in our 'Transactions.'

I do not know of any society in this country that possesses a finer library of obstetric literature, English and foreign, than ours. Hence I feel sure a practitioner could not spend a guinea a year more profitably than in becoming a Fellow of this Society.

The Report of the Honorary Treasurer shows that we are in a healthy financial condition.

The additions to our Library are well up to the average, as told you by the Honorary Librarian.

Consent has been given by the Council to the making of a lift by our landlords, which will fill up a recess leading out of our library. Our landlords have acted generously towards us for making this concession, one thing they give us in return being an increase in our library space. As time goes on, and books increase, this question of shelf room will become more pressing.

The Report of the Chairman of the Board for the Examination of Midwives shows how greatly our examination is valued by women who wish to work as midwives. It has been pointed out by my predecessors that this Society has no desire to continue this work. If a Midwives Bill can be passed in Parliament so that this work, which we believe to be beneficial to women who

are attended by midwives, can be taken up by others, we, as a Society, shall only be too glad to relinquish it, and to devote ourselves entirely to more purely scientific objects.

It is simply untrue to say that we do it for the money it brings in; if we did we should want to keep it, whereas, as you all know, we are desirous of passing it into other hands. Personally, and I feel I am expressing the sentiments of this Society, I have every sympathy with those medical practitioners who object to midwives posing or practising as qualified doctors. It is dangerous to the public and unfair to medical men. Efficient steps will, I hope, be taken to prevent this happening. It may be impossible to prevent it altogether, but surely it can be reduced to such small dimensions as to make no difference.

On the other hand, what we are striving for is to teach midwives the gospel of cleanliness, and to give those women who have passed a satisfactory examination, such as we believe ours to be, and which any examination instituted by the State will also be, some sort of stamp whereby the public may know who is and who is not legally competent to practise as a midwife.

I do not believe any Parliament in this country will try the impossible task of preventing any woman acting as a midwife whether she has passed any examination or not or whether she has had any experience or not. But the more widespread the knowledge of the doctrines and practice of asepsis is made, the more likely will women be attended by those who will do them no harm by the introduction of sepsis.

During the past twelve months your Council has been busy, especially in regard to questions which have arisen affecting our methods of procedure and the working of the Society.

I shall not weary you with minor points, but should like to call your attention to two most important changes which have been made at the instigation of the

Council. The first is the admission of women to the Fellowship.

When the Society was founded, it probably never entered into the minds of its promoters that a time would come when women would obtain entrance into the profession, and would in consequence apply to be admitted to the Fellowship of this and kindred societies. Hence they made a law which ran as follows:—"All medical practitioners, possessing a qualification registrable in the United Kingdom, shall be eligible for election as ordinary Fellows of the Society."

The medical profession strove strenuously to prevent the portals of examining boards being opened to women, but whether for good or for ill they were unsuccessful, and first one and then another door was opened, so that now, although all are not open, yet any woman who wishes to qualify has opportunities of doing so, and as you are well aware there is already a large number of women who are registered practitioners. Hence they became *ipso facto* eligible to become Fellows of this Society. The Council, however, met this by altering the law so that it reads all medical *men*, etc., instead of all medical practitioners, etc. In order that the word "men" should not be construed in a general sense to equal mankind and so include women, the word was printed in italics. The Council of that time no doubt felt the innovation of medical women very strongly, and hence their action. But time has wrought a great change in the attitude of the profession towards medical women, and the sense of fairness alone has compelled even the bitterest opponents to admit that it is not right, now that women have obtained the victory and have availed themselves of it so far as to go through the same course of study and to pass the same examinations as men, so as to become legally qualified and legally registered medical practitioners, to deny to them access to learned societies such as ours. Hence at a recent meeting of your Council it was proposed, seconded, and carried unanimously that the

law already referred to should be again altered, the word "men" being replaced by the word "practitioners" as it stood originally, in order that women should be included in those eligible for the Fellowship of our Society. This recommendation of the Council will, I hope, have been passed by the meeting to-night without any opposition. Whether women ought to be allowed to become legally qualified practitioners may be doubted, but we cannot, if we would, prevent it; it is an accomplished fact. But I confess I see no reason when once they are qualified why they should be shut out from societies such as ours. We are, or profess to be, a learned Society. Our object is the discovery of truth and the progress of our branch of science. The discovery of truth and science is not limited to one sex. Women are heavily handicapped by Nature, and we need not impose any artificial disabilities to hamper them further in the struggle.

Another innovation suggested quite recently by your Council has been to allow the author of a paper to publish it in any journal he likes after it has been read before the Society. This has been done because some Fellows did not wish to send in a valuable paper which would appear only in our 'Transactions,' when he preferred to have it printed in a much more widely read journal. This feeling has borne fruit in other societies, and we have followed their example. I trust this concession may result in a large addition to the number of papers sent in. Any paper accepted will be read and published as usual and will be considered to be the property of the Society, but the author of it can have it published as soon as he likes after it has been read, stating in such other publication that it was read at the Obstetrical Society of London. This recommendation of the Council will also, I hope, have received your approval to-night. The Council has also appointed a standing Pathological Committee, to which any specimen shown can be referred. The first Committee consists of Drs. and Messrs. Blacker, Doran (chairman), Eden, Fairbairn, Keep, Lockyer, Roberts, Smith, Spencer, and

Targett, with the President and Secretaries, *ex officio*. These names guarantee that any specimen so referred will be thoroughly and scientifically reported upon. It was, however, decided that your President should still have the power hitherto in his hands to refer any specimen to a Special Committee nominated by himself, such committee not necessarily including any of the standing Pathological Committee. It is hoped that in this way no specimen will be overlooked, and that it will be referred to the committee most competent to deal with it.

It is a matter for congratulation that during the first year of the twentieth century such radical changes have been made. It shows that we are not suffering from senile rigidity, unable to make alterations, but that we are able to adapt ourselves to different conditions and willing to progress with the times, and to make whatever changes may be thought desirable to promote the objects we have in view.

In reviewing the work done during the year 1901 there is no question that the quality and high standard already attained have been well kept up. It is curious that out of seven papers six were obstetric and only one gynæcological, whilst out of fifty specimens shown (excluding new instruments), thirty-four were gynæcological and only sixteen obstetric.

Fibroid Tumours.

As might have been expected, these very common tumours occupy a large proportion of papers and specimens.

Dr. Donald, of Manchester, read an interesting paper on "Fibroid Tumours complicating Pregnancy." He discussed the risks involved and came to the conclusion that in the majority of instances neither pregnancy nor labour were seriously influenced by these tumours, but that in a small proportion of cases the danger to mother and child was greatly increased. He summed up the risks during

pregnancy as follows :—(1) Rapid increase in the size of the tumour ; (2) incarceration of the tumour in the pelvis ; (3) serious pressure on the bladder ; (4) degeneration of the tumour through diminished nutrition ; (5) excessive rotation of the pregnant uterus ; and (6) abortion or premature labour.

He also pointed out that abortion or labour might be complicated by—(1) obstruction of the natural passages ; (2) malpresentation ; (3) retention of the placenta or membranes ; and (4) by extrusion of the tumour during labour, and that during the puerperium the presence of a fibroid rendered septic absorption more likely.

In discussing the treatment of these cases he dealt with those in which pregnancy was allowed to take its course until full term, or at all events viability, and secondly with those in which it was necessary to interfere in the earlier months.

In the great majority of cases he advocated leaving matters alone until full term, and to perform Cæsarean section if it was then found impossible to deliver *per vias naturales*.

In cases where interference was necessary in the earlier months, he thought that induction of abortion ought to be abandoned, that preliminary myomectomy should be done whenever possible, and that hysterectomy should be performed where myomectomy was impossible. After quoting several authorities he gave clinical details of six cases under his own care, all of which were successful as far as the mother was concerned.

An excellent discussion followed, most of the speakers agreeing in the main with Dr. Donald's conclusions.

Mr. Alban Doran and Dr. Cuthbert Lockyer read a paper on "Sloughing Fibroid of the Left Uterine Cornu with Abnormal Relations."

Mr. Doran removed from a single woman, aged 30, the uterus and tumour with the left appendages. The tumour was in a necrotic condition. The patient recovered. On dissection it was found that the fibroid had developed in

the left cornu of the uterus. The relations and the microscopical appearances of the tumour were carefully described, and references were given to similar tumours described by Doederlein, of Tübingen, and Cripps.

Dr. Herbert Spencer showed a large uterus with cervical fibroid, removed by abdominal hysterectomy by Doyen's method, the patient making a good recovery.

Dr. Walter Tate showed a fibroid of the uterus with cystic degeneration, removed from a woman aged 63, from whom both ovaries had been removed eleven years before. The patient did well.

Dr. Boxall showed a cystic fibroid with carcinoma of the left ovary and right Fallopian tube. His description is illustrated by some excellent drawings. A committee appointed to report on the specimen agreed with his description of the case.

Dr. William Duncan showed uterine fibroids removed by intra-peritoneal hysterectomy.

Dr. Herbert Spencer showed a cystic fibro-myoma of the uterus removed by posterior colpotomy. Internal hæmorrhage occurred after the operation, and the abdomen was opened and the bleeding stopped, the alarming condition of the patient necessitating injection of a large quantity of saline fluid into the cellular tissue below the breasts, besides some saline fluid being left in the peritoneal cavity. The patient recovered. A good discussion followed on the relative merits of colpotomy and abdominal section.

Dr. Stanley Boyd showed a suppurating fibroid of the uterus. It was converted practically into a cyst, and was diagnosed as an ovarian tumour. At the first operation it was opened and drained, but later it was removed, the uterus being removed with it. The patient made a good recovery.

Mr. Alban Doran showed a pregnant fibroid uterus removed at the fifth month. It is illustrated by an excellent plate. The patient made a good recovery.

Dr. Galabin showed a subperitoneal fibroid weighing

over 20 lbs., originating from the broad ligament. There was a larger proportion of fibrous tissue than in ordinary uterine fibroids. The cavity from which the tumour was enucleated was packed with gauze, and the patient ultimately recovered.

Dr. William Duncan showed a subperitoneal fibroid.

Dr. Andrews showed a fibroid of the ovary. It consisted largely of fibrous tissue, but contained some muscular fibres.

Mr. Alban Doran showed a fibroid of the broad ligament associated with an ovarian cyst; an excellent plate illustrates it, and a description of the microscopical appearance is given by Mr. Shattock. The patient made a good recovery, and albuminuria, which was present before the operation, disappeared.

Dr. Walter Tate showed a fibroid of the uterus, complicated with double salpingitis and carcinoma of the cervix. It was removed by a combined vaginal and abdominal operation, and the patient made a good recovery.

Cancer.

It would be a real delight to be able to announce that at last a remedy had been found for this dread disease; but amidst all the vaunted specifics not one has hitherto borne the test of repeated trial, and hence the records of cases show that they have been treated for the most part by excision.

Dr. Sanderson read a paper on "A Case of Combined Vaginal and Abdominal Hysterectomy for a Pregnancy of Four and a Half Months, complicated by Cancer of the Cervix."

The chief interest of the case lay in the method of removal, most of the speakers preferring to operate by the vaginal route alone, after emptying the pregnant uterus.

Dr. Herman showed a specimen of sarcoma of the stomach. It was thought to be either a uterine fibroid

or a solid ovarian tumour, but when removed by abdominal section it was found to be connected by a short pedicle with the greater curvature of the stomach in front of the omentum.

The patient made a good recovery.

Dr. Arnold Lea showed a sarcoma of the uterus, which was referred to a committee, whose report agreed with the description given by Dr. Lea.

Dr. William Duncan showed multiple myxomatous polypi from the cervix uteri.

I showed a specimen of deciduoma malignum removed by vaginal hysterectomy. The patient recovered, but hæmorrhage recurred a few months later, and proved fatal before she could be removed to the hospital. Unfortunately an autopsy could not be obtained.

The specimen was referred to a committee, who reported that it was a typical case showing the usual masses of syncytium, etc. They pointed out that it was impossible to say whether the patient had had a recent miscarriage or not. Excellent drawings, showing the naked eye and microscopical appearances, have been published.

The vexed question as to whether this form of cancer is of fœtal or maternal origin may some day be settled. At present we must go on collecting facts.

Dr. Fairbairn showed a carcinomatous tumour of the ovary removed successfully by abdominal section. It was encapsuled in ovarian tissue and about the size of the fœtal head.

Mr. Butler-Smythe showed a carcinomatous uterus removed eighteen and a half years subsequent to double ovariotomy, which is of great interest in connection with the question as to the utility of removal of the ovaries in inoperable cancer.

Dr. Galabin showed a sarcoma of the uterus which had been taken for an ordinary fibroid tumour. In the discussion doubt was thrown upon its nature, some thinking it was a fibro-myoma.

Dr. William Duncan also showed a sarcoma of the uterus, and Dr. Andrews showed a very rare specimen of primary melanotic sarcoma of the ovary which had been removed successfully by abdominal section.

Dr. Lewers showed a uterus with squamous epithelioma of the cervix, removed successfully in 1895, with no recurrence six years later.

Extra-uterine Gestation.

Messrs. Anning and Littlewood read a paper on a most interesting and almost unique case of "Primary Ovarian Pregnancy with Rupture fourteen days after the last Menstruation." Clinical details were given, and a description of the operation and microscopic sections were shown. There seems to be no doubt that it is a genuine case, ranking in importance with the one described by Dr. Catharine van Tussenbroek in the 'Annales de Gynecologie' in 1899.

In the case described by the authors the patient was 28 years of age, and had been married five months. Abdominal section was performed, and the right appendages and about a quart of blood were removed.

In the latter was found a flesh-pink-coloured impregnated ovum the size of a large pea. The Fallopian tube showed no flaw, and into a cavity in the ovary, lined in part with laminated clot, the ovum with its envelope exactly fitted. Sections of the cyst wall itself, taken from the ovarian side, showed the structure characteristic of a corpus luteum. Excellent drawings of this important specimen are published in the 'Transactions.'

Mr. Hastings Gilford showed a specimen of the left uterine appendages showing evidence of rupture of the sac in an ovarian pregnancy.

A committee was appointed to report upon this specimen, but unfortunately the specimen was lost.

At the February meeting last year the committee appointed to report on Dr. Croft's specimen, shown in

1900, gave it as their opinion, after very careful examination, that it was an example of primary ovarian gestation. These cases practically settle the question as to the possibility of ovarian gestation in the affirmative.

Dr. Fairbairn showed a tubal mole showing partial tubal abortion of the embryo.

Dr. Handley showed a tubal mole with encysted hæmatocele.

The most remarkable feature of this case was the displacement of the tube entirely forwards.

Dr. Amand Routh showed a tubal abortion with rupture of the tube, operated on successfully under difficult conditions.

Puerperal Eclampsia.

Dr. Groves read a paper on the "Pathology and Treatment of Puerperal Eclampsia," with special reference to the use of saline transfusion. Clinical details of two cases under the care of the author were given in detail, and they, together with forty-five others, were tabulated, showing a mortality of only 12·7 per cent.

The pathology of eclampsia was very fully gone into, and the various theories were discussed. The saline fluid was injected into the veins, five pints in one case and three and a half in the other. In both cases rapid improvement followed, and diuresis occurred thirteen hours after in one and within forty-eight hours in the other. Evidence of the toxic nature of eclampsia was adduced, and the author gave it as his opinion that the therapeutic action of saline solution was probably due to its hindering the formation of thrombi, and dissolving those just formed.

This paper resulted in an adjourned discussion, to join in which Dr. Jardine and Dr. Munro Kerr came specially from Glasgow. Although doubt was thrown on the idea that in saline transfusion a specific cure for this disease had been obtained, still the results of those who had tried it

were so good as to make it desirable to give it a fair trial.

Dr. Andrews showed microscopical sections of the kidneys in a case of puerperal eclampsia which proved fatal. The most marked changes were seen in the epithelium of the convoluted tubes where there was what seemed to be a running together of the cells. The patient had been treated with injections of morphia and atropine and an infusion of three pints of saline fluid, and later an injection of strychnine and caffeine.

Rupture of the Uterus.

Dr. Maxwell, Changpoo, Amoy, China, read a paper on "The Spontaneous Rupture of the Uterus in Placenta Prævia." The patient was a primipara aged 23, and the rupture took place posteriorly, resulting in alarming hæmorrhage. The uterus was packed with surgical gauze wrung out in biniodide of mercury lotion, and this gauze was removed in twenty-four hours. No douche was used, and the patient was up and about at the end of fourteen days.

Leukæmia and Pregnancy.

Dr. Herman read a paper on this rare condition, and he gave some conclusions derived from a study of his own and seven other cases, which were all he could find published. These eight cases agreed in the following points:

1. The presence of an enlarged spleen and liver caused patients with leukæmia to suffer more from the abdominal distension of pregnancy than healthy women.

2. The symptoms of leukæmia were aggravated during pregnancy.

3. In pregnancy with leukæmia there was a great tendency to miscarriage or premature labour.

4. Death sometimes quickly followed the termination of pregnancy.

5. If the patient survived the termination of pregnancy great improvement took place.

He advocated the induction of premature labour or miscarriage as a therapeutic measure only in cases in which the symptoms caused suffering and were aggravated after the onset of pregnancy.

Septicæmia and Peritonitis.

Dr. Lockyer showed two uteri removed after death from puerperal fever, and gave the report of a bacteriological investigation. From inoculations on guinea-pigs it was reported that the organism present in the vagina was the *Staphylococcus albus*.

Mr. Bland-Sutton read a short paper on a case of gonorrhœal pelvic peritonitis. Dr. Foulerton was able to make pure cultures of the *Micrococcus gonorrhœæ* from the parts removed by abdominal section.

Ovarian Tumours.

Mr. Doran showed a specimen of acute torsion of an ovarian pedicle with chronic torsion of a tumour of the opposite ovary. Both tumours were dermoids.

Dr. Munro Kerr showed a dermoid cyst of the ovary which had obstructed labour. Forceps were used and the tumour removed by abdominal section five weeks later.

Dr. Alcock showed a cystic corpus luteum.

Dr. Spencer showed an ovarian tumour which ruptured three days after labour. The patient, who had refused operation when the tumour was found, some two or three years before, died from syncope soon after the rupture.

Dr. Galabin showed a papillomatous cyst of an accessory ovary, and pointed out that the view that all papillary cysts of the ovary grew from the hilum of the ovary was probably incorrect, as in his case it appeared to have originated in the oöphoron proper.

Contracted Pelvis.

Dr. William Duncan showed a uterus at full term removed by intra-peritoneal hysterectomy on account of a contracted pelvis. The patient recovered. She was a dwarf, and the diagonal conjugate was only three inches. A discussion took place as to the relative merits of Cæsarean section and hysterectomy.

Uterine Casts.

Dr. Fothergill showed a decidual uterine cast expelled after eight weeks' amenorrhœa together with an ovum of five days' growth. He considered that it was a spurious abortion, as described by Dr. Eden, and that the so-called syncytium was a fœtal and not a maternal structure.

Dr. Lockyer showed a menstrual membrane and also two decidual membranes, one of the latter being still *in utero*. He regarded the menstrual membrane as an inflammatory product, and called it "endometritis exfoliativa," and pointed out that in his case there was no preceding gonorrhœa.

Disease of the Vulva.

A case of ? hydatidiform cysts growing in the vulva, exhibited by Lieut.-Col. Sturmer, was referred to a committee.

Hermaphroditism.

Dr. Griffith showed a Pole aged 26 of uncertain sex. He was probably an undeveloped male.

Dr. Hubert Roberts showed a specimen of pseudo-hermaphroditism in a male subject. A very full and interesting description of the pelvic viscera was given.

Vomiting in Pregnancy.

Dr. Maxwell, of China, read notes on two fatal cases of pernicious vomiting in pregnancy. No post-mortem evidence, however, was adduced, and in all probability there was some cause other than the pregnancy that produced the fatal vomiting.

Fœtal Conditions.

Dr. Lockyer showed a specimen consisting of a large cyst which occupied the posterior mediastinum and the greater part of the abdominal cavity of a male infant at birth. Beautiful drawings are published, with a very complete description of the anatomy of the case. Dr. Locker considered it an outgrowth from the early alimentary tract.

Dr. Bonney showed a uterus bicornis unicollis which had been removed from a hydrocephalic fœtus. There were other defects, the hard and soft palates being absent, and there was a double harelip. The septum ventriculorum was deficient, and the aorta came off from the right ventricle. He thought that the phenomena of superfœtation and super-fecundation might in many cases be explained by the presence of a uterus bicornis unicollis.

Dr. Stannus showed an orbital tumour in a hydrocephalic fœtus, which has been referred to the Teratological Committee.

Dr. Andrews showed two cases of fœtal ascites and œdema, one of which had caused difficulty in labour and the other the last born of twins.

New Instruments.

Dr. Davies showed a new pessary.

Dr. Jennings a transfusion apparatus.

Dr. Wise showed a volsella forceps for the soft dilated cervix.

Obituary Notices.

It has been already mentioned that during the last year we have lost six Fellows by death:

1. Eugene Goddard, of Highbury New Park. He received his medical education at St. Thomas's Hospital, and became qualified in 1862. Twenty years later he took the M.D. of Durham. He was elected a Fellow of this Society in 1871, and thus was on our roll for thirty years. He was a very successful practitioner, and although sixty years of age, was still doing a great deal of work; in fact, he died in harness practically, for he was seized after a hard morning's work with a rigor and indications of abdominal mischief, which proved fatal in seven days by general peritonitis. He was conscious of his approaching death, which he met with resignation and fortitude.

2. Thomas Tinley, of Whitby. This gentleman received his medical education in Glasgow and became qualified in 1867. He took the M.R.C.P.Edin. in 1881, and the M.D.Durham in 1886. He became a Fellow of our Society in 1887. As a student he was distinguished, taking numerous prizes. He practised in Whitby, and was Medical Officer of Health for that town at the time of his death. He was Surgeon-Major of the East Riding Yorks Volunteer Artillery and a Lecturer and Examiner to the St. John's Ambulance Association. He was appointed J.P. for the North Riding of Yorkshire in 1899. He was a strong man and had occasion to ride a good deal on horseback, but he suffered latterly from attacks of angina pectoris, one of which proved fatal. He was fifty-five years of age and his second wife survives him.

3. John D. Williams, of Cardiff. This distinguished gynæcologist was only thirty-seven years of age when he died. He graduated at the University of Edinburgh, and took the Gold Medal for his "Thesis on the Pathology

of the Female Generative Organs." He gained the Freeland Barton Fellowship.

For a time he was Demonstrator of Anatomy in Edinburgh, but he left in order to practise in Dowlais with Dr. H. L. Hughes. Three years later he removed to Cardiff, and in 1897 became Honorary Gynæcologist to the Porth Hospital, and in 1898 Honorary Consulting Gynæcologist to the Cardiff Dispensary. Finally he gained the post of Gynæcologist to the Cardiff Infirmary.

He had already acquired a reputation as a gynæcologist in South Wales, and, no doubt, had he lived, he would have had a large and lucrative practice. He wrote several excellent papers on obstetric and gynæcological subjects, and his premature death is greatly to be deplored. It came about in such a manner that it should be a warning to those who spend their holidays abroad, especially as he is not the first victim to similar death traps. Last Easter he visited Rome, and drank some water from a well near the city. He developed typhoid fever, and died from the complication of hæmorrhage.

4. A. E. Aust Lawrence, of Bristol. Dr. Lawrence was born in Bristol in 1848, so that he was only fifty-three years of age when he died. He received his medical education at Bristol and Aberdeen, graduating M.B. and C.M. in 1872, and M.D. in 1874. He began as a general practitioner in Clifton in 1872, but succeeded Dr. T. G. Sevayne in 1875 as Physician Accoucheur to the Bristol General Hospital. He held this post for twenty-one years, and was then made Consulting Physician Accoucheur in recognition of his great services. At the time of his death he was Professor of Midwifery in University College, Bristol, and President-Elect of the Bath and Bristol Branch of the British Medical Association. He was elected a Fellow of our Society in 1875, and was on the Council in 1885, and again in 1888, and became Vice-President in 1889 to 1890. He thus became identified with midwifery and diseases of women, and besides obtaining a good consulting practice he wrote

valuable papers on these subjects. He was a man of great energy, and he used to attend the council meetings and the ordinary meetings of this Society very frequently considering the distance he had to travel. But he was enthusiastic in the branch of medicine he had taken up, and so thought no trouble too great which enabled him to help to advance the science of obstetrics. It was due chiefly to him that there is now well-equipped women's department in the General Hospital of Bristol. Dr. Lawrence was a very pleasant companion, and had a most cheerful disposition. His personal charm of manner will make his loss keenly felt by all who knew him, and particularly by his widow and two daughters.

His death was sudden and unexpected. The day before he was apparently in good health and spirits, but next morning he was found dead in bed, his death being due, as far as could be ascertained, to syncope. The large attendance at his funeral was a testimony to his popularity, and to the love which was felt for him by so many of his friends. In him this Society has lost a loyal and able supporter.

5. Henry Sutherland, of New Cavendish Street, London. Dr. Sutherland was devoted to mental work, having been Resident Assistant Medical Officer to the West Riding County Lunatic Asylum, and also Lecturer on Insanity at the Westminster Hospital. He took his B.A. in Cambridge in 1867, his M.R.C.P. in London in 1870, and his M.D. in Oxford in 1872. He wrote a good deal on subjects connected with insanity, and he took a great interest in the obstetric side of it. In Tuke's 'Dictionary of Psychological Medecine' he wrote an article on "Menstruation and Insanity," and in the 'West Riding Asylum Reports for 1873' an article on "The Change of Life and Insanity." It was not until 1883 that he became a Fellow of this Society. He was nearly sixty years of age at the time of his death, which was caused by heart disease.

6. Surgeon-General Robert Harvey, C.B., D.S.O., F.R.C.P. and LL.D., of Simla, India. Dr. Harvey re-

ceived his medical education in Glasgow and Aberdeen. His life has been spent in India, where at one time he was Professor of Midwifery in the Medical College in Bengal, and Obstetric Physician to the Eden Hospital. He contributed numerous papers to the medical journals on obstetric and gynæcological subjects. He was at the time of his death Director-General Indian Medical Service and Hon. Surgeon to H.E. the Viceroy of India. He was made a Fellow of our Society as long ago as 1865. I have been unable to obtain particulars of his death.

I am sure you will all join with me in expressing sympathy with the bereaved relatives of these Fellows, and it only remains now for me to thank you for a patient hearing.

On the motion of Dr. W. S. Playfair, seconded by Dr. G. E. Herman, a vote of thanks to the President for his address was passed by acclamation.

MARCH 5TH, 1902.

PETER HORROCKS, M.D., President, in the Chair.

Present—30 Fellows and 4 visitors.

Books were presented by Dr. Franta, Dr. Minot, and Dr. Cullingworth.

Wyndham A. Milligan, M.B., C.M.Aberd., was admitted a Fellow of the Society.

The following candidates were proposed for election :—Mary Ann Dacomb Scharlieb, M.D.Lond., M.S., B.S.; Ada Margaret Browne, L.S.A.; Alfred James Rice Oxley, M.D.Dubl.; Florence Nightingale Boyd, L.R.C.P. and S.I., M.D.Brux.

The following gentlemen were elected Fellows of the Society :—Henry J. F. Simson, M.B., F.R.C.S.Edin.; Evan James Trevor Jones, M.D.Brux., L.R.C.P.Lond.; John Tennant, M.A., M.B., C.M.Edin.; H. Simpson Newland, M.B.Adel., F.R.C.S.Eng.

CASE OF RUPTURE OF AN OVARIAN ABSCESS TWELVE HOURS AFTER LABOUR.

By COMYNS BERKELEY, M.B.

DR. COMYNS BERKELEY showed a uterus and appendages removed from a patient who had died twelve hours after labour had ended from acute peritonitis caused by rupture of an ovarian abscess.

The patient was 32 years of age, and had had five children. As far as could be ascertained the only illness she had ever had was an attack of pelvic inflammation before her marriage ten years ago. She had never complained of abdominal pain or leucorrhœa; the periods had been regular and normal. The pregnancy was uneventful except that the morning sickness was rather more troublesome than in previous pregnancies, all of which had ended quite normally.

On January 5th intermittent pains came on, between which the patient was quite well, and she considered labour had started. On January 7th the pain became continuous and was distressing, and about the same time she began to vomit yellow fluid. The extern clerk on arrival found the pulse 100, respirations and temperature normal, no tenderness, membranes unruptured, head presenting, cervix dilated to the size of half a crown, and the patient complaining of pain and sickness. He called again three hours later and found the patient much worse. More pain and sickness, pulse 136, respiration 30, very restless and collapsed; so he sent for the obstetric house physician. Before this gentleman arrived the baby had been born, and the patient then appeared to improve, since the vomiting and pain stopped and pulse fell to 80. The placenta was expressed without any difficulty, and there was practically no loss. Six hours later the obstetric house physician was called, to find the patient very ill. Pulse 136, respirations 60, no pain or tenderness, continuous vomiting, very collapsed.

Dr. Berkeley was then asked to see the case. He found the stomach dilated so that it reached to within two inches of the pubes, partially obliterated the liver dulness, and compressed the left lung so that the percussion note over the left chest resembled that of a pneumothorax. In addition there was marked splashing and frequent vomiting of yellow fluid without any effort. The patient was very collapsed. Dr. Berkeley diagnosed acute primary dilatation of the stomach, and asked Dr.

Campbell Thomson, who lived close by, had seen five cases, and lately read a very able paper on the subject before the Royal Medical and Chirurgical Society, to see the patient. This he was able to do at once, and in the absence of any history or signs pointing to peritonitis, agreed with the diagnosis. The stomach was emptied of over three pints of fluid and washed out, after which the patient appeared to be relieved. She, however, died six hours later.

Dr. Campbell Thomson, who did the post-mortem, found purulent peritonitis with a large amount of semi-purulent fluid in the abdomen. Lungs slightly œdematous. Heart, kidneys, and liver healthy. Spleen enlarged and soft. Right ovary healthy; right and left tubes appear healthy, and are pervious. Left ovary contains an opening at its lower border, through which pus is escaping, and which leads to an abscess cavity. The abscess had also burst into the broad ligament, and pus was escaping from an opening in that structure. The ovary was bound down to the posterior surface of the uterus by old adhesions, and he ended his report as follows:—"Although the dilatation of the stomach was no doubt secondary to the peritonitis, nevertheless it formed the most prominent sign during life, and tends to confirm the view I advanced in my papers that primary acute dilatation of the stomach is closely allied to the great dilatation of the stomach and intestines sometimes found in acute peritonitis."

Dr. Berkeley thought that the abscess had been burst by the contracting uterus some time between January 5th and January 7th, and drew attention to Chapman Grigg's paper in the 'Journal of the British Gynæcological Society,' vol. ii, p. 264, wherein he states that in five patients who died at Queen Charlotte's Lying-in Hospital with symptoms of puerperal fever out of a total of 548 deliveries extending over a period of nine months, four were due to antecedent disease of the ovaries and tubes.

Description of Specimen.

The specimen consists of the uterus, both Fallopian tubes, and the left ovary.

The uterus measures nine inches long, five and a half inches broad, and three inches deep: the cavity measures eight inches.

The uterus has been opened along the whole length of its anterior surface; the placental site is situated on the posterior, left, and upper aspect of the cavity, and appears normal. The cervix is marked by a series of deep lacerations, more marked at the os externum; one, however, runs the whole length of the canal.

The peritoneum covering the uterus is smooth and of normal thickness, and appears normal except in the neighbourhood of the left ovary.

The right Fallopian tube is patent; it is normal in appearance.

The left Fallopian tube is patent, of normal size at its uterine end; its outer end is thickened, and its fimbriated extremity is missing. It is adherent by its middle third to the upper and outer surface of the ovary, whilst its inner third lies on a sac formed by the lifting up of the peritoneum from the posterior surface of the uterus, and this sac is continuous with a cavity in the ovary.

The left ovary is totally adherent to the back of the uterus by its posterior surface, and is occupied in chief part by the aforementioned cavity.

The cavity in the ovary is about the size of a walnut, and is bounded behind and on its outer side by ovarian tissue, on its inner side by the junction of the ovarian tissue with the peritoneum of the uterus, and in front by the uterine wall. Below is an irregular opening through the ovarian tissue, and above this cavity is continuous with a cavity in the broad ligament.

The cavity in the broad ligament is about the size of a bantam's egg, and has been formed by the stripping up of the peritoneum from the posterior surface of the

uterus. It opens above by an opening with clear-cut edges about the size of a florin.

The sac formed by the coalescence of these two cavities has smooth walls, and appears to have a thin membranous lining.

In the immediate proximity of the ovary there is evidence of peritoneal adhesions of some standing.

Report of the Pathological Committee on Dr. Comyns Berkeley's specimen of Ovarian Abscess ruptured during Labour.

We agree with Dr. Comyns Berkeley's description of his specimen, and we find no evidence to show that the infection occurred either through the tube or through the uterus.

(Signed) Comyns Berkeley.
G. F. Blacker.
W. F. Victor Bonney.
Corrie Keep.
G. Bellingham Smith.
April 17*th*, 1902. Alban Doran, *Chairman*.

The President said that the late Dr. Hilton Fagge used to say at Guy's Hospital that there were three conditions in the abdomen which might cause rapid death in an apparently healthy person: (1) perforation of a gastric ulcer; (2) perforation of small intestine in latent typhoid fever; and (3) abscess of the ovary. He asked whether the patient had exhibited any signs of ovarian abscess during the pregnancy.

Dr. T. W. Eden thought that the fact that the tubes were both pervious suggested that the ovarian inflammation was a recent and not a chronic process, as occlusion of the tubes was almost invariable in chronic pelvic inflammation. The absence of any symptoms during pregnancy pointing to infection through the vagina led him to think that this might be one of those cases of bowel infection which we knew sometimes occurred. Could Dr. Berkeley say whether any intestinal adhesions to the ovary were found at the autopsy?

Major Woolbert, I.M.S., remarked that he had seen a somewhat similar case in a bitch. The animal appeared quite well up to the time of her delivery of a litter of pups, after which

she sickened and died in a few days. He made a post-mortem examination, and found an abscess in one ovary with some inflammation of the neighbouring peritoneum. The other organs appeared healthy.

Dr. W. S. A. Griffith remarked on the interest of the specimen, and suggested that it should be referred to the standing Pathological Committee appointed by the Council some months ago. It was difficult to explain the virulence of the infective peritonitis if, as it appeared from the specimen and the history of the case, the ovarian abscess was of long standing, as it was usual in such suppuration to find the pus almost sterile. On the other hand, in recent acute septic suppuration it was difficult to distinguish between a suppuration of the tube or ovary which might be causal, and a suppuration which was a part of the general infection.

A CASE OF TERATOMA OF THE FŒTAL HEAD.

By Hugh S. Stannus,[1] M.R.C.S.

It is a case in which the growth, arising on the right side of the head, involves the cranial cavity, orbit, and cheek in a hydrocephalic female fœtus, with a cleft in the neck, associated with hydramnion which necessitated interference with the pregnancy at the seventh month.

The head, which was detached from the body during delivery, weighs 2 lbs., and measures eleven inches in greatest breadth. At first sight it appears to be that of a double-headed monster, but the enlargement is due to—

1. A large tumour in the upper part of the right side of the face (orbital tumour).

2. A rounded swelling projecting from the right cheek.

3. The hydrocephalic condition of the head.

The larger tumour has pushed the face towards the left, so that the face, left side of head, and anterior surface of tumour are more or less on the same plane; while the posterior surface of the tumour is flush with the right side of the head, and with the exception of the ear, smooth.

It gives the impression that it has arisen in the orbit, and by its growth expanded the outlet, pushing the eye

DESCRIPTION OF PLATE III,

Illustrating Mr. H. S. Stannus's specimen of "Teratoma of the Fœtal Head."

Sketch of the whole fœtus, showing two of the tumours and the hydrocephalus.

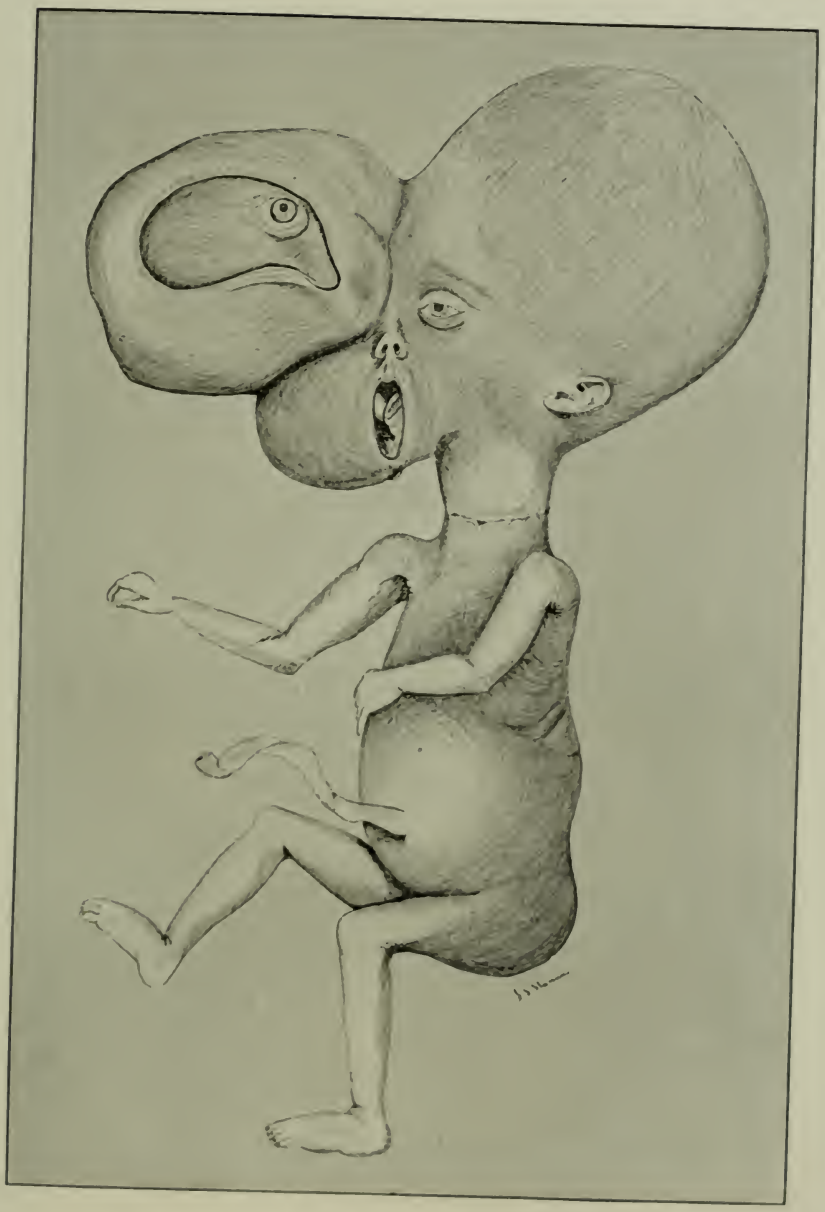

Illustrating Mr. H. S. STANNUS's Specimen of Teratoma of the Fœtal Head.

Engraved and Printed by Bale and Danielsson, Ltd.

in front of it; and this is borne out by the position of the bony margins of the malar and frontal felt through the skin. As a result of this protrusion from the orbit, the palpebral fissure has been dilated in an extraordinary manner. It is seen on the upper and anterior surface of the tumour, and measures $3\frac{1}{2}'' \times 2''$ (the left measuring $\frac{5}{8}'' \times \frac{1}{3}''$).

The lids as such are obliterated, but the palpebral margins are fringed by fine lashes. A shining pinkish membrane, apparently the conjunctiva, covers in the exposed surface, and shallow fornices exist above and below.

Situated at the upper part, and rather nearer the inner than the outer canthus, is the right eye. It appears as if "set" in the mass of new growth, so that while the whole of the iris and cornea are visible and apparently normal, only part of the sclerotic is seen, and the conjunctiva is reflected from the latter on to the tumour. The pupil of the right eye has a reddish tinge, the left being black.

The whole tumour is elastic to touch, much softer in its outer part, where it feels semi-fluid.

The tumour of cheek is rounded, about $2\frac{1}{2}''$ in diameter, and of firmer consistency. Its posterior surface is continuous with that of the larger tumour, but in front the two are separated by a sulcus which runs upwards and inwards, reaching the median line at the root of the nose. The surface is smooth, but presents two or three prominences. The inner limit is formed by the mouth.

The mouth itself is enlarged in a vertical direction, and measures $1\frac{1}{2}'' \times \frac{3}{4}''$, the deformity being evidently due to the presence of the tumour. The upper edge of the alveolus of the lower jaw is seen as a pearly white curved bar notched in the middle, and above the tongue. The roof of the mouth and the hard asymmetrical alveolar margin can be felt. No cleft in the palate exists. The right wall of the buccal cavity is broad, and forms part of the covering of the cheek tumour.

Below the mouth is a cleft with margins resembling

lips. It is somewhat oval in shape, measuring $\frac{7}{8}'' \times \frac{5}{4}''$. Situated at the bottom of the cleft, but projecting up into it, are two bars of cartilage; they are serrated, and enclose between them a third smooth portion; all are attached to the right ramus of the jaw. At the lowermost part of the cleft is a little soft fleshy body, terminating in three finger-like processes. A fine probe can be passed between the cartilages, on the inner side of the jaw towards the median line.

The left eye, nose, and ears are normal in shape and relative position.

The hydrocephalus was not extreme, but the natural configuration of the vault of the skull has necessarily been destroyed by the means adopted to effect delivery.

No brain matter remains in the cranial cavity, but occupying the middle fossa on the right side is a mass about the size of the cheek tumour lying underneath the dura mater.

The body is thirteen inches in length and weighs $1\frac{1}{4}$ lbs., and is that of a seven months' female fœtus. There is no apparent deformity of body or extremities.

The placenta is large, roughly oval in shape, with irregular outline measuring $10'' \times 8''$, and divided into cotyledons of very varying thickness, from one inch to complete absence of placental substance at one spot.

The umbilical cord appears normal, the amount of Whartonian jelly and degree of twisting being a little deficient. The insertion into the placenta is eccentric, being three inches nearer one pole than the other.

The membranes are thin but of great extent (hydramnios = 12 pints). The whole weighs $1\frac{1}{4}$ lbs.

An incision was made on the posterior surface of the specimen, and the skin reflected forwards over the face, in this way allowing the dissection to be carried out without destroying the features.

The three tumours already noticed are found to be connected together by processes of growth, forming one mass which, though it has not invaded the left side of

DESCRIPTION OF PLATE IV,

Illustrating Mr. H. S. Stannus's specimen of "Teratoma of the Fœtal Head."

Sketch to show the relations of the bones and pericranium on the posterior surface of the specimen to the tumours.

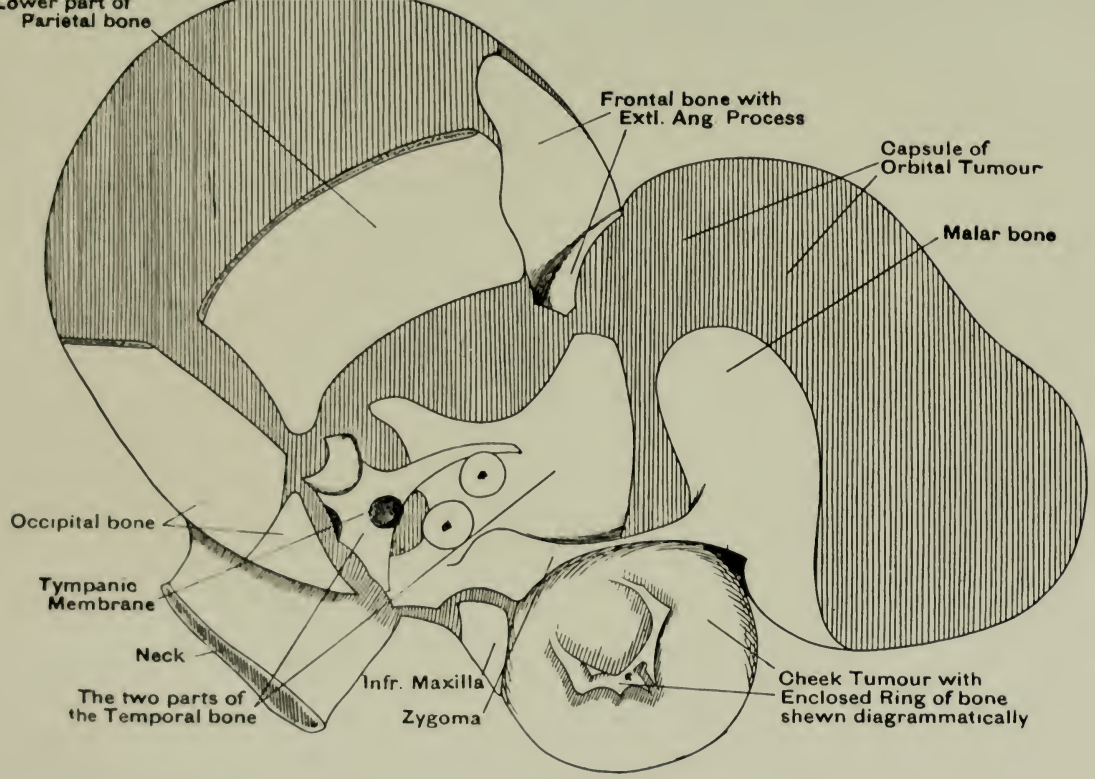

Illustrating Mr. H. S. STANNUS's Specimen of Teratoma of the Fœtal Head.

Engraved and Printed by Bale and Danielsson, Ltd.

the head, involves the right petrous bone and all in front of it.

The arrangement of the bones of the right side of the skull will first be noted, and then the relations of the growth described.

The frontal bone meets its fellow in the median line below, but is widely separated from it above, forming the large anterior fontanelle; behind, it comes in contact with the anterior border of the parietal. The external angular process is well developed, but does not articulate with the malar bone. The orbital margin is expanded, and gives attachment to the capsule of the orbital tumour, but the orbital plate is not fully developed.

The parietal bone is normal in shape, and articulates in front and behind with the frontal and occipital bones respectively. The inferior concave border does not articulate with the upper margin of the temporal bone, which is deficient in that situation, so that a space is left between these bones covered in by pericranium, forming the wall of the temporal fossa.

The greater wing of the sphenoid is also deficient, and takes no part in the formation of the fossa.

The temporal bone consists of two ununited portions; the larger is roughly quadrilateral, the smaller triangular, base upwards, apex downwards, lying between the former portion and the occipital bone, and articulating with the former by a long process which fits into a groove formed by a little boss of bone just above the root of the zygomatic process. Two spaces, only protected by pericranium, are formed between the two parts; the upper one corresponding to a cavity in the petrous bone, filled by a process of the intra-cranial tumour; the lower also opens into the same space at its lower part. Close to the latter, in the smaller portion, is the tympanic membrane and ring of bone.

The squamous portion is partly undeveloped, leaving an upper concave border, bounded at either end by a process projecting upwards; the anterior one lying under the

external angular process of the frontal, but not articulating with it, the other being normal; in this way the space before mentioned is formed.

The zygomatic process runs forwards to meet the corresponding process of the malar; the capsule of the cheek tumour is attached to it along its whole length, not, however, involving it in the growth. The anterior border of the temporal is slightly concave, and lies parallel with, but separated from the posterior margin of the malar by a band of pericranium half an inch wide in the absence of the ala of the sphenoid. The posterior border articulates normally with the occipital bone, which is itself normal.

The natural floor of the middle fossa of the cranial cavity is deficient owing to the absence of the ala of the sphenoid, which is represented by a small portion of bone close to the median line. The lesser wing is present as a small spicule adherent to the margin of the orbital plate of the frontal. A false floor is formed on a lower plane by the incurved lower part of the temporal and the upper surface of the superior maxilla.

A cavity is thus formed in which the intra-cranial tumour lies, bounded on the outer side by the squamous portion of the temporal, behind by the petrous, on the inner side by the vertical plates of the maxilla, palate, ethmoid, and sphenoid, above by dura mater, and also in front by the orbital plate of the frontal. In front it is partially closed by a membranous curtain enclosing a delicate plate of bone which separates the intra-cranial mass from the orbital tumour. The septum is, however, incomplete below and at the sides, where processes of growth unite the two.

An oval aperture three quarters of an inch in diameter exists in the floor, formed by the lower concave margin of the temporal on the outer side, the outer border of the maxilla on the inner; behind it is completed by the petrous and in front by fibrous tissue which partly covers over the aperture, and to which is attached the ring of bone found in the cheek tumour; through this aperture

communication exists between the intra-cranial and cheek tumours.

The superior maxilla consists of a horizontal plate with nasal, palatine, malar, and alveolar processes. The horizontal plate is concave on its upper surface, and with the concave outer surface of the vertical plate and nasal process forms part of the floor and walls of the cavity mentioned above; the antrum is absent. The posterior border of the vertical portion and palatine process articulate with the sphenoid and palatal bones. On the under surface of the horizontal plate the curved alveolus is seen running from near the anterior part of the aperture at the base, to the mid-line in front. A process also projects outwards and downwards to articulate with the malar.

The malar bone, recognised by its zygomatic process, is expanded into a curved plate of bone which lies in the plane between the two external tumours, and is partly subcutaneous. Its upper end and anterior border are free, and give attachment to the capsule of the orbital tumour, the former lying below and in front of the external angular process of the frontal; the posterior border has been noticed. The lower part curves inwards, lending support to the orbital tumour, and articulates with the maxilla at a point in front between the two tumours on a level with the middle of the mouth.

The jaw articulates normally with the skull at the root of the zygoma, but the ramus is displaced backwards, and fixed in that position by the cheek tumour wedged in between it and the zygoma. As a result the mouth is widely open, and the tumour which forms the prominence in the cheek also bulges into the mouth.

As already described, the middle fossa is apparently occupied by the intra-cranial tumour; it, however, fills the larger cavity previously mentioned. The capsule of dura mater is, however, very definitely attached to the boundaries of the fossa; from it fibrous septa pass into the mass, dividing it into lobules, and including in them delicate plates of bone.

The lobules in the upper part of the tumour are well formed, and yellow in colour; several lie rather separated from the main mass; one such lies under the orbital plate, separated from the orbital tumour by the curtain. Another process occupies a little fibrous sac bounded externally by the pericranium in the interval between the parietal and temporal bones; a third extends into the petrous bone, which is in consequence expanded and hollowed out.

The lower part of the tumour is almost diffluent, and projecting up into it are several spicules of bone derived from a little mass near the median line, no doubt portions of partly absorbed sphenoid. From this lower portion processes pass through the aperture in the floor and through the lower part of the opening in front to the cheek tumour and orbital tumour respectively.

The orbital tumour is made up of several distinct masses, corresponding partly to the bosses seen on the outer surface. The capsule is derived from the periosteum of the bones forming the outlet of the orbit, viz. frontal, maxillary, and malar. Septa pass into the tumour separating the lobes, each having a well-marked finer capsule of its own, from which it shells out easily.

The largest lobule occupies the uppermost part of the tumour; it is very firm, rounded, and about two inches in diameter. In front of this is another mass which forms the prominence just above the nose, while the outer part of the tumour is composed of three other masses, smaller, softer, and semi-fluid. These masses are all in communication with the lower part of the intra-cranial tumour.

The eye is represented by a shell consisting of the ciliary body and parts anterior to it, and lies outside the capsule between it and the exterior.

The cheek tumour is in great part subcutaneous, and the skin over it is easily removed, discovering the capsule covered by layers of muscular fibres. The capsule is attached at the base of the skull to the margins of the aperture in the formation of which the temporal, maxilla, and sphenoid take part, and also derives support from the

zygoma above, ramus of jaw behind, and surrounding soft parts; on the inner side it is limited by the buccal cavity.

The mass, which can be shelled out from its covering, consists of a soft, red, marrow-like substance with a fibrous stroma. Buried in its midst is a ring of bone fairly regular in shape, and one inch in diameter. It has a flattened process which is attached by fibrous tissue to the base of the skull, and partially closes the aperture through which this tumour communicates with the intra-cranial mass.

The dissection of the neck revealed the larynx and thyroid body normal in size and position.

A fine probe passes in between the cartilaginous bars of the cleft, which are attached to the lower part of the right ramus along a canal which runs on the inner side of the ramus of the jaw, upwards to the base of the tongue, where it opens into an otherwise closed cavity filled with mucus.

The abdominal and thoracic viscera presented no abnormalities, and were not the seat of any growth.

Microscopically the new growth shows various stages in the differentiation of embryonic cells into almost every tissue of the body. Thus the transition into fibrous, myxomatous, and areolar tissue is seen, also striped muscle-fibre, likewise cartilage, fat, and here and there areas of calcification with attempts at bone formation. Other cells have taken on the character of epithelium; masses of such cells are seen grouped together in definite arrangement with the appearance of a central cavity, so forming a gland-like tubule. In some places the wall is invaginated into the lumen, in others the cavity is occupied by granular material.

Several rings of columnar epithelium are seen enclosing within them cells resembling endothelium. Larger spaces also exist lined by a stratified epithelium, the innermost layer sometimes ciliated, containing as a rule masses of cells and débris.

Several spaces surrounded by lymphatic tissue and fibrous coats exhibit a mucous membrane containing glands lined by goblet-cells, the whole resembling some portion of the alimentary tract.

The history of the case is as follows:—The mother and father were Italians aged forty-one and forty-six, and were in no way related before marriage.

There was nothing of interest in the family history; no deformity or abnormality had ever been observed in any member of the family. No history of tuberculosis, syphilis, or gonorrhœa.

The mother had always enjoyed good health. She was married fourteen years ago at the age of twenty-seven, and had had seven children and one miscarriage; the confinements had always been normal and uninterrupted by any inflammatory trouble.

The first five children are alive and healthy, the sixth and seventh died with bronchitis aged six and ten months respectively.

The miscarriage had occurred ten months before admission, at the fourth month. Menstruation had been re-established soon afterwards, and continued regular till February, 1901. Patient then thought she was pregnant, but noticed nothing unusual till the six weeks before admission to hospital. During that time her symptoms had been referable to great and rapidly increasing distension of the abdomen, a feeling of weight, shortness of breath, and later inability to rest in any one position, some vomiting and dyspepsia with anorexia; her previously existing varicose veins were exaggerated, and some œdema of legs had appeared.

She was sent up to St. Thomas's Hospital as a case of extreme ascites complicating pregnancy, and admitted 12th October, 1901.

On admission a fairly well-nourished woman, with no signs of any constitutional disease. Except the abdominal condition the only other point noticed was the presence of numerous flat-topped brownish warts situated on the

chest and in both axillæ ; one larger than the rest was black and mulberry-like in appearance, and sprang from the left side of the pectoral region.

The abdomen was greatly enlarged, forming a dome-shaped swelling as the patient lay in the bed. The greatest girth measured forty-eight inches, three inches above the umbilicus.

The distension was evidently due to a tense encysted collection of fluid.

A well-marked fluid thrill could be obtained between any two points ; external ballottement could with difficulty be made out, but no fœtal parts could be detected. The whole was dull to percussion except a narrow band at the subcostal margin and the flanks, which were resonant.

Vaginal examination revealed the cervix lying high up and the canal patulous, admitting two fingers. The bulging membranes could be felt at the internal os, and it was evident that the cervix was continuous with the large abdominal cystic swelling.

Hydramnion was diagnosed, and it was decided to relieve the condition. Three hours after admission the membranes were ruptured with the immediate escape of twelve pints of amniotic fluid. Owing to the size and shape of the contents of the uterus, which then became apparent, it was thought probable that twins were present. Twelve hours later patient complained of pain, and a foot was found presenting ; the second leg was brought down and the body immediately followed.

Efforts to deliver the head by the ordinary means proving unsuccessful, the finger was passed into the uterus, when it was discovered that delivery was obstructed by a hydrocephalic head.

Perforation was attempted, and resulted in the escape of a collection of blood-stained fluid from between the scalp and the vault of the skull. Chloroform was then administered, and in the efforts of traction, the body separated from the head.

The enlarged presenting fontanelle was then perforated,

with the escape of a large quantity of fluid; the opening was enlarged, and the brain matter, together with most of the bones of the vault, removed before delivery could be effected; the remains of the vault appeared first, then the face, and lastly the tumour masses.

It was found necessary to remove the placenta digitally.

The patient made an uninterrupted convalescence.

Bibliography and short account of cases of somewhat similar character to the above, viz. examples of the condition called by Taruffi Exopiosopus amorphus.

"Teratoma Orbitæ Congenitum." Archiv für path. Anat. und Physiol, von Virchow, 6 Folge, Band vii, 67, 1876.

Vrolik.—Nieuwe Verhandelingen der I Cl. van het Koninkl. Nederl. Instituut, Amsterdam, 1831, Bd. iii, S. 211.

Ahlfeld.—Archiv für Gynaek., Berl., 1874, S. 216.

A tumour situated in the buccal cavity of a fœtus beneath the left cheek. It was four and a half inches in diameter, and consisted of fibrous tissue, cartilage, and portions of the bone of the lower extremity. There was also present a body resembling the placenta, and a portion of intestine with the vermiform process.

Soemmering, S. T. L.—"Catalogue of the Anatomical Museum of Giessen." Frankfort-on-Maine, 1830, s. 77, N. 27.

A tumour projecting under the left cheek into the posterior part of the mouth of a fœtus, and producing deformity of the larynx and œsophagus. Portions of the upper and lower extremities of a fœtus with parts of the intestine, and a number of cysts with atheromatous contents, made up the greater part of the tumour.

Bury.—Lond. Medical Gazette, vol. xiv, May 24th, 1834.

A tumour situated under the skin of the cheek, and attached to the right superior maxilla of a fœtus. It consisted of two halves, separated by a process of bone derived from the frontal bone of the host. The interior of the tumour contained a serous fluid, some bones, parts of three limbs, and portions of skin covered with hairs.

Regueras Giovanni.—"Di un mostro umano dermocimo:" Narrazione letta all' Acad. Giornia, 1850. Catania, 1850, con tav.

In a male fœtus, born at full term, the author found a tumour, with a diameter of eight inches, attached to the whole of the area corresponding to the inferior maxilla and to the upper part of the front of the neck.

The stroma of the tumour had the appearance of a spongy mass, containing numerous vessels, not unlike a placenta. In this tissue was found a membranous tube resembling intestine.

In other parts of the tumour were present rudimentary portions of back bones, and a substance resembling brain tissue.

Hess, Wilh.—"Beitrag zur Casuistik der Geschwülste, mit Zeugungsähnlichem Inhalt. Diss., Giessen," 1854. Kanstatt's Jahresbericht, 1854, Bd. ii, S. 31.

A tumour in the left cheek of a female fœtus, double the size of a fœtal head. It contained numerous cysts, some blind canals with the structure of intestine, and fragments of bone in part resembling a forearm, hand, and lower extremities.

Bröer und Weigert.—Virchow, Archiv, Bd. lxvii, S. 518, 1876.

A fœtus with a tumour projecting from the right orbit. The optic nerve formed the pedicle of the tumour, while

the ocular bulb lay upon it. The greater part of the tumour consisted of connective tissue containing cystic spaces, with some fragments of cartilage and bone.

On microscopic examination were found connective tissue, epithelial cells, lymphatics, smooth muscular tissue, and vessels. Some of the cysts were lined by a mucous membrane resembling that of the intestine.

Ford.—Amer. Journ. of Med. Sciences, Jan., 1879. Philad.

A tumour situated in the right cheek and upper part of neck of a fœtus. It had a connective-tissue capsule and brain-like contents, containing fatty tissue, cartilage, mucous membrane, and epithelium.

Ahlfeld, F.—Die Missbildungen, 1880, p. 52, Table vi, fig. 11.

A fœtus with a tumour springing from the left orbit, consisting of a mass resembling a button, and the left lower extremity.

Attached to the cheek near the left angle of the mouth was a tumour with the consistence of the liver. The fœtus had also a frontal encephalocele.

Pancoast.—Medical and Surgical Reports, new series, vol. i, p. 405, 1859.

A fœtus with a tumour springing from the left cheek as large as an apple. Attached to the surface were some fingers and part of a forearm. The interior of the tumour contained portions of intestine and a substance like liver.

Morison, J. Rutherford.—Edin. Med. Journal, vol. xlii, July—December, 1896, p. 130.

A tumour successfully removed from the right side of the face of a male child eleven months old. The mass, about the size of a Tangerine orange, was attached to the part between the nose and right eye. It was covered

partly by skin and partly by mucous membrane, and consisted of fibrous and mucous tissues irregularly mingled.

Ballantyne, J. W.—Trans. Edin. Obstet. Soc., vol. xxiv, 1899, p. 47.

A Siamese boy, seven years old, with congenital tumour covering almost whole of right side of face, which had grown with the general growth of the boy. Base of tumour extended from forehead to end of nose. Tumour soft and doughy over greater part, probably a teratoma. Photographs only shown.

*Report of Teratological Committee upon Mr. Stannus's Specimen of Orbital Tumour in a Fœtus.**

We have carefully examined the dissected specimens and the microscopical sections of various parts of the tumour, and we consider that the whole growth, consisting of the three tumours and their processes, is of the nature of a *teratoma*. The growth is so extensive that it is not possible to ascertain the exact point of its origin, nor is it possible to say what portion of the whole mass represents the oldest part of the tumour. We are unable to determine whether the deficiencies in the bones of the skull are due to defective ossification, or to absorption of the bone during the process of growth of the tumour; probably both these conditions are present in different parts of the specimen.

The cleft in the neck with the canal leading from it probably represents a persistence of the lower part of the first branchial cleft.

G. F. Blacker.
Hugh S. Stannus.
Alban Doran, *Chairman.*

February 16th, 1902.

* Exhibited at the December meeting, 1901.

SOLID TUMOUR OF THE LEFT OVARY WITH AN ATTACHED CYST COMMUNICATING WITH THE LEFT FALLOPIAN TUBE.

By Victor Bonney, M.D., F.R.C.S.

The specimen was removed *post mortem* from a woman aged 56, who had suffered from an abdominal tumour for twelve years. In October, 1901, symptoms of intestinal obstruction appeared, which terminated by the spontaneous extrusion *per rectum* of an intussusception of the large intestine about six inches long. The patient temporarily recovered, but in February, 1902, similar symptoms appeared, and she rapidly sank and died.

The specimen consists of a large solid tumour of the left ovary, thinly encapsuled.

Attached to the entire upper surface of the tumour is a thin-walled cyst, now much shrunken, but holding during life many quarts of fluid of a watery consistence. This cyst is prolonged through a somewhat valve-like opening into the much dilated left Fallopian tube. The wall of the tube, like that of the cyst, is thin and membranous, and there is no line of demarcation between them. The cyst wall on reaching the upper surface of the tumour bifurcates into two parts. Of these, the outer is continuous over the outer surface of the tumour, forming a thin capsule. The inner passes over the upper surface of the tumour, forming the lower boundary of the cyst cavity.

Within the tumour is a second cavity, the size of an orange. It is surrounded by a smooth fibrous capsule, and is irregular in outline. It is separated from the cyst above the tumour by a layer of tissue about half an inch in thickness. It contained a grumous thick fluid.

At the back of the tumour are seen some remains of its attachment to the broad ligament and uterus.

At the further end of the tumour is a mass of adherent omentum.

Beneath the dilated tube is the mesosalpinx. Sections of the dilated tube show a simple fibrous structure without trace of epithelium. A section taken at the junction of the cyst wall with the tumour shows the cyst wall to be composed of simple fibrous tissue without any epithelial lining. The tumour beneath it is composed of a mass of fibrous tissue, containing many nuclei, within which are many spaces of irregular and variable size, and lined by a single layer of columnar epithelium. Several sections taken from different parts of the tumour all show this structure. In many places the epithelial lining of the spaces appears to have disintegrated.

There is no evidence of epithelial infiltration in any part of the specimen.

Report of the Pathological Committee on Dr. Bonney's Specimen of Solid Ovarian Tumour with a Cyst attached, with the Tube open.

We are of opinion that the tumour consists of a solid ovarian growth showing cystic degeneration, and of a thin-walled cyst attached to it, into which the tube is seen to open, and which we regard as itself the dilated outer portion of the tube.

We have examined microscopic sections of the tumour, and we find that it has the structure of an adenoma.

(Signed) G. F. Blacker.
W. Forster Bonney.
G. Bellingham Smith.
Corrie Keep.
Alban Doran, *Chairman.*

May 2nd, 1902.

SARCOMA OF OVARY.

Shown by Peter Horrocks, M.D.

The President showed two sarcomata of the ovary, each tumour being the size of a football. They were removed recently from two patients who presented almost identical symptoms, namely, a large freely movable solid tumour, together with abundant ascites necessitating paracentesis in one case to relieve dyspnœa, marked wasting, pyrexia, and pleurisy. The last was thought to be due possibly to secondary growths. Both patients were making a good recovery.

It was interesting to note that in one case the small intestines were so intimately adherent as to require a very careful dissection, whilst in the other case there were no adhesions. Now in the former the sarcomatous elements were most abundant, whilst in the latter the fibrous element predominated. Both women were multiparous, but one with the marked sarcoma was under thirty, and the other about forty years of age.

Mr. Corrie Keep thought that, independently of any secondary deposit of new growth, pleuritic effusion was not uncommon in cases of fibromatous or sarcomatous tumours of the ovaries. He had seen two cases of fibroma of the ovary accompanied with serous pleuritic effusion, which had completely cleared up after removal of the tumour. In one case the tumour was growing on the opposite side to the effusion, and in the other on the same side. He was unable at present to ascribe any adequate cause for the condition. He also thought that it was most desirable that the after-history of all patients from whom solid ovarian tumours had been removed should be most carefully kept and reported, with a view to distinguishing in the future between malignancy and innocence in this class of growth, where microscopic examination at present frequently results in doubt or in error.

Dr. Amand Routh asked if the pleural effusion was on the same side as the ovarian affection. In all the cases observed by him this had been the case, pointing to the possibility of lymphatic conveyance of the inflammatory process.

LITHOPÆDION RETAINED IN PATIENT FOR SIXTEEN YEARS.

By Walter Tate, M.D.

The patient from whom this specimen was removed was a married woman aged 46. She had had one still-born child twenty-two years ago. Sixteen years ago she missed two periods, and soon afterwards was suddenly seized with severe pain in right side of abdomen, while stooping to tie up her boots. She went to bed, and had hot fomentations applied. After a few days she got up, but soon had to return to bed on account of severe hæmorrhage from vagina and return of abdominal pain. After this she was in bed on and off for two years, during which time she had attacks of pain followed by hæmorrhage. From this time till August, 1901, she was in fairly good health. In August last she was suddenly attacked with severe pain in the left iliac region. The pain continued, though varying in intensity, up till the time of her admission to St. Thomas's Hospital on December 28th, 1901.

On admission the uterus was anteflexed and tilted a little to the right. On the left side was a hard, irregular, craggy swelling, as large as a hen's egg, extending outwards from the uterus to the pelvic wall. The consistence of the mass suggested either a dermoid cyst of the ovary or cancer of the Fallopian tube.

Abdominal section was performed on the 2nd January, 1902. There were firm adhesions of the mass to the uterus, broad ligament, omentum, and intestine. On separation of these the hard spiculated nature of the mass was evident. It was also seen that the mass was firmly incorporated with the ovary, and though attached to the right uterine appendages it had rotated over in front of the uterus to the opposite side. In this way the

situation of the swelling found on bimanual examination was explained.

The tumour removed was pyriform in shape, measuring $2\frac{7}{8}$ inches in length and $1\frac{5}{8}$ inches across at the widest part. The orbits and prominence of the nose were easily recognised in the upper spherical part of the mass, and bony spicules three fourths of an inch long represented remains of long bones of the limbs.

The Fallopian tube appeared to be normal, and showed no evidence of any rupture.

The lithopædion probably resulted from a tubal gestation which ruptured sixteen years before the patient was admitted.

SUPPRESSION OF URINE AFTER LABOUR.

By R. G. McKerron, M.A., M.D.

(Received January 20th, 1902.)

(*Abstract.*)

Attention is first directed to the fact that suppression of urine before or after labour is rare, notwithstanding the frequency of pathological changes in the kidneys during pregnancy. From recent experience the author is disposed to believe that as a puerperal complication complete or partial suppression is more common than the small number of recorded cases would suggest. He describes three cases which came within his own knowledge, adding short abstracts of three cases of complete anuria found in literature.

The causation of anuria after labour is, he observes, obscure. To assist in the solution of the causal problem an analysis of the leading clinical features of the cases is given, from which the author concludes that several factors are concerned in its production, and that these may be variously combined in different cases. The essential causes he believes to be (1) a nephritis, similar to that underlying eclampsia, and probably superimposed on kidneys previously defective, (2) a neurotic temperament, (3) shock, resulting from precipitate labour or from intense pain accompanying its progress.

The paper concludes with a few observations on treatment and on the possible effect of opium in contributing to the suppression.

The changes produced by pregnancy in the kidneys and in the urinary secretion have been, and promise for some time to be, the subject of much discussion. Serious dis-

turbances in the renal function have long been recognised as among the most dangerous complications of gestation, but the physiological merges so insensibly into the pathological that it is far from easy, often impossible, to determine the exact point at which the normal is transgressed and danger begins.

It is to the urine we must look for an indication. An early and constant sign of morbid changes in the kidney is to be found in a lessened secretion of urine, with albuminuria and a lessened elimination of urea. In the most serious form, more especially in that which results in eclampsia, this diminution is very marked, as shown in the interesting series of cases reported by Herman.*

When these pathological changes are the result solely of the pregnant condition they usually disappear rapidly on its termination, though in eclamptic cases death may ensue before the functional activity of the kidneys has been restored.

Though a marked diminution in the quantity of the urine as the result of the nephritis of pregnancy is not uncommon, complete suppression is rare, and I know of no instance in which it has been noted *during gestation* apart from eclampsia or surgical interference. Bland-Sutton † records a case in which anuria followed ovariotomy in the ninth month of gestation, necessitating the induction of labour. Although such an untoward result is by no means an infrequent experience of the surgeon in other as well as renal cases, as an obstetric complication it is extremely rare. So uncommon, indeed, is suppression of urine after labour, apart from eclampsia, that no text-book even mentions it; while, so far as I can gather, literature furnishes only three instances of its occurrence.

Recent experience, however, has led me to the conclusion that total or partial suppression of urine is not so uncommon a puerperal complication as these scanty records would suggest. At any rate, in the last three years three

* 'Obstet. Trans.,' vols. xxix and xxxii.

† 'Lancet,' 1895, i, p. 461.

cases have come within my own knowledge, two of complete, one of partial suppression. Altogether we have a series of six cases, in five of which the suppression was complete. Notwithstanding the dangerous nature of the condition, it is a remarkable circumstance that in one only of the cases, in which symptoms of serious disturbance existed before and during labour, does the gravity of the complication seem to have been immediately recognised, with the result that valuable time was lost in initiating active measures of treatment. As will be seen, there was nothing during pregnancy or labour to arouse suspicion, and the medical man, unaware that an entire suspension of the renal function may follow an apparently normal and easy labour, was lulled into a false security by the absence of urgent symptoms, which is so characteristic a feature in many cases of suppression of urine. This important fact is of itself sufficient to justify the present paper.

The causation of suppression of urine after a physiological process which is normally accompanied by an increased activity of the secretory organs, though meantime obscure, is a subject of great interest, and, owing to its dangerous character, of great importance. The question, however, is too complex to be settled by so small a number of cases, more especially as we have to rely on purely clinical evidence. Further, from the fact that few symptoms were present during pregnancy the records are necessarily incomplete.

I shall first give the details of the three cases which came within my own knowledge, and thereafter, to complete the evidence, shall add an abstract of the three published cases.

Case 1. — *Suppression of urine following premature delivery of a stillborn fœtus in the eighth month; no symptoms during pregnancy; duration of suppression one week; recovery.*

Early in April, 1897, I was consulted by Mrs. S—, who wished to engage me for her confinement. She was

in the eighth month of her first pregnancy. She was twenty-three years of age, high-coloured, but of a delicate and strumous appearance, and markedly neurotic.

A week or two before coming to me she began to observe swelling of her ankles and puffiness of the face and hands. This increased, and when seen by me the œdema was quite obvious but not excessive in amount, and was limited to the situations mentioned above. Her urine was found to be scanty in amount and almost solid with albumen. She was ordered rest in bed, and put on an exclusively milk diet. This led to an improvement in the condition of the urine, which increased in quantity and contained less albumen, but, notwithstanding, in a few days labour pains set in, and she was delivered after an easy labour of a seventh-month fœtus, which had evidently been dead for over a week. She made a good though somewhat slow recovery. The albumen rapidly diminished in amount, but did not finally disappear till three weeks after labour.

In the beginning of September, 1898, she again became pregnant. In the interval the urine was examined on two or three occasions, and found free from albumen. In the early months of pregnancy she was remarkably well. There was no sickness, nor was there any œdema. The urine was tested at intervals of about a month, but showed no albumen.

On the forenoon of April 17th I received a message to call on her. At 3 a.m. she had been seized with a sudden pain in the lower part of the abdomen, which in about an hour abated, but was followed at 5 a.m. by intense sickness and vomiting. This continued intermittently till I saw her at noon. She was not in bed. She still complained of sickness and of pain in the back and abdomen, not severe but continuous. There was a slight appearance of hæmorrhage from the vagina, which showed only as a mere stain. She was sent to bed, and for the sickness an effervescent saline medicine was ordered, along with a mustard poultice for the epigastrium. The urine, which

owing to an oversight had not been sent to me for six weeks, was to be kept for examination. Soon after I left the vaginal hæmorrhage increased, and I was again summoned at 2.30 p.m. On my arrival it was evident that there had been considerable bleeding. Pain in the back, and to a less extent in the abdomen, was still complained of. On examination it was found that the os uteri admitted a finger readily, but the cervix was not drawn up; the head presented: the placenta could not be felt in the lower uterine segment. The hæmorrhage had stopped, and there were no labour pains. Absolute rest in bed with the application of a tight abdominal bandage was all the treatment employed. I visited her again at 6 p.m. In the interval there had been no further bleeding, but the sickness and pain in the back were as before.

Having to leave town for a few hours I gave instructions that Professor Stephenson, who had kindly consented to take charge of her in my absence, should be sent for in the event of further bleeding or of labour pains beginning. About 8 o'clock an urgent message was sent to him, but before his arrival a seven and a half months' dead but quite fresh fœtus had been expelled, almost without warning, after two or three strong pains. There was no great hæmorrhage. The placenta was found to be covered almost in its whole extent with adherent black clots. About an hour after labour she was left in an apparently satisfactory condition.

She passed a fair night, save that she was much troubled with sickness; any attempt to take fluid, either water or milk and soda, caused vomiting. No urine had been voided. There was no evidence of bladder distension, but at 1 o'clock the nurse passed the catheter. Only one half-ounce of urine was drawn off. When this was examined it was found to contain one quarter albumen, while the deposit showed blood-corpuscles, triple phosphates, and epithelial casts; urea ·25 per cent.

I saw her again late in the afternoon, and introduced the catheter, but no urine was obtained. The sickness still

continued, but otherwise she made no complaint of pain or discomfort. The temperature was normal, the pulse but little accelerated and of no great tension; tongue clean and moist; skin dry and harsh. She was ordered ice to suck, iced water and iced milk and soda. A hot fomentation was applied to the renal region.

19th.—Apart from occasional sickness she had passed a fair night. Vomiting occurred only on attempt to take fluids. The vomited matter was watery, containing flocculent-looking masses of a light blue colour, which resembled nothing so much as the precipitate got on adding the liquor potassæ and tartrate solutions for Fehling's sugar test. The lochial discharge was small in amount and well under the average. No urine had been passed, but as there was no evidence of bladder distension the catheter was not used. Poultices were continued to the lumbar region, and a diuretic mixture was ordered. The mixture caused vomiting, however, as did everything save ice and iced water. Occasionally iced milk and soda in very small quantity was retained.

20th.—The symptoms and general condition were as before, save that she now complained of slight headache and some aching pain in the loins. No urine had been passed. Poultices were applied, and a hot pack ordered. A compound jalap powder was given, but as it was at once rejected an enema was administered.

21st.—No urine had been voided; pulse and temperature subnormal; pupils normal; the sickness somewhat moderated, but apt to be induced by taking any fluid. A pint of warm, normal saline solution was injected into the rectum, followed by a hot pack. The saline solution in part returned, but a few minutes later she passed 8½ ounces of urine, after which she expressed herself as much relieved. From the analysis of this urine, which follows, it might be supposed, and is possible, that it contained some of the saline solution from the rectum. It may be remembered, however, that the first urine passed after a period of suppression almost constantly shows a lessened percentage of

urea. Analysis: urine slightly acid, sp. gr. 1010; urea ·01 per cent., or 4 grs. in all; a trace of albumen; pus and blood-corpuscles in the deposit.

At 7 o'clock the same evening another injection of saline solution was given, followed two and a half hours after by a hot pack, after which she expressed a wish for hot fluids, and was allowed hot water and milk and a little tea, all of which she retained.

22nd.—A slight improvement was visible; temperature, as seen from the accompanying chart, still subnormal; sickness now only occasional, most of the fluids she took being retained, as also a small quantity of thin corn-flour. The same treatment was continued, but in the twenty-four hours only 4 ounces of urine were passed, which gave the following analysis:—Reaction slightly alkaline, sp. gr. 1016; urea 6 per cent., or 12 grs. in the twenty-four hours; albumen ·15 per cent. by Esbach; deposit blood and pus cells and triple phosphates.

23rd.—Little change in the general or renal condition, only a small quantity of urine—5½ ounces—being passed in the preceding twenty-four hours. In this there were 24¾ grs. of urea and ·06 per cent. of albumen, while there were still some blood-corpuscles in the deposit.

24th.—Considerable improvement; pulse and temperature continued normal, while the skin was much less harsh and inclined to perspire. During the twenty-four hours up to 4 a.m. on the 25th, 12 ounces of urine were passed, an analysis of which gave the following result:—Reaction sp. gr. 1010, urea ·9 per cent., blood-corpuscles, albumen a trace. The patient looked very well, and expressed herself as very much better; indeed, notwithstanding the fact that up to this time—the seventh day—only 90 grs. of urea had been secreted, she never looked really ill.

25th.—In the twenty-four hours ending 4 a.m. on the 26th the quantity of urine passed was 49 ounces. Examined, it gave the following result:—Reaction acid, urea

1·15 per cent., or 232 grs. in the twenty-four hours; albumen ·01 per cent.; a few pus and blood cells.

The patient seemed and felt quite well. There was little tendency to sickness, almost all the nourishment she took being retained.

For the next few days there was marked polyuria, 64 ounces being passed on the 26th, while on the following day there were 72 ounces, which on examination showed an acid reaction, a sp. gr. of 1010, with ·9 per cent. of urea and ·05 per cent. of albumen; there were no blood-corpuscles or casts. On the next two days 96 ounces and 120 ounces were obtained, the analysis of which was similar to the above.

The urine was tested at intervals for some months, and contained a trace of albumen for about six weeks after labour.

This case has a peculiar interest in being the sole recorded instance, to which at least I have had access, of prolonged anuria after labour which ended in recovery.

Case 2.—*Complete suppression of urine preceding and following premature labour at the beginning of the seventh month; death: child stillborn.**

Mrs. S—, aged 42, a spare woman of slender build and of a markedly neurotic temperament, was delivered of her first child, which is still alive, 10½ years ago. Throughout the greater part of pregnancy she suffered from excessive nausea, sickness, and prostration. The urine continued free from albumen throughout. After labour, which was at term and attended with an unusual degree of suffering, she made a good recovery. She has since had two miscarriages, the last six years ago. In both the pregnancies she was similarly affected with sickness and prostration, which in the earlier was so great as to cause considerable anxiety to the medical attendant, who on one or two occasions was on the point of inducing premature labour. Both, how-

* For the report of this case I am indebted to Dr. John Gordon, of Aberdeen.

ever, spontaneously terminated at the sixth month in the birth of dead children.

In the early months of the present pregnancy she suffered from a recurrence of vomiting and nausea, which, however, were not so severe, and passed off towards the end of the fourth month, after which she was in very good health. The urine was not tested on this occasion, the symptoms being so similar to those in previous pregnancies when the urine was found not to contain albumen.

Early in the morning of October 20th, 1901, she was suddenly seized, in the beginning of the seventh month of pregnancy, with severe pain in the hypogastrium, followed soon by a slight discharge of blood from the vagina. She was seen at 8 a.m. by Dr. Gordon, who was struck by her waxy appearance and her expression of great suffering. She was much troubled with sickness and retching, and had intense continuous pain over the uterus, which was tender on pressure. There was no œdema. As examination showed no signs of commencing labour, a mixture containing ergot and morphia was given. Later in the forenoon the condition was much the same. For the abdominal pain, which was still very severe, a morphia pill was ordered every four hours.

At 6 p.m. she was still very sick; temperature subnormal, pulse regular and good, respiration at times laboured. Since early morning she had passed no water; the catheter showed the bladder to be empty. She was suffering so intensely that a hypodermic injection of morphia—gr. $\frac{1}{3}$—was given. At 9 p.m. she was seen along with Professor Stephenson. No urine had been passed, while her general condition was as before.

Labour had not begun; another injection of morphia—$\frac{1}{4}$ grain—given. She passed a fairly good night, but was very weak and unable to retain anything save a few sips of tea. She had occasional attacks of precordial pain. There was little change in her condition next morning. With the catheter a teaspoonful of urine was drawn off, but it was mixed with vaginal discharge and useless for

examination. It was observed that the hands and legs had become somewhat swollen.

True labour pains seem to have begun at noon, and at 4 p.m. she was delivered of a fœtus which had evidently been dead for some time. So rapid was the latter part of the expulsion and so severe the abdominal pain that the woman was unconscious of its birth. The placenta could not be expelled, and was removed under chloroform about an hour after. The pain was little if at all relieved by the emptying of the uterus. At the beginning of and during labour the temperature was 97°.

In the evening she was found much easier. She passed a good night, but any attempt to eat brought on vomiting and pain.

22nd.—The patient was very weak and unable to take nourishment; temperature 99°, pulse tolerably good. The catheter was twice passed during the day, but without result. Poultices were applied to the loins; pilocarpine was injected subcutaneously, as also later digitaline and strychnine. In the evening she seemed fairly well and comfortable, though still troubled with sickness.

23rd.—She passed a quiet night and slept a little. No urine was obtained during the day. At 10 p.m. she had what the nurse described as a rigor—probably a convulsion. Her temperature was found to be 97°, and in half an hour had fallen to 95°. When visited soon after by Dr. Gordon her breathing was laboured, her pupils contracted, and her appearance so alarming that he asked Dr. Stephenson to see her. Injections of saline solution into the rectum were added to the treatment previously employed.

24th.—During the night she was very restless, with severe precordial pain. She asked for and got a few sips of tea, which she retained. At 6 a.m. she gave vent to a loud shriek, and cried that she was choking, while her face became contorted. She was seen soon after, when the temperature was found to be 95°, the pulse regular and of moderate tension. No urine was obtained by the

catheter. At 11 a.m. inhalations of oxygen were tried, but she gradually became weaker and died at 3.45 p.m., suffering great precordial pain, and conscious to the last. No post-mortem examination was allowed.

Case 3.—*Partial suppression of urine in a primipara lasting for three days after labour two weeks before term, followed by polyuria and recovery; child alive.*

Mrs. N—, aged 19, was admitted to the Maternity Hospital on October 26th. She was advanced to within two weeks of the end of her first pregnancy. Previous to gestation she had always enjoyed good health. In the early months she suffered merely from the usual subjective symptoms, but at the beginning of the ninth month she was suddenly seized with sickness and vomiting, attended with severe headache and pain in the back. As during the next ten days she had frequent recurrence of these symptoms, she sent for her medical attendant, who advised her to go to the hospital.

On admission she was seen to be of average build and well nourished. Though neurotic in temperament she was not markedly so. There was no œdema. The catheter was passed, but only one half-ounce of urine was withdrawn, which became almost solid on boiling. Her temperature was 100°, her pulse 122. There was considerable tenderness in the left loin and over the left side of the uterus.

A few hours after admission labour spontaneously commenced, and dilatation proceeded rapidly, the first stage being completed in five hours. About an hour after, with the head lying on the pelvic floor, Dr. Stephenson applied the forceps under anæsthesia, on account of the condition of the woman and the urine, and completed delivery without trouble at 10.30 p.m. The child, a male, was alive, well nourished, and weighed 6½ lbs.

Soon after labour the woman began to suffer from sickness with persistent retching and vomiting. The pulse and temperature, as seen from the accompanying chart,

were subnormal, the pulse falling at midnight on the 27th to 48. No urine was voided within the first twenty-four hours. On passing the catheter only four ounces were obtained, which on boiling deposited $\frac{1}{3}$ albumen. The lochial discharge was normal in quantity. Poultices were applied to the lumbar regions every three hours, rectal injections of saline solution were ordered every four hours, and she was given by the mouth sips of very hot water and milk and potass, of which she took three pints in twenty-four hours.

28th.—During the whole twenty-four hours the temperature, which was taken four-hourly, never rose above 97°, and was occasionally as low as 96°. The pulse was also subnormal, being only 44 at 4 p.m. This marked depression of pulse and temperature is especially noteworthy. The vomiting and retching continued. During the day she took three pints of milk and potass and four pints of hot water in occasional sips. Only eight ounces of urine were obtained by catheter during this period. It contained $\frac{1}{3}$ albumen. Poultices and saline injections were continued; a mixture containing digitalis and strychnine was ordered, and for the vomiting a mustard leaf was applied to the epigastrium.

29th.—The condition was practically unchanged. There was marked apathy. The treatment was continued, and in addition two drachms of whisky were ordered every three hours, as well as $\frac{1}{2}$ oz. of Hendry's solution of salts every four hours, which produced free action of the bowels. By catheterisation 14 oz. of urine obtained, showing $\frac{1}{4}$ albumen.

30th.—Still apathetic and drowsy, but general condition improved. The temperature rose in the afternoon to nearly normal, while the pulse rate increased. Vomiting and retching less severe, so that she was able to take about eight pints of fluids—buttermilk, potass and milk, and hot water. Hendry's salts continued three times a day. She passed urine voluntarily throughout the day to the

amount of 47 oz., in which there was still $\frac{1}{6}$ albumen. Bowels acted freely; lochia normal.

31st.—Still depressed and drowsy; vomiting much less frequent and severe. Quantity of urine 100 oz. with $\frac{1}{10}$ albumen. Treatment as above.

Nov. 1st.—Continued improvement; little tendency to vomit; pulse 70, temperature normal, tongue furred, skin moist; complained of great thirst, though taking as much as eight pints of fluid on an average per day. The quantity of urine was 84½ oz. with $\frac{1}{10}$ albumen.

From this time the woman steadily improved. By November 4th, or the ninth day, the urine was free from albumen, and so continued till she was dismissed from the hospital on November 11th. She has since continued well.

The above case is interesting. The condition of the kidneys was probably similar to that in the other cases. She seems just to have escapsed eclampsia through the premature onset of labour, and, it may be surmised, complete anuria through artificial delivery under an anæsthetic.

Case 4.—*Uræmic poisoning following suppression of urine after labour.* (McCrea, 'Canada Lancet,' Toronto, 1884.)

On 17th October patient, a 3-para, delivered of a premature, eighth-month, stillborn child. On the following day she complained of severe pain in the lumbar region, for which ½ dr. Tinct. Opii in a starch enema was given. As no urine had been voided the catheter was passed, but the bladder found empty. In spite of treatment the anuria persisted. There was from the beginning troublesome vomiting, with, later, elevation of temperature and contraction of the pupils. The patient gradually became comatose, and died on the 27th—eleven days after the completion of labour.

Case 5.—*Suppression of urine following a normal but very rapid labour at term in a primipara.* (Williams, 'Lancet,' 1886.)

On March 24th, patient, aged 22, was delivered of a mature but stillborn child after a very rapid labour. On the same evening, save that she was very apathetic, she seemed to all appearance going on well. As on the following day no urine had been passed the catheter was used, but only three drops were obtained. Active treatment was instituted, but up to the fifth day only 5 oz. of urine were secreted, the anuria being accompanied by vomiting. On the evening of the fifth day death took place quite suddenly. There were no convulsions.

Case 6.—*Suppression of urine following premature labour at the seventh month; child stillborn.* (F. F. Bond, 'Lancet,' 1889.)

On the afternoon of January 9th Bond was called to see a woman—a 3-para aged 27—who had been delivered by a midwife at 2 a.m. the same morning of a premature, stillborn child. The labour was very rapid, and followed by rather severe hæmorrhage, which soon abated. She had passed no urine, but apart from occasional vomiting her condition was otherwise good. By the following day no urine had been passed, and with the catheter only a few drops were obtained. Under treatment the vomiting abated, but the anuria persisted, and there was intense pain over the loins. On the seventh day vomiting and retching returned; pulse and temperature were subnormal. Her condition became rapidly worse, and death occurred on the tenth day, being preceded by drowsiness with occasional delirium.

It is to be regretted that in not one of the cases was a post-mortem examination obtained. In endeavouring to explain the causation of the anuria we are thus compelled to rely on the clinical records, which, though sufficiently

full as to the symptoms accompanying the complication, are necessarily incomplete in respect to those, and to the condition of the kidneys and urine, which led up to it.

Though there is a general similarity in the features of the cases, it is more than probable that they were not all dependent on precisely the same cause, or, to put it more correctly (as the causation is undoubtedly of a complex nature), that the contributing factors were variously combined in the different cases.

It may assist in the elucidation of the causal problem if a comparison is made of the leading features of the cases, and attention drawn to the more striking points of resemblance. This I propose to do under the following headings :

1. *Age.*—The age is noted in five of the cases, and with one exception the patients were young women under thirty. In the case in which the age is not stated it may with probability be inferred from the number of her pregnancies that the woman was young. Assuming her age as thirty, we get an average age of twenty-six, an age at which it is unlikely that they were the subject of chronic Bright's disease, the possibility of which is further excluded by examination of the urine during pregnancy, and by the subsequent history in the cases which recovered.

2 *Puerperal history.*—Two of the patients were young primiparæ, two were pregnant for the second time, while one was in her third and one in her fourth pregnancy.

An inquiry into the history of the earlier pregnancies discloses several important facts which seem to have a bearing on the subsequent complication. In all the four multiparous women some abnormality, pointing to renal inadequacy, is found in the puerperal history. In Case 1 the first pregnancy terminated prematurely in the birth of a macerated fœtus. The urine was tested a few days before the onset of premature labour, and found to be nearly solid with albumen. In Case 2 the first pregnancy, though resulting in the birth of a living child, was accompanied with great sickness and prostration, while the two

following, during which the woman suffered even more acutely, terminated at the sixth month in the birth of dead children. In our fourth the condition of the woman is not noted, but while the first child was born alive the second was stillborn at the eighth month. The history of the sixth case is very similar, the first child being born alive, the second stillborn at the seventh month. The woman was subject to epileptic attacks, and was highly neurotic, a temperament which was specially noted in three of the other cases.

3. *History of present pregnancy.*—In two only of the cases were symptoms present of a severity to induce the patient to seek medical advice. In Case 3, that of partial suppression, the woman continued in excellent health till the beginning of the ninth month, when she was seized quite suddenly with sickness and vomiting, accompanied by severe headache and pain in the back. The urine, tested a few hours before the onset of labour, was almost solid with albumen. My own is the only other case in which the urine was examined during pregnancy. No symptoms were present, the woman expressing herself as in very good health, while the urine, tested on several occasions, was always found free from albumen.

In the other cases inquiry elicited nothing unusual in the course of pregnancy, and the patients seem not to have been seen by the medical attendant before labour.

It is a noteworthy fact that in one case only did the pregnancy continue to term. In this case the child, though stillborn, seems to have been recently dead. In three labour came on at the seventh month, in one at the eighth, while in the case of partial suppression labour was two weeks before term.

Equally striking, and of more importance in its bearing on the question of causation, is the mortality among the children. In the five labours which were followed by complete suppression the children were stillborn, and in two at least the fœtus had evidently been dead for some time. In all, the women were fourteen times pregnant,

and four times only did the pregnancy terminate in the birth of a living child.

In regard to the character of the labour there is a very important ætiological fact to be noted. In four of the cases of total suppression the labour was unusually rapid, if not precipitate. The importance of this will be referred to later. In the fifth case the duration is not mentioned.

Slight accidental hæmorrhage immediately preceded the onset of labour in two of the cases, in one of which it was accompanied by excruciating pain. In only one case was there hæmorrhage in excess of the normal amount after labour.

4. *Post-partum symptoms and character of urine.*—It is a well-known, but none the less remarkable fact that total suppression of urine may exist for several days without giving rise to any urgent symptom. This was strikingly illustrated in almost all our cases. So well, apparently, was the patient, and so free from symptoms, that it was with difficulty that the friends could be persuaded of the gravity of the condition. As a rule the woman expressed herself as comfortable and well. Pain in the back and headache, but not severe, were present in all save one, in which there was severe abdominal and precordial pain. The most uniform and striking symptom was vomiting. In my own case for the first few days, and in the second case all through, practically everything was rejected. In two of the cases there was well-marked depression of the pulse and temperature.

The later symptoms in the fatal cases were those that usually precede a fatal issue in suppression of urine—vomiting, drowsiness passing on to coma, muscular twitching, and contraction of the pupils. In two cases there were convulsions towards the close.

In regard to the urine, we find that in one only of the fatal cases was any obtained. One half-ounce was drawn off by catheter on the third day. It was pale, clear, and contained $\frac{1}{6}$ albumen. On the fourth day $1\frac{1}{2}$ oz. were obtained, with a sp. gr. of 1020, and showing blood and

hyaline casts and a "large quantity of spheroidal cells like renal epithelium." About two hours before death, which took place suddenly and unexpectedly on the fifth day, ½ oz. was spontaneously passed.

Of the two cases which recovered, it will be noted that in the first only 30½ oz. of urine were secreted during the first eight days. Save ½ oz. obtained by the catheter on the day following labour—and which was probably in the bladder during it—no urine was obtained till the fourth day, when 8½ oz. were passed after a saline injection into the rectum. This contained only ·01 per cent. of urea, a trace of albumen, and a few blood-corpuscles in the deposit. On the following day 4 oz. were passed with the following analysis:—sp. gr. 1016, urea ·6 per cent., albumen ·15 per cent., and still a few blood-cells. On the next three days 5½ oz., 12 oz., and 49 oz. were passed respectively, with an increase in the urea percentage and a diminution in the albumen. After this there was well-marked polyuria. Convalescence was slow, and the albumen did not entirely disappear for six weeks. In the second successful case the urine was solid with albumen a few hours before the onset of labour. During the first twenty-four hours after its completion none was voided, and with the catheter only 4 oz. were obtained, which on boiling deposited ⅓ albumen; on the next day 8 oz., with still ⅓ albumen; on the next 14 oz., with ¼ albumen; and on the following day 47 oz., and thereafter polyuria. By the ninth day the albumen had entirely disappeared, and from that time the woman made a very rapid recovery.

The re-establishment of the renal secretion in these two cases was preceded by a distinct amelioration in the sickness and vomiting, and this may, I think, be regarded as one of the earliest favourable signs.

5. *General conclusions.*—It will be observed that in all the cases of complete suppression, with the exception perhaps of Case 2, the symptoms conform to those usually ascribed to the obstructive form, the anuria extending over five to eleven days, and being unattended at the outset

with any urgent symptoms. Though Bond was of opinion that the complication was the result of the impaction of calculi in both ureters, there are facts in connection with the cases which make it very difficult to accept the view that they were instances of so-called obstructive anuria. In the case of partial suppression, for example, there was evidently a condition of the kidneys similar to that underlying eclampsia, and which brought the woman after labour to the brink of complete suppression ; but a stronger objection is furnished by the fact that in all five cases of complete suppression the children were not only stillborn, but in every instance save one were premature. It is obvious that there existed some cause which led to the death of the fœtus. In this cause we shall find the explanation of the suppression. McCrea was of opinion that the anuria was due to the absorption of decomposing matter in connection with the dead fœtus *in utero*, which he thought had given rise to blood-poisoning—a conclusion to which he held the symptoms strongly pointed. In no other case, however, is the fœtus described as decomposing. In my own it was fresh, and death was known to be recent, as movements had been felt on the previous day.

It is much more likely that the fœtal death and the post-partum anuria were dependent on a common cause. What this cause was can only be conjectured, but in all probability there was toxæmia from nephritis of a character similar to that which is now believed to produce eclampsia. That renal inadequacy existed before the occurrence of the last pregnancy is at once suggested by the puerperal history. In all the four multiparous women the previous labour resulted in the premature birth of a stillborn child.

It is unfortunate that in two of the cases only was the urine examined during pregnancy: in one, a secundipara, no albumen was found six weeks before labour, though in the previous pregnancy the urine contained a large quantity of albumen ; in the other the urine, tested a few hours before labour, became solid on boiling.

The whole puerperal history seems, then, to point to the existence of some defect in one or in both kidneys, which rendered them unequal to the increased strain of pregnancy, and exposed them during it to nephritis. But while the nephritis of pregnancy is common, and the condition of the kidneys which obtained in our cases probably not infrequent, complete suppression of urine after labour is very rare. In general, even in the most serious cases of nephritis which result in eclampsia, the activity of the kidneys is rapidly restored after the uterus has been emptied. In these complete suppression is rare, and in not one of our cases did convulsions precede suppression.

It is clear, then, that we must look for some other factor to explain the occurrence of anuria. That, I think, is to be found in the character of the labour. In five cases this is noted, and in all the labour was unusually rapid. In my own case it might fairly be described as precipitate. Though little danger is in general to be apprehended from undue rapidity of labour, yet in highly neurotic women it occasionally produces an unexpected degree of shock and collapse, more especially when it is the result, not of a diminished resistance, but of an undue severity of the pains. Having recently seen a case of this kind, I am the more inclined to believe that the pain and shock associated with precipitate labour constitute an important element in the causation. In discussing the ætiology of non-obstructive suppression Fagge* mentions that the shock accompanying rupture of the uterus may produce a temporary anuria, which passes off as the patient recovers. It is probable that he had in view an actual case, but no reference is given, and I can nowhere find record of such a case.

It is only in nervous, high-strung women that undue rapidity of labour is liable to occasion alarming symptoms, and there can be no doubt that a neurotic temperament plays a considerable part in the production of anuria fol-

* 'Principles and Practice of Medicine,' vol. ii, p. 669, 2nd edit.

lowing labour. In four of the cases the women were expressly stated to be neurotic.

It should be observed that in Case 2 suppression seems to have preceded the onset of labour, but here the woman suffered both before and during labour from intense pain, which was probably the immediate cause of the suspension of the renal function.

In the absence of post-mortem evidence the causation must still be regarded as obscure. While this is so, the following would seem, from an analysis of the clinical conditions present, to be the more important factors concerned in the production of post-partum anuria.

(1) A pathological condition of the kidneys—probably nephritis—resulting from pregnancy, but in some cases dependent on a pre-existing defect of the organs, congenital or acquired.

(2) A neurotic temperament: the influence of this on the renal secretion is seen in hysterical suppression.

(3) The shock incident to an undue rapidity of labour, or arising from excessive pain. This seems in all the cases to have been the exciting cause.

The treatment of suppression of urine after labour does not differ in any way from that to be followed in the same condition apart from pregnancy, and is so fully described in text-books of medicine that it need not be further discussed. Attention may, however, be called to one or two points suggested by a perusal of the cases.

It is very important that efforts to restore the function of the kidneys, and to supplement them till that is accomplished by increasing the activity of the accessory channels of excretion, should be instituted *without delay*. In almost all the cases much valuable time was lost through failure to immediately realise the gravity of the condition. Whether the result would have been different if energetic treatment had been resorted to earlier it is impossible to say. As an addition to the measures usually recommended, the injection of saline solution into the rectum will be found useful. It proved the most effective remedy in my

own case, though it was tried by Dr. Gordon without success.

Another interesting and important point arises in connection with the use of opium. In all the fatal cases save one it was given, chiefly for the relief of abdominal or lumbar pain, and it becomes a question whether it had any detrimental influence on the kidney secretion, and was in reality a factor in the production of suppression. Did it in any way interfere with the restoration of the renal function? While admitting the possibility, I am disposed to think that it did not, for the reason that in one of the fatal cases opium was not given; and further, that morphia does not produce this effect in cases of eclampsia, in which probably the condition of the kidneys is very similar. At the same time I am of opinion that opium should be rigidly withheld in cases in which anuria is to be feared.

Dr. Boxall said that he had never met with a case of *complete* suppression of urine after delivery, and thought all would agree with the authors that it is of extremely rare occurrence. But within the last year he had met with two cases of *partial* suppression, both terminating fatally, one four days after a labour, which took place a week before the full time, and the other a fortnight after a five months' miscarriage. The features of the illness in each case presented much in common. In neither case were the symptoms till shortly before death such as to draw special attention to the exceedingly grave condition of the patient.

The first case was that of a lady about thirty years of age. She had had two miscarriages previously when about three or four months advanced in pregnancy. For neither of the miscarriages could any special reason be suggested. He learnt subsequently from the doctor who attended her in the first of these about eighteen months previously that the urine then contained albumen in considerable quantity. The last miscarriage was followed by an attack of sepsis and excessive loss, for which the uterus was curetted.

In the last pregnancy a slight and transitory loss occurred when she was two months gone. She first came under his observation when she was four and a half months pregnant. At that time, and again when he saw her six weeks later, the uterus felt unusually bulged to the left side as if by a fibroid; but six weeks later still this bulging was no longer apparent. She was a very well-developed and well-nourished woman, of

somewhat excitable temperament, who apparently had enjoyed good health. But during the pregnancy she had been troubled by an irritable cough and disturbed sleep, and suffered from repeated gastric attacks.

The labour was rather severe, the membranes having ruptured prematurely a week before the full time and forty-eight hours before the pains began. For two hours before the completion of the first stage the pains were severe and almost continuous. Dr. Boxall found, on his arrival, the patient kneeling up on all-fours with the idea of obtaining relief. The head was just beginning to pass through the cervix and to descend into the pelvis. Chloroform was administered during the pains. The head slowly descended. During the last half-hour of the second stage (which lasted two and a half hours) the pains began to flag, and the patient was becoming exhausted; but, just as forceps were about to be applied, delivery took place. The placenta was expressed one and a half hours after. No evidence of the fibroid which had been thought to exist could then be felt. The child's head had undergone considerable moulding. Artificial respiration had to be resorted to for about five minutes. The infant had slight fits and convulsive movements for nearly a month subsequently, but since then has made good progress.

Towards the end of labour and for some hours afterwards the patient was sick, and brought up a quantity of brownish fluid. Everything given by the mouth, even hot water out of a teaspoon, was rejected. As the patient was rather exhausted, rectal feeding was at once resorted to. The pulse was 80, beyond which point it never sank, and was of fair volume.

About eight hours after labour the patient passed two ounces of urine naturally. Twenty-six hours after labour, as no more urine had been subsequently passed, the catheter was used, and five ounces of urine were drawn off. This urine was dark in colour, and on examination proved to contain two fifths albumen. No casts or blood were found under the microscope. Hot fomentations were at once applied to the loins. At this time a distinct icteric tint of the conjunctivæ was noticeable; but this passed off in a day or two.

Eighteen hours after delivery the sickness entirely ceased, and six hours later feeding by the mouth was recommenced. On passing the catheter the bladder was found to contain two ounces of urine only, and this deposited half albumen.

Thirty-three hours after delivery the sickness returned, but there was no headache and no drowsiness, and the merest trace of pitting of the legs on firm pressure. There was slight backache till the fomentation was applied, but no special complaint was made even of this. Rectal injections of saline fluid were also given in order to induce the kidneys to act, but without

effect. In the next twenty-four hours three ounces of urine only could be obtained. The amount of albumen, however, had fallen to one thirtieth. A few casts were found under the microscope. The hot pack produced little or no sweating.

Eighty-one hours after labour twitching in the fingers was first observed. A hot air bath was then given, and produced a copious perspiration, but still not more than two ounces of urine could be obtained in the next twenty-four hours. The albumen, however, had further diminished. The patient was at that time able to take liquid nourishment by mouth, and was fully conscious. She slept for some hours.

The temperature, which had hitherto been normal to subnormal, then, on the evening of the third day, began to rise, and during the night reached 105°; the face became dusky, the breathing laboured, and consciousness was lost. Bleeding to the extent of forty ounces with subsequent transfusion of saline fluid into the vein produced but slight and transitory improvement. The coma deepened, and eight hours from the time that consciousness was lost, the patient had one slight convulsion and died. The temperature taken one hour after death was 108·6°.

It may be noted that in this case there was never complete suppression of urine, but that from the time of labour till death, four days and two hours after, not more than fourteen ounces were secreted. The vomiting, which at first was looked upon as, and probably was like that during the pregnancy, gastric in character, subsided, and then returned. Apart from the vomiting no urgent symptoms were present till eight hours before death, though slight twitchings were observed twenty hours earlier. Had it not been that the urine was examined soon after labour, the exact nature of the illness might have passed unrecognised till the day before it terminated fatally. In this case certainly no time was lost in applying active remedial measures, but unfortunately they all failed to re-establish the functions of the kidneys.

The second case occurred in a young and well-developed and well-nourished woman, who had not been pregnant before. The miscarriage, which took place when she was five months pregnant, may have been assisted by her having taken large doses of tincture of gossypium, and by a Turkish bath followed by a chill on the day prior to the miscarriage, and possibly also by mechanical means. The membranes were retained, and were removed by the introduction of two fingers into the uterus. A sublimate douche was subsequently given.

Vomiting commenced at the time of the miscarriage, and was very persistent. Next day the conjunctivæ were distinctly jaundiced, and remained so for a week.

Dr. Boxall was called to see her in consultation eleven days

after the miscarriage had taken place. The temperature was 98°, the pulse 48, dicrotic and rather feeble. But the patient, in spite of the persistent vomiting, appeared to be by no means seriously ill. She complained of the distress caused by the sickness, and of pain in the region of the gall-bladder. The urine up to that time had not been tested, and no specimen could then be obtained, but from inquiries made it seems that nothing unusual had been noticed. The bowels had been relieved by a calomel purge, and had been kept open by enemata. Among the numerous remedies tried nothing had been found to check the sickness. Rectal feeding was suggested.

Two days later the patient became rapidly worse. But little urine was passed, and on being tested was found to contain some albumen and blood and a few casts. The vomiting was incessant, the pulse continued slow, and the temperature subnormal. A semi-comatose condition supervened, in which the patient died sixteen days after the miscarriage.

On post-mortem examination the liver was found to be paler and softer than natural, and the kidneys were enlarged, very much congested, and showed evidence of old-standing disease of moderate degree, and also of recent acute inflammatory softening. There was some excess of fluid (slightly blood-stained) in the peritoneal, pleural, and pericardial cavities. Distinct indications of some blunt-pointed instrument having been passed into the cervix of the uterus were present, but whether before or subsequent to the miscarriage could not be determined.

On the only occasion on which Dr. Boxall saw this patient during life there was no headache, drowsiness, backache, or œdema, and as far as could then be made out the urine was passed in sufficient quantity. There were reasons for regarding the vomiting as gastric in character, and he quite failed to recognise the grave condition of the illness. Nor does it appear, when two days later the patient was taken worse, and the condition of the urine was known, that the grave condition of the kidneys was recognised, or that any active measures were adopted with a view to combat the renal inadequacy.

Both these cases went to show that a grave condition of the kidneys might exist with little beyond the persistent vomiting to indicate the danger till shortly before death. The first case, in which saline injections both into the rectum and into the veins were included among the measures early adopted and actively persisted in, showed how slight was the hope of re-establishing the functions of the kidney in such cases.

Dr. W. H. Tate then reported the following case of anuria following labour:

Mrs. S—, aged 22, was confined of her first child on 16th April, 1899. The confinement was quite normal. The presentation was second vertex; there was no rupture of the perinæum,

and the third stage of labour was completed without any difficulty.

During the first week the patient's condition was quite satisfactory, with the exception that on one or two occasions the temperature was slightly raised.

On the 23rd April, while having a vaginal douche, patient had a shivering attack, and temperature rose to 102·5°. She felt faint and vomited. On the same day she complained of sore throat. On the following day temperature had fallen to normal, but she vomited four times during the day.

At 6 a.m. on the 25th she began to hiccough, and this troublesome symptom continued until death. There was also some diarrhœa. The lochia appeared to be healthy and free from odour. The amount of urine passed was first observed to be below the normal on this day, but was not thought to be of serious import, as the diminished secretion was explained by the vomiting which occurred twice on the 25th.

On the 26th patient's condition was about the same. The hiccough continued as a severe and distressing symptom, and Dr. Cullingworth was called in to see the patient in consultation with Dr. Smith of Streatham. At his visit he found the patient looking very anæmic and weak, but not alarmingly ill. The tongue was furred. There was ulceration of the tonsils. There was no abdominal distension nor any tenderness. Patient was put under chloroform, and the interior of the uterus explored. A quantity of ill-smelling placental tissue, morbidly adherent, was removed with considerable difficulty. The patient was noticed to pass a little urine while under the anæsthetic. At 8 p.m. temperature was 98·4°. After the operation the hiccough continued as before, but no urine was passed. A catheter was passed, but the bladder was found to be empty.

On the 27th temperature was subnormal, 97·8°. The tongue was cleaner, and the discharge free from odour.

On the 28th April, as the hiccough continued Dr. Tate went down to see the patient for Dr. Cullingworth. No urine had been passed. The temperature was subnormal. The condition of the throat, which had been sloughy, had improved. The patient was very weak and anæmic, but was able to answer questions. The uterus contained a firm clot, which was easily removed. No urine at all had been passed since Dr. Cullingworth's visit on the 26th, in spite of administration of diuretics, champagne, fomentation to the loins, etc. Patient died suddenly at 6.30 p.m. on the same day. She complained of sudden pain over the heart, and died before the nurse could get to the bedside.

Dr. Tate also referred to a very remarkable case reported by Bradford and Lawrence in the 'Journal of Pathology and

Bacteriology' in May, 1898. The patient, a married woman who had had six children, was delivered of a stillborn child on February 28th, 1896. She was sick after the confinement was over, and suffered from headache and slight drowsiness. She said she passed no urine from the time of her confinement till March 2nd, when two drachms were drawn off. She was admitted to University College Hospital on March 3rd, complaining of inability to pass water. She had no fits or twitchings. On admission she was very weak and anæmic. Mucous membrane almost colourless. Temp. 98·6°; pulse 88. No œdema. Slightly drowsy, but quite conscious when spoken to and rational. On March 4th 1½ drachms of urine were drawn off. Temperature was 97·8° and pulse 100. She gradually got weaker on March 5th, 6th, and 7th. The temperature was subnormal, varying from 96·4° to 95·4°, and she died suddenly on March 7th, half an hour after having a hot air bath. At the autopsy there was found to be complete necrosis of nearly the whole cortex of both kidneys. There was wide-spread endarteritis of the interlobular arteries, which were thrombosed, and had caused necrosis of the convoluted tubules throughout the cortex.

Dr. W. S. A. Griffith said that there appeared to be two classes of puerperal cases of suppression of urine: one the common case of acute nephritis, with or without eclampsia; the other, very rare, quite unconnected with this disease. He had seen one of the latter some years ago at Blackheath, a primipara quite clear in her mind, without headache or uræmic symptoms, with complete suppression of urine, who survived about five days, and the treatment adopted failed completely. His recollection of the case was that it was a complication of acute septicæmia.

Dr. W. Murray Leslie said he could recall three cases, where, however, the anuria did not prove complete, though the daily amount of urine voided was in excessively small quantities and loaded with albumen, and in each of these cases the main factor in setting up the condition proved to be alcohol. The first case seen in consultation had a long history of indulgence, and ended fatally after a fortnight with uræmic symptoms. The other two cases, in private practice—primiparæ,—recovered. These two latter patients had never previously been suspected of alcoholism, and one had only acquired the habit during the pregnancy. The kidneys were not examined, as post-mortems were not obtainable. He emphasised the importance of regular examination of the urine at intervals during the latter part of a pregnancy, and of dealing firmly with the question of alcohol should any trace of albumen be found to be present.

APRIL 2ND, 1902.

PETER HORROCKS, M.D., President, in the Chair.

Present—35 Fellows.

Books were presented by the American Gynecological Society, Société de Médecine de Rouen, Mr. Bland-Sutton, Boston (U.S.A.) Lying-in Hospital Staff, Gesellschaft für Natur- und Heilkunde in Dresden, and the Organising Council of the British Congress on Tuberculosis.

Evan James Trevor Jones, M.D. (Aberdare), was declared admitted.

The following candidates were proposed for election :— Arthur Raymond Stilwell Freeland, M.R.C.S., L.R.C.P. ; Ernest Wool Lewis, M.R.C.S., L.R.C.P.

The following candidates were elected Fellows :— Mary Ann Dacomb Scharlieb, M.D.Lond., M.S., B.S. ; Ada Margaret Browne, L.S.A. ; Alfred James Rice Oxley, M.D. ; Florence Nightingale Boyd, L.R.C.P. and S.I., M.D.Brux.

UNILOCULAR OVARIAN CYST CONTAINING SOLID MASSES UNDERGOING NECROTIC CHANGE.

By J. S. Fairbairn, M.D.

This specimen appears to be of interest from the unusual character of the solid masses growing in its wall, and from the fact that they are largely necrotic and full of effused blood, while the cyst was sessile and without any evidence of strangulation. It is a unilocular cyst with a rough outer surface, and without any pedicle or recognisable anatomical structure. In one part of its wall, equal in area to about a quarter of its entire circumference, is a dense solid mass, and on looking into the interior of the cyst this is seen to present several large bosses—the largest about the size of a hen's egg,—not unlike the solid masses of adenomatous growth frequently seen in the ordinary multilocular cyst, but much harder and firmer. The two most prominent masses are of a deep purple colour, like that of a strangulated cyst, and on section are either solid, or solid with a few small cystic spaces. No glairy mucoid fluid exuded from their cut surface when they were first cut.

As these solid masses form the chief feature of the specimen, they merit a detailed description.

1. The main mass in the thickness of the cyst wall measures 5 × 4 × 1¼ inches. Its surface is reddish white, mottled, and crossed by thick strands which run over its surface, and divide into branching septa. It is covered with a smooth shiny layer, apparently continuous with that lining the rest of the cyst. On section it is quite solid, and of a deep red colour, as if full of blood ; when fresh it had the appearance of liver in some places, and in others was pinkish white like fibromatous tissue.

2. Arising from this mass are rounded bosses of a deep plum-colour, with a slightly wrinkled surface. The largest measures $3\frac{1}{4} \times 2\frac{1}{4}$ inches. On section the dark purple colour is found to be confined to the superficial zone, the deeper parts are yellowish white and firm, and when fresh contained a good deal of fluid, which could be expressed from it by pressure. The next in size is $2\frac{1}{2} \times 1$ inch; it is exactly similar to the first, except that the dark purple colour extends somewhat more deeply. The other nodules are much smaller than these two. They are all evidently necrotic.

3. A mass about the size of a Tangerine orange, which, when fresh, had the same pinkish-white colour as the rest of the cyst. On section it has the appearance of fibromatous tissue undergoing myxomatous and cystic degeneration; it is solid, with many small cystic spaces. There are other small nodules like this, some of which are covered with warty excrescences.

There is no evidence of necrosis of, or of hæmorrhage into, the cyst wall.

Some portions of its peritoneal covering were removed with the cyst, and among them is a portion of broad ligament with its two layers intact, and containing a small portion of Fallopian tube. There was also a small calcareous plaque, which was found embedded in the layers of the adventitious capsule, and a small simple cyst from the ovary of the other side.

Microscopically the growth is an epithelial one of an adenomatous type, with a distinctly papilliferous arrangement in places. It shows the usual cystic spaces lined with a columnar epithelium. Large portions of it are necrosed, and do not take up any nuclear stain. This tissue here is seen to be engorged with blood, and to contain large spaces filled with blood-corpuscles. In the parts bordering on the necrotic areas the epithelium has proliferated, and is collected in rounded masses like cell-nests in the centre of the space, in many of them completely detached from the wall.

The extensive necrosis of the solid masses is difficult to understand; it may possibly be due to the calcification at the base of the cyst interfering with the blood-supply.

The cyst was removed by Dr. Fenton from a patient in the Chelsea Hospital for Women. The patient was a widow of 65, who had been married twenty-five years, but had never been pregnant. She was admitted for swelling of the abdomen, noticed for three or four years, and frequency of micturition. For two months the increase in size of the abdomen had been much more rapid, and with it some swelling of the feet and ankles had been noticed after walking. The menopause had occurred at fifty-three; the general health had been good.

On examination of the abdomen a large cystic mass was found, extending from the pelvis up into the epigastric region. It was dull to percussion, fluctuated, and gave a fluid thrill. *Per vaginam* the uterus was pushed down by the cyst, and lay to the front and left.

On opening the abdomen the cyst was found to have raised up the broad ligament, and appeared to rise from the right side. There was one big cyst with several smaller ones around it.* The large one was aspirated, and about ten pints of dark fluid drawn off. It was then enucleated from underneath the broad ligament, to which it was adherent; no pedicle was found, though some of the adhesions in the lower part of the pelvis required ligature. Some calcareous plaques were noticed at the base of the cyst. The enucleation was very difficult, and neither the uterus nor the other ovary was identified owing to the matted state of the surrounding parts. The abdomen was closed, leaving a drain into the cavity from which the tumour had been separated. Except for troublesome vomiting, which persisted for some days, the patient made a good recovery, and at the present time—eighteen

* When the specimen was examined after the operation it was found to consist of one cyst only.

months after the operation—is in excellent health, though a small sinus still remains in the drainage track.

SMALL FIBROMA UTERI SHOWING SARCOMATOUS CHANGES.

By Munro Kerr, M.D., Glasgow.

This specimen was removed from a married lady of forty-five. As can be seen, it consists of a uterus with a round smooth tumour situated at the left cornu. She complained of great bleeding of six months' duration. She stated also that she had lost flesh and was unfit for the least exertion.

Prior to her present illness she had always enjoyed excellent health. She had had ten of a family, and all the labours and puerperia had been uncomplicated.

The uterus was explored and a small portion of the tumour removed, when on examination it was reported by a pathologist to show evidences of malignancy. The author also examined the sections and agreed with the pathologist. It was considered, therefore, best to remove the whole uterus. This was done without difficulty, and the patient made an excellent recovery.

On sectioning a portion of the tumour for microscopic examination, it presented the appearances of a fibro-myoma. Under the low power and high power muscle-fibres on cross and longitudinal sections are found. In addition, however, there are groups of cells throughout the tumour which are not cross-sections of muscle-fibres. These are considered evidence of a sarcomatous change having occurred in the tumour.

FIBRO-MYOMA OF THE VAGINA.

By Munro Kerr, M.D., Glasgow.

This small tumour was removed by operation from an unmarried lady of about twenty-five. She complained of extreme dysmenorrhœa of many years' duration.

On vaginal examination a hard solid swelling could be felt in the anterior vaginal wall at about the junction of the middle with the upper third. It was quite distinct from the uterus, although it felt at first very like an extremely anteflexed fundus. A few days later the tumour was enucleated without the least difficulty. The wound was then stitched up with catgut.

On examining the tumour microscopically it was found to present features of the ordinary fibro-myoma.

The specimen is shown because of its rarity. The latest monograph in English on the subject is by Smith in the February number of the American 'Journal of Obstetrics and Gynecology.' The author of that paper has collected a hundred odd cases from the literature of different countries.

The specimen was referred to the Pathological Committee.

Report of the Pathological Committee on Dr. Munro Kerr's Specimen of Tumour of the Uterus.

We, the undersigned, have met this day, and, after examining the specimen named above, have drawn up and signed the following report.

The tumour is a submucous fibro-myoma showing hyaline degeneration. There are cystic spaces in different parts of the tumour lined with normal columnar epithelium, which we consider are derived from the endometrium.

We can find no evidence of sarcomatous change in the tumour.

G. F. Blacker.
J. S. Fairbairn.
G. Bellingham Smith.
Cuthbert Lockyer.
Corrie Keep.
Alban Doran, *Chairman.*

April 17th, 1902.

FALLOPIAN TUBE RUPTURED TOWARDS ITS FIMBRIATED END IN TWO PLACES.

By Amand Routh, M.D.

The patient was a married multipara aged 25, whose last period was January 10th to 14th, 1902. On February 28th patient had pelvic pain in abdomen, and fainted as she was rather apt to do, and next day she sent for Dr. Muir, of New Cross Road. Dr. Muir suspected a threatened abortion. March 2nd. There was a slight show. March 4th. Severe continuous vomiting with abdominal pain and tendency to faint; pulse and temperature normal. March 12th. Dr. Muir received urgent message, and found that patient's bowels had acted very freely at 5 p.m. with violent vomiting and she then fainted. Dr. Muir found her with pulse of 160, barely perceptible, but after strychnine hypodermically rallied, and complained of severe abdominal pain. Dr. Muir diagnosed ruptured tubal gestation, and wrote to Dr. Routh at 10.30 p.m. asking him to call next day, as she had already improved, and her pulse had diminished to 120. Dr. Routh saw her with Dr. Muir at 3 p.m. on March 13th, and found her

distinctly worse than she had been a few hours previously, and it was decided to operate at once.

At the operation the abdomen was full of blood; the ovum in its intact membranes was found to be adherent to the edge of a rupture on the posterior aspect of the right Fallopian tube near the fimbriated end. The tube was ligatured off and removed, and was then found to be ruptured both anteriorly and posteriorly. The patient rallied well. During the operation the abdomen was twice filled with saline solution, and two pints of saline solution were also given immediately after the operation *per rectum*, and she convalesced without further complication.

Report on Specimen.

The specimen consists of two separate parts; (1) the ruptured tube, (2) the extruded ovum.

The tube measures 7 cm. in its long axis. At the cut uterine extremity it is normal in size for 1 cm. of its length, but its lumen is impervious. One cm. from the cut end the tube widens out into a thin-walled sac, the distension reaching as far as the fimbriæ, which appear as so many finger-like processes proceeding from the sac; the abdominal ostium having been closed is no longer traceable.

The tubal gestation sac measures 6 cm. in length by 2·5 cm. in width through its greatest diameter. The sac tapers at either extremity, being more or less fusiform in shape. The walls of the sac have ruptured both anteriorly and posteriorly; the one tear in the distended condition measuring 1 × 2 cm., the other being 2 × 2 cm. in extent. Both tears proceed to within 2 cm. of the fimbriated extremity of the tube. At its uterine extremity the sac is occupied by a solid irregular mass which appears to be blood-clot on section, and which corresponds to a similar clot seen to occupy one pole of the ovum. The walls of

the sac are, for the most part, so thinned out as to resemble parchment, but the part to which the clot is attached is several lines in thickness, and is intimately incorporated with the adherent contents.

The ovum is circular, with a diameter of 3 cm. Externally it is invested with a villous covering. On section, an embryo measuring 2 cm. in the flexed position is seen to occupy the amniotic cavity. At one pole of the ovum is a large hæmorrhagic area, which corresponds to that mentioned above as seen at the uterine end of the saccular and ruptured tube.

CUTHBERT LOCKYER.

TUBAL MOLE REMOVED BY COLPOTOMY.

By F. J. McCANN, M.D., F.R.C.S.

An anæmic-looking woman, aged 35 years, was admitted into the Samaritan Hospital under my care in October, 1901.

She had had one child born four years ago, but no miscarriages.

On August 8th, 1901, having missed her period for six weeks, she had severe bleeding from the vagina, blood and clots being passed. "A piece of flesh," described as being the size of the palm of her hand, was observed in the vaginal discharge. Previous to this attack she had noticed that her breasts were painful, and she had morning vomiting. While the hæmorrhage continued she suffered considerable pain, which persisted for some days. The pain was situated in the left iliac region, and was so severe that it caused her to faint on three occasions.

The pain existed at intervals until her admission. A discharge of bright blood continued to issue from the vagina, and was present when she was first seen by me. The breasts were stated to have become smaller, and the pain in them had subsided.

A lump had been detected to the left side of the uterus on September 12th, and enlargement of the womb also noted. This lump was observed to have become smaller on October 6th.

On examination.—An elongated movable swelling was palpable on the left side of the uterus, occupying the left posterior quarter of the pelvis. The uterus was slightly enlarged. The patient was kept in bed under observation for a few days. During this time the discharge of blood continued, but had become darker in colour; the pain in the left iliac region persisted, and the swelling was noted to have increased in size.

A diagnosis of tubal mole was made and operation advised.

Operation.—Owing to the position and relations of the swelling the vaginal route was chosen. The posterior vaginal cul-de-sac was incised and the peritoneum opened. The fingers were inserted into Douglas's pouch and the swelling drawn downwards. It was punctured with a trocar, and some dark blood evacuated. The left ovary, which was cystic, was also punctured. The tube and ovary were then pulled into the vagina. A pair of medium-sized Spencer Wells' forceps was placed on the pedicle, and the tumour separated with scissors.

A hydrosalpinx was found on the right side. It was punctured, ligatured, and removed. The forceps were left *in situ*, and a strip of iodoform inserted for drainage. The operation lasted fifteen minutes. The gauze and forceps were removed at the end of twenty-four hours. The patient recovered, and remains well.

The specimen was kindly prepared and mounted by my colleague, Dr. Cuthbert Lockyer, who has furnished the following report:

The specimen as mounted consists of the left Fallopian tube, the mesosalpinx, and the left ovary.

The tube measures from the cut uterine end to the closed ampullary extremity, seven centimetres.

The proximal undilated portion of the tube is bent upon itself in the form of the letter S; the lumen is patent to a bristle, except at the convexities; the walls of this portion of the tube are somewhat thickened, and on section the tubal mucous membrane is also thickened, rosy red in colour and spongy; the blood-clot extends into the lumen of this bent and apparently undilated portion to within two centimetres of the cut end, there being no abrupt termination of the gestation sac visible to the naked eye towards the uterine extremity of the tube. The mole occupied the outer part of the tube to the extent of five centimetres. It is thickest at its central point, where its diameter measures two centimetres, whilst tapering towards the cut end of the tube it ends obtusely at the closed abdominal ostium, where there is evidence of a slight escape of blood, as the fimbriæ are enveloped in a small blood-clot the size of a horse-bean, adherent to the outer wall of the tube. Half a centimetre from the closed ostium there is seen on section a thin-walled partition dividing the blood-clot into two portions. This partition appears to be derived from the tube wall itself, and exists only in the anterior half of the lumen, so that posteriorly the blood-clot is seen on section to be continuous from its one extremity to the other. This partial division of the tube by a septum close to the fimbriated end has been previously noted (cf. Dr. Routh's Specimen of Tubal Abortion and Rupture, 'Trans. Obstet. Soc. Lond.,' 1902).

The ovary measures five by three centimetres, and is reduced to the condition of a thin-walled cyst in its upper two-thirds.

The thickened musculature of the undilated end of the tube suggests the presence of inflammatory changes prior to the event of tubal pregnancy, a suggestion which was further supported by obvious inflammatory change

discovered in the opposite adnexa at the time of the operation.

Chorionic villi were observed in microscopic sections from the tubal wall.

Dr. McCann stated, in reply to some remarks made in discussion, that as the method of forcipressure for large arteries was still more or less in the experimental stage it was difficult to make definite statements as to the length of time required for the application of the compressing force. From his own experience he had found that the application of a medium-sized pair of Spencer Wells's forceps for twenty-four hours sufficed for the ovarian artery. Probably even a shorter period would serve. After thirty-six hours or more one would expect hæmorrhage, for in all probability the compressed portion would have sloughed or be in process of separation. For the uterine artery, as in cases of vaginal hysterectomy, thirty-six to forty-eight hours appeared to be necessary. Where the forceps employed are rendered aseptic, and the methods of the operator conducted with due regard to asepsis, the slough, if any would occur, would be free from sepsis. In the case under discussion there was no rise of temperature after the operation, and the uterus and remaining appendages were freely movable when the patient was sent home. Colpotomy was chosen in this patient's case because the swelling was felt to be low down in Douglas's pouch. The operation was conducted with the pelvis raised, for in this position the ovaries and tubes are much more accessible when approached through a vaginal incision.

SQUAMOUS CARCINOMA OF THE CERVIX UTERI.

By F. J. McCann, M.D., F.R.C.S.Eng.

The patient from whom this specimen was removed was 39 years of age.

She was admitted into the Samaritan Hospital on March

18th, 1901, complaining of a discharge of blood from the vagina. This discharge had existed for nine weeks.

She had had eleven children, the youngest being four and a half years of age. Previous to the onset of the hæmorrhagic discharge her menstrual periods had been regular, lasting three days, the quantity being small. For six months she stated that she had been losing flesh.

On bimanual examination a rounded growth was felt springing from the posterior lip of the cervix uteri. The surface of the growth was covered by a series of small projections. It was very vascular, bleeding freely when touched. The uterus was movable.

On March 20th the uterus was removed by vaginal hysterectomy, together with a small ovarian cyst (left side). The patient recovered and has remained well.

The specimen appears to be an example of the "infiltrating type" of cancer of the vaginal portion described by German pathologists. The posterior lip is expanded to about the size of a Tangerine orange. The mucous membrane covering its vaginal and cervical aspects is intact. The anterior lip of the cervix is free from disease.

Microscopically the growth is a squamous-celled carcinoma. Sections show typical cell-nests.

A CASE OF CONGENITAL PROLAPSE OF THE UTERUS ASSOCIATED WITH SPINA BIFIDA.

By H. Russell Andrews, M.D.

The pelvic organs were shown, together with a photograph taken after death, and two drawings made during life.

The infant was in the London Hospital, under the care

of Mr. F. S. Eve, who had kindly given Dr. Andrews permission to report the case. The child was one of a family of five. The other four children were well-formed and healthy. There were no malformations among the parents' relations.

The child was eleven days old when admitted into the hospital. It appeared to be full-time, and weighed 7 lbs. 1 oz. It was hydrocephalic. There was wide separation of the two halves of the frontal bone, and marked protrusion of the fore-part of the head. The shape of the head was rather suggestive of the moulding after brow presentation.

There was a spina bifida in the lumbosacral region, the sac, which measured rather over three inches in length and two inches in breadth, being covered partly by skin and partly by a semi-transparent membrane. There was a well-marked post-anal dimple.

The cervix uteri projected about one inch from the vulva; it was not much congested. There was slight superficial ulceration of the vaginal portion. A little mucus was hanging out of the cervical canal. The prolapsed inverted vaginal walls were healthy, not much congested.

The uterus was retroverted. A bougie entered 1⅝ inches. The uterus could be easily pushed up, so that the cervix was high up in the vagina, but came down again when the child cried. When the uterus was pushed up the hymen could be seen as a loose fringe at the posterior part of the vaginal orifice. The orifice of the urethra was a small slit on the right side of a thin-walled tense cyst, the size of a small grape, which appeared to bulge from the left side of the urethra. The anus was rather patulous, but there was no protrusion of the rectal mucous membrane. The child had no difficulty with micturition or defæcation. The legs and thighs were paretic, but not completely paralysed. No reflexes could be obtained.

There was no talipes. The great toe of each foot

was in the position of hallux valgus, and was slightly "hammer"-shaped. Babinski's sign could not be obtained. The prolapse first appeared two hours after birth, when the child was crying vigorously.

The thin membranous covering of the spina bifida gave way on the twelfth day, and the infant died three days later of meningitis with pyrexia and convulsions.

Post-mortem examination.—Meningo-myelocele, filled with thick pus; general purulent cerebro-spinal meningitis. The greatly dilated lateral ventricles contained sero-purulent fluid. The foramen ovale was patent. The sigmoid flexure dipped deeply down into the pelvis, and the rectum seemed to be abnormally loosely attached. The supra-vaginal cervix was somewhat elongated, but the cavity of the cervix was not much longer than that of the body. The uterine ligaments were very lax.

Congenital prolapse of the uterus is a very rare condition. This is apparently the twelfth recorded case. In vol. xlii of the 'Obstet. Soc. Trans.,' p. 169, Dr. Andrews recorded a case which was under the care of Dr. Herman in the London Hospital, and quoted nine other cases. To these must be added—

11. A case recorded by Hanssen ('Münch. med. Woch.,' 1897, p. 1040), also associated with spina bifida. The spina bifida was operated on soon after the birth of the child. The prolapse appeared on the second day. The child died on the ninth day. The post-mortem examination revealed nothing of importance.

12. The present case.

In at least nine, possibly ten of these twelve cases there was also spina bifida.

In the four cases which have been described since Ballantyne and Thomson's paper in the 'American Journal of Obstetrics,' vol. xxxv, p. 161, *i. e.* the cases of Radwansky and Hanssen and the two cases which Dr. Andrews has recorded, the following points may be noted :

1. In only two cases was there also spina bifida. In one of these, No. 12, there was paresis of the legs.

2. In one case, No. 10, there was increased intra-abdominal pressure, but no spina bifida. When this pressure, due to imperforate rectum, had been relieved by colotomy, the uterus remained in its normal position.

3. In one case, No. 9, the prolapse was present at birth. In two cases the prolapse appeared a few hours after birth. In the remaining case the prolapse appeared on the second day.

4. In one case, No. 12, there was hydrocephalus, which was also noted in Nos. 2 and 4 of Ballantyne and Thomson's collection.

5. In one case, No. 9, in which there was no spina bifida, the child was reported at six months to be quite well. The others all died in the first few weeks, in most cases from complications arising from the spina bifida.

In reply to speakers, Dr. ANDREWS said that he had called his case "congenital" prolapse, following the example of others who had recorded cases. In none except No. 9, and possibly Nos. 3 and 6, was the prolapse actually present at birth. Monro had recorded a case in which prolapse occurred at the age of three years. If this case were described as "infantile," and the others as "prolapse in the newly born," the terminology would be more correct. He quite agreed with Ballantyne and Thomson and others that the cause of the prolapse was probably weakening of the supports of the uterus, due to the spina bifida. No microscopical examination of the sacral nerves had been made in this case, as they were bathed in pus.

TUBERCLE OF THE UTERUS.

Shown by Peter Horrocks, M.D.

This specimen was removed by vaginal hysterectomy from a lady nearly seventy years of age. It was thought to be malignant disease of the cervix from the symptoms and signs. She was a married lady, but had never had any children. The cervix was enlarged and bled easily on touching, but it was not so hard as is usual in cancer of the cervix. Pain was not a prominent feature in the case, and she had not lost much flesh.

On removal it was found that the disease had extended throughout the entire endometrium, cervical and corporeal, in this respect differing markedly from cancer. The patient made a good recovery, and is at present, after twelve months, in excellent health. There was no evidence of lung mischief.

ABNORMAL UMBILICAL CORD; TUBERCLE OF UTERUS.

Shown by Herbert Williamson, M.A., M.B.

(1) Specimens of umbilical cord containing four umbilical arteries and only one umbilical vein.

(2) Two specimens of tubercle of the body of the uterus. One of these specimens, even after removal, was regarded as carcinoma until microscopic examination revealed the presence of giant-cells and tubercle bacilli.

TUBERCULOSIS OF CERVIX.

By E. O. Croft, M.D.

Dr. E. O. Croft showed a uterus which he had removed by vaginal hysterectomy for tuberculous papillary cervicitis. Microscopic sections from the same specimen, showing typical tubercular structure with giant-cells, were also on the table among the series exhibited by Mr. Targett.

The specimen was removed from a young nulliparous woman aged 26, who had been married two and a half years. There was a strong family history of phthisis in her mother's family, but her husband was perfectly healthy. Menstruation had always been scanty and infrequent, but there was chronic leucorrhœa.

The last period occurred early in 1901, and amenorrhœa persisting, the patient thought she was pregnant. The confinement not taking place she was examined, and a growth of the cervix discovered which bled readily on touching. The cervix was enlarged, and the growth, which occupied the site of an ordinary erosion, was prominent, softish, and had a papillary structure, the projections varying in size from fine granulations to polypoid masses as large as currants. These growths readily broke away and were preserved for examination. The cervix was scraped, and further portions removed for examination. On both occasions well-marked tuberculosis was revealed. As there was no evidence of tubercle in any other organ, the uterus was removed *per vaginam*. At the time of the operation the tubes and ovaries were examined and seemed healthy. They were not removed. The body of the uterus was small and appeared healthy, but subsequent microscopical examination has proved that there was also tuberculous tissue in the corporeal endometrium.

The patient made a rapid recovery, but the future history will be watched with interest. The discovery of tubercle in the body of the uterus after its removal suggests that it would have been wiser to remove the tubes as well, as there is the possibility of the lesion having been a descending rather than an ascending one.

A CASE OF PRIMARY TUBERCULOSIS OF THE CERVIX SIMULATING CANCER, AND TREATED BY VAGINAL HYSTERECTOMY.

By Arthur H. N. Lewers, M.D.Lond., F.R.C.P.Lond.,
OBSTETRIC PHYSICIAN TO THE LONDON HOSPITAL.

(Received February 14th, 1902.)

(*Abstract.*)

The patient was a married woman, thirty-six years of age, who had never been pregnant.

For nine months before she came under observation there had been a vaginal discharge, which was blood-stained, and slightly offensive. Bleeding had been noticed after coitus, and also after using a vaginal syringe. She had had slight pain in the left iliac region for about five months. This did not appear to have been at all severe.

The catamenia had been regular, lasting three or four days only, and not attended by any special pain.

The patient's general health had been good up till twelve months before she came under observation. Then she found herself beginning to get weak and disinclined for exertion, and to suffer from the local symptoms above mentioned. She did not think she had lost flesh.

One of her aunts died of consumption, but otherwise the family history was unimportant.

On vaginal examination the condition of the vaginal portion of the cervix seemed identical with what is found in many cases

of cancer. The vaginal portion appeared to be the seat of "a growth," which was friable, and bled readily on examination. The uterus was freely movable.

Believing that the case was one of cancer of the cervix suitable for radical operation, the author performed vaginal hysterectomy on January 30th, 1896.

The patient made a good recovery.

The author has seen her several times since, and had a letter from her on the 20th of November, 1901, in which she said that she "enjoys fairly good health, and has had no return of the bleeding."

While she was in the hospital there was no evidence of any disease in other organs.

When portions of the supposed malignant growth were sent to the Clinical Research Association for examination, the report came back that there was no evidence of cancer, but that the structure was tubercular.

The author refers briefly to the writings of Pozzi, Cullen, and Whitridge Williams, from which it appears that primary tuberculosis of the cervix is an exceedingly rare condition.

Mrs. S. T—, aged 36, a housekeeper, was sent to see me by Dr. Haslip on January 21st, 1896.

She had been married eight years, but had never been pregnant.

She said that she had suffered from a white vaginal discharge for years, even before her marriage. During the last nine months, however, there had been bleeding noticed in between the periods. The discharge had been slightly offensive. The first time the irregular bleeding occurred was nine months ago, after coitus. Besides the blood-stained intermenstrual discharge she had noticed pieces of skin in it from time to time, especially after the menstrual periods. For the last three months she had used a syringe for the vagina, and on two occasions passing in the pipe of the syringe had brought on bleeding.

She had had pain in the left iliac region for five months, and also a dull feeling round the lower part of her body.

The pain, however, did not seem to have been at all severe, and it had not been constant till the last week.

The catamenia had been regular every calendar month, lasting three to four days, and attended with very little pain. The amount lost had, if anything, been recently less than usual.

Three years ago she had bronchitis and influenza badly, and she had bronchitis again last year (1895). Before she was married she had gastric ulcer and hæmatemesis. But as a rule she had enjoyed good health until about the last twelve months, when she began to get weak, disinclined for exertion, and to suffer from the local symptoms already mentioned. She had not definitely lost flesh.

As regards the family history, one of her aunts died of consumption; that is the only case of it she knows of in the family.

Examination (January 21st, 1896).—Nothing abnormal was detected on examination of the abdomen.

On vaginal examination the external os was distinctly more patulous than usual, and a soft friable growth was felt within it in the cervical canal as far as the finger could reach. The growth bled very freely on touching it. Through the speculum the growth was seen to be slightly raised, and most of it was on the anterior lip and to the left, though there was some all round the os. The uterus bimanually seemed to be about normal in size, and freely movable.

On the signs and symptoms above mentioned I had no doubt at the time that the case was one of malignant disease of the cervix, and I advised the patient to have the uterus removed. Accordingly she was admitted into the London Hospital under my care on the 24th of January, 1896.

On January 27th the patient was anæsthetised, and a careful examination made. The result confirmed what had been found at the previous examination. The whole appearance was, as far as I could judge, identical with that

met with in many cases of cancer of the cervix. The supposed growth broke down very readily when pressed on with the sound. The case seemed to be one of cancer of the cervix suitable for vaginal hysterectomy.

Operation (January 30th, 1896).—The uterus was removed by vaginal hysterectomy. The cut margins of the vaginal wall were freely seared with Paquelin's cautery. Pressure forceps were used to secure the vessels in the broad ligaments, and were left on. An iodoform gauze drain was passed between the forceps so as to project about an inch into Douglas's pouch. The forceps were all removed at the end of the third day, and the subsequent history of the case was uneventful.

On February 20th an examination was made. There was a healthy-looking granulating wound, about half an inch in diameter, at the top of the vagina. The patient went home on February 22nd.

I have seen the patient three times since the operation, and examined her. The scar at the top of the vagina was on each occasion quite healthy, and the patient was in good health.

I wrote to her recently to know how she was, and she replied in a letter dated November 20th, 1901, that "she enjoys fairly good health, and has had no return of the bleeding." She occasionally has bronchitis and slight "congestion."

Description of the uterus (after nearly six years in spirit).—The extreme length is three inches and one eighth.

Three pieces have been cut off for microscopic examination, and sent to the Clinical Research Association. Two from the cervix were reported on by Mr. Targett, as showing tubercle. One piece from the fundus showed nothing abnormal.

Before the uterus was laid open the external os was more patulous than normal. Round it are seen a series of papillary projections, which extend some way up the cervical canal. The largest is close to the internal os.

Two drawings of the section were made under Mr.

Fig. 1.

Fig. 2.

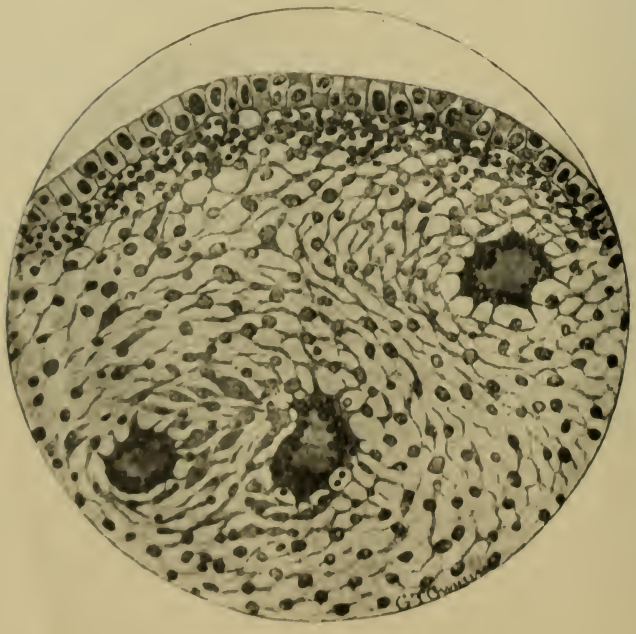

Targett's supervision by the Clinical Research Association, and he has kindly given me the following description of the figures :

"*The upper drawing* (Fig. 1) represents a portion of the mucous membrane of the *cervix uteri* thrown into ridges, and thickened by inflammatory growth. In one of these ridges is embedded a group of grey tubercles with large well-formed giant-cell systems.

"*In the lower drawing* (Fig. 2) the top of this ridge of mucous membrane is represented with its columnar epithelium and cellular tissue. Three large polynuclear cells are represented."

Fig. 3.

Remarks.—Cullen, in his valuable work on 'Cancer of the Uterus,' mentions cases of tuberculosis of the cervix. He says, "This rare condition [tuberculous ulceration of the cervix] clinically might readily be mistaken for squamous-celled carcinoma of the cervix." He refers to

a few cases. In one there were condylomata and tuberculosis of the cervix. The cervix was amputated, vaginal hysterectomy being found impossible. The patient died about a month after the operation, apparently of tuberculosis of the lungs. At the autopsy there was found general tuberculosis of almost all the organs. As regards the signs in this case, on physical examination there were polypoid masses on the cervix and vaginal vault, not showing any tendency to bleed on examination. The patient was a coloured woman aged seventeen.*

In another case mentioned by Cullen the patient died of general tuberculosis; there was tuberculosis of the uterus, tubes, and ovaries. There was no evidence that it was primary in the uterus.†

Cullen also refers to a case reported by E. Kaufmann. In this tuberculosis of the cervix was discovered at an autopsy on a patient aged seventy-nine. There was no general tuberculosis in this case. ‡

He does not, as far as I have seen, refer to any case in which the disease was limited to the cervix and primary there, and in which the condition led to an examination during life.

In my case the "growth" on the cervix bled very readily on examination, and was also friable. In fact, it was not till examination of the tissue with the microscope, after the uterus had been removed, that I entertained the slightest doubt that the case was one of cancer of the cervix. I suppose there can be little question but that, given a case of primary tuberculosis of the cervix, where there is reason to believe there is no tubercle elsewhere, vaginal hysterectomy is the right treatment. In my case, however, I have to admit that, if that be so, the right treatment was adopted on a wrong diagnosis.

I may mention that it was not till four years after the operation that a portion of the cervix was sent to the

* Cullen, 'Cancer of the Uterus,' p. 194.

† Ibid., p. 193.

‡ Ibid., p. 346.

Clinical Research Association for examination, so certain had I felt that the case was an ordinary one of cancer of the cervix. In the year 1900 I was writing a paper on the after histories in forty cases of vaginal hysterectomy performed for cancer of the uterus. This case was one of that series. I obtained reports from the Clinical Research Association on portions of the cervix or body of the uterus, as the case might be, in each of the cases in which the disease was known not to have recurred. When I sent a portion of the cervix in the case that forms the subject of this paper I fully expected to get back a report that the tissue showed cancer. Instead of this, however, Mr. Targett reported that the tissue showed the presence of tubercle, and asked for another piece of the cervix to examine. This was sent, and the report came back that this portion, like the first, showed the presence of tubercle.

Recently (December, 1901) I sent the first section of the cervix prepared (and drawn) by the Clinical Research Association to Dr. Bulloch, Bacteriologist and Lecturer on Bacteriology and General Pathology to the London Hospital. He reported on it as follows:—"I beg to report that I have examined one stained section of a growth said to have been removed from the uterus by Dr. Lewers. The section was evidently a transverse one through the mucosa of the uterus, and contained an abnormal tissue. The epithelium of the mucous membrane was divided so as to expose the cytogenic tissue, in which parts of the uterine glands could still be detected, and they did not appear to be abnormal. Lying, however, in the cytogenic tissue were several nodules, which presented the classical appearances of a tubercular giant-cell system. The giant-cells were polygonal, and contained many nuclei, the main part of the nodule being composed of epithelioid cells in a state of vacuolar degeneration. In the absence of the positive proof of the existence of *Bacillus tuberculosis* in the nodules an exact diagnosis is impossible. There can, however, be no doubt that the lesion is of a chronic granulomatous type, most probably tubercular."

Dr. Bulloch asked me for a portion of the cervix that he might make sections for himself, and this, making the fourth piece cut off the uterus for microscopic examination, was sent him. His report on this piece is as follows:—"I have nothing further to add to the report I have already sent you, with the exception of the fact that, although the structure was tubercular, no tubercle bacilli could be found in six specimens stained specially to show them."

Pozzi* says at the beginning of his chapter on "Tuberculosis of the Generative Organs," "Invasion of the generative apparatus by the tubercle bacillus is somewhat rare. Certain regions, *e. g.* the vagina and the cervix, appear to be very refractory to it, no doubt on account of the resistance of the stratified epithelium that protects them. It is the tubes that are generally the starting-point of tubercular lesions. From the tubes the disease readily passes to the ovaries, and more rarely it descends down into the uterus itself." He also says, "Cases of tubercular disease limited to the cervix are not numerous," and refers to two cases, one by A. Laboulbène and another described by Cornil. The latter case was one in which the clinical signs suggested malignant disease, and on the assumption that the case was one of cancer, Péan removed the uterus. Examination of the uterus afterwards proved that the morbid process was tubercular. Cornil was not, however, able to find any bacilli.

The case recorded in this paper is therefore very similar to that of Cornil. In both cases the condition present was believed to be cancer, and in both, on this mistaken diagnosis, hysterectomy was performed. In both, although the structure was characteristically tubercular, tubercle bacilli could not be found.

There is an exhaustive paper on tuberculosis of the female generative organs by Dr. J. Whitridge Williams in the 'Johns Hopkins Hospital Reports' (vol. iii, 1892, p. 85).

* 'Treatise on Gynæcology,' vol. iii, p. 128 (the New Sydenham Society), 1893.

The references to the literature are there very fully given, as will be evident from the fact that they are 133 in number. Though, however, there is this large mass of literature on tuberculosis of the female generative organs, there is very little of it concerned with primary tuberculosis of the cervix. It is interesting to observe that when tuberculosis affects the body of the uterus it very rarely involves the cervix, and also that when it involves the cervix the body of the uterus is very rarely affected. In most of the cases of tuberculosis of the cervix tuberculosis of the vagina has been present as well. In other cases tuberculosis of the cervix has been the sole manifestation of the disease in the genital tract in women the subjects of phthisis. Lastly, the cervix may be the only part of the whole body affected by tubercle. Apparently Cornil and Péan's case is the only one observed and recognised during the life of the patient; though even there, as in my case, the uterus was removed on a mistaken diagnosis of cancer. There is also a case of Zweifel's, in which a similarly wrong diagnosis was rectified by examining a portion of the cervix with the microscope before operating. Whitridge Williams has no doubt that "tubercular ulcerations of the cervix have not infrequently been operated upon on the supposition that they were of carcinomatous origin." There is a case by Zweigbaum, of Warsaw, reported in the 'British Medical Journal' (vol. i, 1889, p. 93), which is interesting as bearing on treatment. In that case the vaginal portion of the cervix was affected. He apparently cured the local mischief in three weeks by the application of the cautery. The patient, however, died five months later of general tuberculosis, and there was recurrence of tubercular ulceration in the vagina. As this patient died of general tuberculosis comparatively soon after the vaginal portion was found affected with tubercle, it does not seem quite clear that the cervix was the only part affected when the case first came under observation.

The fact that tuberculosis of the cervix may easily be mistaken for cancer may perhaps throw some light on

those few, very few cases of so-called cancer of the cervix which have recovered spontaneously without operation, for it appears not very improbable that a patient with tuberculosis limited to the cervix might occasionally recover spontaneously.

The PRESIDENT said he was surprised to hear that tubercle in the uterus in the majority of cases was confined either to the cervix or to the body; for in the only two cases that had come under his own observation the whole mucous membrane, from the os externum to the top of the uterus, was affected, and he had thus been led to think that tubercle differed essentially in this respect from cancer. Also in his own case and in Dr. Lewers' case the patients had never been pregnant. He was surprised to hear Mr. Targett say that it was easy to diagnose tubercle. Certainly it might be in the lungs, either clinically or post mortem, with the naked eye; but in tubercle of the uterus he thought it was difficult, and even where a piece had been cut out and investigated microscopically it had been pronounced to be sarcoma. He was under the impression that the specimen shown by Mr. Targett from the Guy's Hospital Museum was the same one to which he had referred. She was in a medical ward, and he (Dr. Horrocks) had seen her, and had diagnosed from the condition of the swollen cervix, which seemed filled with ovula Nabothi, a follicular inflammation of the cervix. She was transferred to the care of Dr. Galabin, who cut a piece out, and after careful microscopical investigation came to the conclusion that it was sarcoma, and removed the uterus by vaginal hysterectomy. The whole of the internal mucous membrane was greatly thickened and diseased throughout. It was examined at the Royal College of Surgeons by Dr. Goodhart and some one else, and tubercle bacilli were found.

Dr. E. O. CROFT remarked, in reply, on the importance and difficulty of diagnosing cases of tuberculous cervicitis. There was a closer resemblance of the symptoms in Dr. Lewers' case to those of cancer than in the case described by himself. Dr. Lewers' patient had had bleeding, pain, and some offensive discharge. Dr. Croft's case had absolute amenorrhœa for many months, bleeding only taking place when examined. The growth was softer than in cancer, and did not break away in the same crumbling manner. The papillary masses were easily detached, and were more of the consistence of mucous polypi than of the vegetations of cancer. Dr. Croft, on his first examination of the case, concluded that the growth was not of the nature of any of the ordinary forms of cancer of the cervix, but kept in mind the possibility of an early condition of botryoidal sarcoma or

myxoma of the cervix. The tuberculous nature of the lesion was, however, established by microscopic examination before operation was decided on. In reply to a remark of Dr. Lewers, Dr. Croft said that tubercle bacilli had not been definitely demonstrated.

Dr. LEWERS said, in reply, that there was no evidence of any disease in other organs when the patient was in the hospital. She was, besides, known six years later to be in good health, so that there could be no reasonable doubt that the disease in his case was primary in the cervix. With the exception of the specimen shown by Dr. Croft, those referred to by the various speakers appeared to be all cases in which the tuberculosis of the uterus was not primary. The history in Dr. Croft's case was obviously very different from that in his (Dr. Lewers') case. In the latter there was metrorrhagia, while in the former there was a long period of absolute amenorrhœa. Even in Dr. Croft's case, however, hæmorrhage occurred on examination.

MAY 7TH, 1902.

PETER HORROCKS, M.D., President, in the Chair.

Present—38 Fellows and 8 visitors.

Books were presented by the New York Hospital Staff, the American Gynecological Society, and Dr. Alfons Rosthorn.

Henry J. F. Simson, M.B., F.R.C.S.Ed.; Florence Nightingale Boyd, L.R.C.P. and S.I., M.D.Brux.; Ada Margaret Browne, L.S.A.; and Frederick J. Willey, M.B., B.S., were admitted Fellows of the Society.

John Tennant, M.A., M.B., C.M.Edin. (Belfast), was declared admitted.

The following gentlemen were elected Fellows of the Society:—Arthur Raymond Stilwell Freeland, M.R.C.S., L.R.C.P.; and Ernest Wool Lewis, M.R.C.S., L.R.C.P.

LYMPHANGITIS MAMMÆ: AN AFFECTION OF THE BREAST ARISING ABOUT THE TENTH DAY OF THE PUERPERIUM WITH WELL-MARKED CLINICAL FEATURES. (ILLUSTRATED BY SIX CASES.)

By Ralph Vincent, M.D., B.S., M.R.C.P.

(Received April 17th, 1902.)

The condition I describe is well known to many; at Queen Charlotte's Hospital it has received various names, such as "flushed breast," "sapræmic breast," etc., and I claim no originality of observation in this respect. But in obstetric literature the condition is scarcely at all referred to, and I am not acquainted with any description corresponding with the typical character of these cases. The following cases all occurred at Queen Charlotte's, and I am indebted to the Medical Committee for permission to report them.

Case 1.—A. S—, aged 18, a single primigravida, was delivered on October 30th. The labour and early puerperium were quite normal. The uterus involuted well; the lochia were brown on the eighth, scanty on the eleventh, and absent on the fourteenth day. On November 8th (tenth day) the patient was well; the uterus was small, in proper position, and there was no uterine tenderness; the lochia were pale. The breasts were acting well, and there was no pain or tenderness. The secretion was normal, and the infant gained regularly from the third day. At 8 a.m. on the eleventh day (November 9th) the temperature was 101·2°, and the right breast was flushed on the inner and lower quadrant. At 2 p.m. the affection was well marked; the area of inflammation was wedge-shaped with the apex at the nipple. The skin was red, indurated, and very tender on palpation; the temperature was 102·6°. Hot fomentations were applied;

at 8 p.m. the patient was still suffering from much pain, and the temperature was still as high. During the night the condition rapidly improved, and at 8 next morning there was only slight redness, and the tenderness had almost disappeared; the temperature had fallen to 99·4°. On the following day the breast was quite sound, no trace of redness, tenderness, or induration could be discovered, and the temperature was normal.

Case 2.—E. J—, aged 28, a married primigravida, was delivered May 13th. The chorion was partially retained. There was a slight perinæal laceration, which was repaired, and which healed aseptically. On the third day the breasts were inactive, the nipples were retracted and sore, having been injured by the vigorous infant. The uterus was normal, the lochia were scanty and pink in colour. The intestines were somewhat constipated, and the patient had a prolapsed internal hæmorrhoid. On May 17th (fifth day) the lochia were offensive; no membrane had been passed. At 11 a.m. the uterus was four and a quarter inches above the pubes, and it was tender on the left side. The nipples were improving. Vaginal douches (Tr. Iodi ʒj ad Oj) were given night and morning. On May 18th (sixth day) about one square inch of membrane came away with douche fluid. On May 21st (ninth day) the outer side of the right breast was flushed, and during the day the condition developed. At 8 a.m. the temperature was 100·8°, at 2 p.m. 102°, at 8 p.m. 101·6°, at midnight 99·2°. The physical signs were the same in all respects, except the precise situation, to those in the previous case. The patient complained of headache and was constipated. Hot fomentations were applied and castor oil administered. At 8 a.m. next morning the temperature was 98·2°, and the affection had practically disappeared.

Case 3.—E. A—, aged 22, a single primigravida, was delivered February 21st. The perinæum was lacerated

and was repaired; the labour was otherwise normal. The puerperium was practically normal up to the twelfth day. The perinæum was quite clean, and the sutures were removed on the ninth day. The uterus involuted well, and the lochia were quite normal. The breasts were large and secreted well; the nipples were sound. The patient was somewhat constipated, and the usual daily enemata were supplemented by doses of Pulv. Glycyrrhizæ Co. On the eleventh day the patient was well. At 8 a.m. on the twelfth day (March 4th) the temperature was 97°; pulse 68. During the day the temperature rose slightly; at 2 p.m. it was 98·8°. On the left breast at the lower and outer quadrant was a wedge-shaped area, flushed and slightly tender. The signs all increased in severity during the day, and at 11 p.m. the temperature was 102·2°. The usual treatment was adopted, and at 8 a.m. next morning the temperature was 101°. The breast was still flushed, but the signs were diminishing, and at 8 p.m. the temperature was normal, and the inflammation had disappeared.

Case 4.—A. M—, aged 31, a single primigravida, delivered April 8th. This was a case of pelvic presentation, and labour was tedious and difficult. The puerperium was normal up to the twelfth day (April 19th). The uterus involuted well, the lochia were quite normal, and the breasts gave rise to no trouble. On the 19th, in the afternoon, the patient complained of pain in the left breast. At the upper and outer part of the breast there were tenderness and induration, but no redness. Hot fomentations were applied. On April 20th (thirteenth day), at 8 a.m., the temperature was 98·6°, at 2 p.m. 99°, at 8 p.m. 103°. The typical condition was well marked, and the wedge-shaped area was brightly flushed. During the next day the condition rapidly subsided.

Case 5.—C. J—, aged 22, a single primigravida, was delivered on April 12th; the labour was normal. On the

eighth day (April 19th), after the temperature had been irregular for some days, it rose to 101·2°. The lochia were free and brown in colour; the breasts were very distended, the uterus was small and not tender. The uterus was douched, and this brought away a few shreds. On the ninth day (April 20th) the breasts were still large and tender, distended by the great quantity of milk secreted. The nipples were sound. The uterus was involuting well, the lochia were normal, and scanty in amount. On the eleventh day (the 22nd), in the morning, the patient complained of pain and tenderness in the left breast. During the day the signs developed, and the evening temperature was 103°. On the twelfth day the inner half of the left breast was indurated, red, and acutely tender; the wedge shape was well defined, and the temperature was 104°. The condition gradually subsided. On the thirteenth day the temperature was normal, and on the fourteenth day all signs of inflammation had disappeared.

Case 6.—V. B—, aged 22, a single primigravida, was delivered on June 29th of a premature infant. The labour was easy and the early puerperium was normal. On July 7th (ninth day), at 8 a.m., the temperature was 100°, at 10 it was 102°, and on the inner and lower quadrant of the right breast there was a wedge-shaped area, red, and raised above the surface, slightly œdematous, tender to the touch, and indurated. By the next morning the signs had disappeared.

The temperature charts show a rise occurring, in each case, between the end of the first week and the beginning of the second week.

These cases, I think, demonstrate the existence of this disorder as a special affection of the breast quite *sui generis*.

Lymphangitis arises about the tenth day of the puerperium. About this time a pink flush may be seen on some part of the breast; this gradually develops, and in the course of twelve hours the following clinical picture

presents itself. There is a wedge-shaped area of inflammation, the apex being at the nipple, the base being at some part of the junction of the breast with the chest wall. This wedge-shaped area is red, slightly œdematous, hot to the touch, tender and indurated, the induration being distinctly outlined and definitely corresponding with the redness. The inflamed area is raised above the general breast surface, but the inflammation is confined to the superficial structures, and does not involve the mammary gland. During the development of this condition the temperature rapidly rises, the patient complains of pain in the breast and of headache, whilst constipation is frequently present. The treatment required is simple; the infant is taken from the breast, hot fomentations are applied to the inflamed part, and the patient is freely purged. Within about forty-eight hours the affection has disappeared.

The condition is interesting in several ways; it is especially so in its adherence to type: (*a*) the onset is sudden and characteristic; the time of the onset is remarkable, being nearly always between the eighth and twelfth days of the puerperium; (*b*) the physical signs are definite and well marked; (*c*) the duration of the attack is short, and the prognosis is invariably favourable despite the local and general signs of severe infection, for such would generally be their significance under ordinary circumstances.

With reference to the ætiology of the condition, the following considerations are of importance:

(1) Lymphangitis mammæ occurs in cases where there has been no evidence of any sepsis, and where the lochia have been quite normal throughout.

(2) The definitely wedge-shaped area, with the apex at the nipple, points strongly to an infection of the lymphatics arising at the nipple.

(3) The infection is easily conveyed to the nipple by a nurse whose hands are contaminated by the lochial discharge, and in various other ways.

(4) The time of onset is of great importance in considering the ætiology of the condition. The possible sources of infection are many; but all of them, with one exception, exist both before and after the second week of the puerperium. We may dismiss, therefore, these various possibilities, since they do not meet the necessities of the case. On the other hand, there is one condition present at this time and absent before and after—the lochia serosa.

I conclude, therefore, that lymphangitis mammæ is due to an infection of the lymphatics at the nipple, and that the infection is due to lochial contamination. Obvious decomposition of this discharge may be a predisposing factor, but I do not think it is; it certainly is not an essential factor. The lochial discharge in its normal condition at the second week is capable of producing the infection. I may add that, after the observation of a considerable number of cases, I think that the conjunctivitis occurring in infants about the second week, when the eyes have been previously free, is due to the same cause.

Dr. Amand Routh asked if the author was sure that some of his cases were not small mammary abscesses, which had opened suddenly into one of the larger milk ducts, thus accounting for the sudden cessation of all the symptoms.

A PROBABLE CASE OF SUPERFŒTATION.

By W. F. Victor Bonney, M.S., M.D.

Dr. Victor Bonney showed a specimen of very early twin gestation passed by a patient of Dr. Bromet's after one month's amenorrhœa.

The specimen consisted of a mass of thickened decidua and organised clot, containing two complete amniotic

cavities, each surrounded by its own chorion and primitive chorionic villi.

The interest of the specimen lay in the fact that the contained fœtus were in different stages of development, the smaller being barely of three weeks' growth, while the larger was of between six and seven weeks.'

There was nothing either microscopically or macroscopically to indicate that the smaller fœtus had died before the larger one,—indeed, the smaller appeared to be in the better state of preservation of the two. Dr. Bonney referred briefly to the possibility of this being a case of superfœtation, and pointed out that several explanations might be given of the unequal development of the two embryos. Thus it might be explained on the assumption that the patient had a double uterus, or that the smaller represented a blighted embryo whose nutrition had been interfered with by the growth of its stronger companion, or that the smaller embryo had died some weeks before the larger one. Against the first was the fact that the two gestation products were expelled in one mass; and further, that there was no evidence of any sort of a double uterus. As regarded the second the speaker pointed out that the smaller embryo was in no sense "blighted," but was as perfect in all its parts as the larger one, merely differing from it in stage of development; and finally, there was no evidence to support the third suggestion, since the smaller embryo appeared to be in the better state of preservation of the two.

The alternative to these three explanations was that the smaller fœtus represented an ovum which had become fertilised nearly four weeks after the fertilisation of the ovum which had produced the larger one.

The speaker referred briefly to the difficulty of getting exact evidence as to superfœtation, but said that he considered that this specimen was probably an example of that phenomenon. He also showed for comparative purposes a perfect and very early ovum passed by a patient attending the out-patient department of the Chelsea Hos-

pital for Women. It was of between three and four weeks' development.

GANGRENOUS SARCOMA OF UTERUS REMOVED BY ABDOMINAL HYSTERECTOMY FROM A PATIENT SUFFERING FROM GLYCOSURIA.

By Walter Tate, M.D.

This tumour was removed from an unmarried lady, aged 50, who had had the menopause five years previously. In January, 1901, she began to notice a purulent blood-stained discharge, which later became offensive. In July, 1901, she consulted her medical attendant, as she had had a flooding. As she refused to have any examination made chinosol douches were ordered, and by the end of July the discharge was much less and not offensive. In August an examination was made for the first time, and the uterus found to be as large as a cricket ball. A second opinion was advised, but patient insisted on going away to the country for change. She remained at Hastings for five months, during which time she had a large quantity of very offensive discharge, which was so copious that she had to wear a urinal to collect it. While at Hastings she had one or two severe febrile attacks due to septic absorption. The temperature rose to 104° and 105°, and she had rigors. The patient was losing ground steadily, and was very ill and anæmic. It was also discovered that there was sugar in the urine. In January, 1902, the patient returned to London and again consulted Dr. Seymour, her original doctor.

He found the tumour had grown very rapidly, and, as the patient's condition was critical, he brought her to see me early in February. The patient at this time was

looking exceedingly ill, very anæmic and wasted, and markedly cachectic. A most offensive odour pervaded the whole room as soon as the patient entered it. The abdomen was somewhat distended by a very firm and fairly smooth tumour, which reached to two inches above the umbilicus. This tumour was fairly mobile from side to side. The cervix was high up and quite normal; the lateral fornices were free from any suspicion of infiltration, and bimanually the tumour was found to be freely mobile. There was a quantity of chocolate-coloured offensive discharge escaping from the os.

The tumour was thought to be either a rapidly growing sarcoma or a sloughing fibro-myoma. The urine had sp. gr. 1026, and readily reduced Fehling's solution.

As there was no evidence of any extension of the disease outside the uterus, and the patient was being poisoned owing to septic absorption from the gangrenous tumour, its removal was advised.

Operation (February 18th, 1902).—The vagina having been thoroughly cleansed, the cervix was drawn down to the vulva, and the cervical canal closed, so as to prevent escape of the foul discharge from the interior of the uterus. For this part of the operation rubber gloves were used. After a second thorough cleansing of the vagina the rubber gloves were removed, and the abdomen opened by a six-inch incision. The tumour was readily brought out of the wound, and both broad ligaments were seen to be perfectly healthy and free from any infiltration. The uterus was completely removed without any difficulty, a gauze drain was passed through into the vagina, and the abdominal incision closed without drainage.

The tumour removed was about the size of a six months' gestation, and weighed 5¼ lbs. It measured seven and a half by six and a half by four and a half inches. The cervix was elongated, and the sutures passed through it had entirely prevented any escape of the contents of the uterus. The outer surface of the

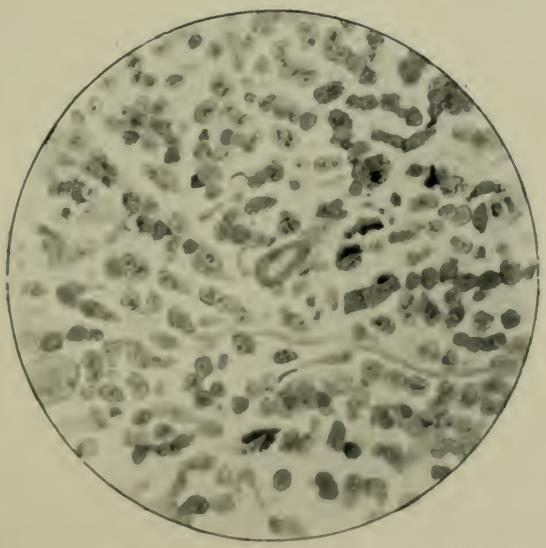

Illustrating Dr. WALTER TATE's specimen of Gangrenous Sarcoma of Uterus.

Adlard & Son, Imp.

tumour was quite smooth, and externally the tumour presented an appearance like a fibro-myoma. On making a coronal section through the tumour from the fundus downwards towards the internal os the tumour was seen to consist of two distinct parts: a smaller part as large as a Jaffa orange, which had the typical appearance of a fibroid tumour; and a larger part, in the middle of which was the enormously expanded uterine cavity, the walls of which were gangrenous, surrounded by an extensive mass of growth infiltrating the walls to a depth varying from one to three inches. There was a zone of healthy muscular tissue between the growth and the peritoneal surface of the uterus, and also a well-defined septum of healthy muscular tissue between the growth and the fibroid.

Microscopically the growth proved to be a round-celled sarcoma, and, on examining a portion of the growth next the fibroid, there was a very clear line of demarcation between the growth and the fibroid.

This case illustrates very clearly the localised nature of malignant growths when they affect the body of the uterus. It also is interesting to observe the absence of any sarcomatous degeneration of the fibroid in spite of the very extensive sarcomatous disease present in the uterus. It would almost suggest that fibroid tumours are protected against invasion by sarcomatous growth.

Another point of interest in this case was the presence of glycosuria. It was thought before the operation that this might be an absorption diabetes due to the gangrenous growth in the uterus. The subsequent history of the patient showed that this was not the case. It is true that two days after the operation the urine contained no sugar, but this was probably due to more or less absence of any carbohydrate diet. At the end of a week the urine was found again to contain sugar, and three weeks after the operation the patient was passing seventy to eighty ounces of urine of sp. gr. 1035, and there was a rapid reduction of Fehling.

The patient made an uninterrupted recovery, and left the nursing home in less than four weeks.

The PRESIDENT asked whether the whole of the sarcomatous portion had been examined, because it was possible for it to be a fibroid undergoing sarcomatous change. This form of degeneration undoubtedly did occur on fibroids of the uterus. The question of operating in cases complicated by diabetes was a serious one, not so much on account of the kidneys being unable to do the extra work following upon an operation, but because of the mental disturbances, the dread of operation, etc., resulting in diabetic coma. He mentioned a case of a simple fibroid polypus being removed quite easily and without an anæsthetic, where the patient died in a few days from diabetic coma. His colleague, Dr. Parry, saw her, and said that patients with diabetes sometimes developed coma in the hotel or lodgings where they were staying, apparently through the excitement caused by coming to see a physician about their ailment.

Dr. MALINS said that the specimens exhibited and the remarks made by the President afforded ground for questions of considerable interest and importance—whether fibroid growths of the uterus undergo malignant changes, and whether these growths and malignant disease can exist at the same time in the uterus independently. He had seen cases where a sloughing fibroid had been mistaken clinically for carcinoma, and *vice versâ*, and had lately removed the uterus from a patient where round-celled sarcoma had been found in a case of presumed myoma. The co-existence of these conditions in the same uterus was one of much significance from all points of view, and deserved careful attention.

A PURE MYOMA OF THE OVARY, WITH A MICROSCOPIC SECTION.

By ALBAN DORAN, F.R.C.S.

THIS specimen, which is of considerable interest, has not been exhibited before. I described it in a short communication published in a recent volume of the 'Edinburgh Medical Journal,'* where a drawing of the

* "Ovarian Tumours simulating Inflamed Ovaries, including a Case of Ovarian Myoma," 'Edin. Med. Journ.,' vol. iii, n. s., 1898, p. 449.

tumour and of a microscopical section will be found. It is now preserved in the museum of the Royal College of Surgeons (Path. Ser., 4532, A.a).

The patient was a single woman, aged 27, a straw-platter from the eastern counties, fairly well nourished, but crippled through infantile paralysis, which had arrested the development of the left lower extremity. In the spring of 1897 she began to suffer from severe bearing-down pains. By September they grew so distressing that she had to take to her bed. The catamenia were little affected by the illness; the show was moderate, accompanied at first by pain. A small cyst was detected in the posterior lip of the cervix, which was removed by Dr. Percy Boulton. He discovered a hard oval mass in the left fornix, and an elastic swelling in Douglas's pouch; they were connected and quite movable. We agreed that there was a new growth—not an inflammatory product—which caused the pelvic pain. The uterus was bulky, its cavity measured three inches.

On December 14th, 1897, I operated. There was no difficulty in drawing up the curious double tumour which lay in Douglas's pouch, and was attached to the right side of the uterus. It had fallen under the left ovary, which was free from disease. There was not the slightest trace of any inflammatory change in the pelvis and abdomen. The tumour was removed with the tube, the pedicle being anatomically normal, as in an ovarian cyst.

The pedicle being, as just observed, normal, the Fallopian tube and mesosalpinx appear entire, the latter not opened up. The place of the ovary is occupied by an almost unilocular cyst two and a half inches in long diameter; the ovarian ligament runs into its lowest and innermost part at the point of junction with the second tumour. The two new growths are united over a circular area seven-eighths of an inch in diameter. The solid tumour is a myoma. It is irregular in form, tuberous like a small potato, and when fresh was distinctly of a pale reddish-brown colour, like a uterine myoma. The

cut surface was also distinctly red, very unlike the dead white of a fibroma. There is a capsule, and internally the fibres are arranged in oval and spherical nodules as commonly seen in interstitial uterine myomata; these nodules make the surface irregular. No trace of ovarian tissue is to be detected either in the cyst or in the myomatous tumour.

I exhibit a section prepared at the College of Surgeons. It shows that the solid tumour is made up of well-developed plain muscle-cells, arranged in an irregular manner, while fibrous tissue is very scanty, and in parts totally absent. Thus the tumour is a true myoma, identical with the common uterine "fibroid." The section contrasts instructively with another which I exhibit to-night. It is figured in my contribution, "On Myoma and Fibro-myoma of the Uterus and Allied Tumours of the Ovary," in the thirtieth volume of our 'Transactions' (Plate III, fig. 5). It was taken from a large solid ovarian tumour, and is seen to consist of bands of pure fibrous tissue. The wavy bundles are most characteristic, and contrast strongly with the stouter muscle-cells from the myoma.

I marked the same pathological contrast between this fibroma and a genuine case of myoma of the ovarian ligament, which was accordingly also figured (loc. cit., Plate I, fig. 2) in my paper. I believe, as I did in 1888, when that contribution was submitted to the Society's consideration, that the muscular elements in a solid ovarian tumour are usually derived from the ovarian ligament, which is a process of muscular tissue from the uterus; that is to say, a uterine, not an ovarian element, making an elevation of the peritoneum of the broad ligament.

This theory seems supported firstly by the microscopic appearances of the minute tumour of the ovarian ligament figured in my paper, and secondly by this specimen of a tumour of the ovary, which is seen, on microscopic evidence, to be a pure myoma; whilst on naked-eye inspection it is clear that the ovarian ligament, con-

spicuously thickened, runs into this solid growth, or, more correctly speaking, the solid growth springs from the ligament which lies between it and the cystic growth. Thus the solid tumour is, as it were, a subserous myoma springing directly from a process of the uterus commonly called the ovarian ligament.

I have certainly detected plain muscle-cells in several large fibro-myomas of the ovary which I have examined, but these tumours were mostly made up of bundles of white fibrous tissue. It is reasonable to believe that even in these growths the muscle-cells were derived (in great part at least) from the ovarian ligament which runs into the ovary. I am diffident about the appearances seen in sections of very large tumours, often full of "young" connective tissue, and also more or less affected by myxomatous and other changes. This is the case in respect to the large solid tumour now in the museum of the College of Surgeons (Path. Ser., No. 4528) which I have figured and described as a "myoma;" * and my opinion has been widely quoted in text-books. The nuclei found about bundles of white fibres (as seen loc. cit., Pl. III, fig. 5, 'Trans. Obst. Soc.,' vol. xxx) often give an appearance as though the fibres were plain muscle-cells when the histological elements are indistinct, as in a large tumour like that specimen. As to this small tumour which I exhibit to-night, there can be no doubt that the section shows it to be mainly made up of plain muscle-cells.

In conclusion, it is clear that this tumour is a myoma of the ovary, and that it is closely associated with the ovarian ligament, which contains plain muscle-cells. I will presently bring forward an incipient fibroma of the ovary, lying far from the ovarian ligament, and contain-

* 'Clinical and Pathological Observations on Tumours of the Ovary, Fallopian Tube, and Broad Ligament,' p. 97, and fig. 19. No doubt this big tumour is in part made up of plain muscle-cells, and arose from the same source as in the case now exhibited, and as in Dr. Russell Andrews' specimen ("Fibro-myoma of the Ovary," 'Trans. Obst. Soc.,' vol xliii, 1901, p. 231).

ing no muscle-cells. The two specimens, when their microscopic appearances are compared, seem to suggest that myoma and fibroma are two distinct forms of tumour.

A PURE FIBROMA OF THE OVARY.

By Alban Doran, F.R.C.S.

This specimen is exhibited as a contrast to the pure myoma just brought forward. I related the clinical history of the case in my contribution on "Cases of Fibroma of the Ovary and Ovarian Ligament" to the thirty-eighth volume of the 'Transactions' (Case 7 in Table I). The specimen now belongs to the museum of St. Bartholomew's Hospital, Pathological Series, No. 2925B. I removed it in the summer of 1889 from a woman aged fifty-two, and I heard from her a few days ago, when she was in good health and free from any signs of recurrence. When fresh it weighed a little under three pounds. The microscopic sections showed a tense stroma of pure fibrous tissue, with a distinct area of young connective tissue. In short, it was precisely similar to the section from a pure fibroma which is exhibited to-night as contrasting with the section of a pure myoma. In February, 1897, I exhibited before the Society a tumour which Mr. Targett found to be a pure fibroma.* It had developed in the left ovary, and there were nearly ten pints of ascitic fluid in the abdomen. The rest of the history of this case, already published, is of clinical and surgical interest. Since I reported it I heard from the patient two years and a half after the operation there was no recurrence, and the menopause had set in. She was forty-nine when

* "Fibroma of the Ovary; Impaction; Ascites; Removal," 'Trans. Obst. Soc.,' vol. xxxix, p. 37.

I removed the tumour.* The right ovary showed no sign of disease.

I fancy that myoma and fibroma of the ovary are distinct diseases. There is no evidence that a myoma like that which I exhibit this evening ever grows into a fibroma like this specimen through disappearance of its muscular elements, though a myoma may from the first include much fibrous tissue, and grow into a big fibromyoma, as is so common in the uterus. The pure fibroma of the ovary seems as though it never contained a single plain muscle-cell.

This specimen, then, is a fully developed, though not very large, fibroma of the ovary. There is no reason for us to conclude that it ever histologically resembled the specimen of myoma which I have just exhibited, whilst there is every reason to believe that it once was, like the specimen I am about to demonstrate, an incipient fibroma of the ovary not half an inch in diameter.

FIBROMA OF OVARY ONE-THIRD OF AN INCH IN DIAMETER.

By Alban Doran, F.R.C.S.

I presented this specimen to the museum of the Royal College of Surgeons in 1882, and it is now in the Pathological Collection, No. 4527A. I described it as "a shrunken ovary containing a large corpus fibrosum,—that is, a nodule of fibrous tissue developed in a Graafian follicle." I exhibit it to-night in association with Dr.

* In July, 1898, I removed a pure fibroma of the ovary from a girl aged 20. It weighed 4 lbs. 11 oz., and there were nearly six pints of ascitic fluid in the peritoneal cavity. There had been amenorrhœa for three months. The period returned after the operation, and in 1901 there was no sign of any recurrence.

Fairbairn's interesting communication, and I will give reasons why I must modify my former opinion about the nature of the tumour as expressed in the above description, taken from the College catalogue.

The patient was forty years old. On January 20th, 1882, Mr. Knowsley Thornton removed a large soft sarcoma of the right ovary. Acute peritonitis set in, and the patient died on January 25th.

I removed the left ovary at the necropsy. As will be seen, it is small and rather flat. It measures one inch in length by half an inch at its deepest part, near its inner extremity. Its outer surface is somewhat wrinkled; its cut surface shows a firm stroma, bearing no normal follicles. Close to the ovarian ligament is a spherical mass about one-third of an inch in diameter. The cut surface of this mass seems precisely like the surface of a large fibroma. A small semilunar space external to the spherical mass seems to represent the cavity of a follicle diminished by the pushing in of its wall by the mass. In other words, the growth is not intra-follicular, but has arisen in the stroma and encroached on one follicle.

Mr. Shattock kindly made some sections of this little tumour last week, one of which I exhibit. We have carefully examined the sections together, and find, as will be seen, that the periphery of the tumour is made up of not very dense fibrous tissue, with numerous well-formed oval nuclei. The interior of the tumour is made up of very dense white fibre, with few nuclei. This fibre is evidently not necrotic, as well-formed capillaries ramify in it, whilst under a high power the fibres can be resolved into fibrils. The bundles of fibrils are so pronounced and so regularly intersect each other that they cannot represent scar tissue. On the other hand, there is no trace of hyaline degeneration.

There can be no doubt, then, that this little growth is a true fibroma. I remember that the other ovary was converted into a soft sarcoma, but have no note of its precise nature, as it was not sent to the College; in fact, as far as I can remember it was forwarded elsewhere after

the operation. The precise relation of the two new growths cannot therefore be determined, though we must suspect that they represent more than a coincidence.

The term "corpus fibrosum" which I applied to this little tumour was inaccurate, as I meant that it was a growth of the kind to which that term was applied by Patenko.*

The "corpora fibrosa" are, according to his researches, simply abnormal deviations of a natural process of sclerosis of the wall of a follicle, whether retrograde before ripeness or thoroughly mature. Patenko specially admits that there is no evidence that a corpus fibrosum ever becomes a true fibroma of the ovary. Indeed, the corpus fibrosum always shrinks, so that the sum of the largest possible number of corpora fibrosa that could form in one ovary would not make a perceptible enlargement; indeed, theoretically it would make the ovary smaller. Neither Mr. Bland-Sutton nor myself ever succeeded in tracing a fibroma to a corpus fibrosum; indeed, that kind of "body" is not made up of white fibres. Patenko is careful to note that the tissue is hyaline. The term "corpus *fibrosum*" is therefore very misleading.

Patenko noted that when a follicle has discharged its ovum, and instead of forming a corpus luteum undergoes sclerosis or hyaline changes in its walls, its cavity is invaded by a considerable amount of ovarian stroma, which undergoes partial atrophy. The corpus fibrosum thus produced is a structureless, semi-opaque, dull fusiform body, with the atrophied and sclerosed stroma within its substance. In the section which I exhibit the tissue of the growth is far from structureless, whilst sclerosis is conspicuous for its absence.

When compared with the small myoma which I have exhibited to-night, this specimen would seem to show that

* "Ueber die Entwickelung der Corpora fibrosa in Ovarien," 'Virchow's Archiv,' vol. lxxxiv (1881), p. 193. I wrote a full abstract of Patenko's monograph, which will be found in the 'London Medical Record,' vol. ix, p. 441.

myoma and fibroma of the ovary are perfectly distinct forms of tumour. Let it be specially noted that this minute fibroma lies far from the ovarian ligament, which contains plain muscle-cells, whilst the myoma is closely connected with that ligament.

FIBROMA OF OVARY.

By Florence Nightingale Boyd, M.D.

This specimen was removed from a single lady of sixty-one on February 13th, 1902. The menopause had occurred without troubles at fifty.

The patient had consulted Dr. Jane Walker two years previously for a lump in the lower abdomen and frequency of micturition. The tumour then reached halfway to the umbilicus. It remained fairly stationary till within three months of operation, when it increased in size somewhat rapidly. At the time of operation it extended centrally two fingers' breadth above the umbilicus and out into the flanks on either side, remaining freely movable. *Per vaginam* and *rectum* it was found to fill Douglas's pouch and bulge forward the right broad ligament. The cervix moved with it, and the fundus uteri could not be defined apart from it. The patient cycled long distances without trouble, and was comfortable when sitting or lying, but walking caused considerable discomfort owing to the frequency of micturition which it occasioned.

The tumour, which weighed 5 lbs. 14 oz., was entirely free from adhesions, and occupied the position of the left ovary with a two-inch pedicle. It was removed with the tube, which was not stretched or inflamed. The uterus was dragged upon, so that the whole small uterus was converted into a sort of fleshy pedicle to the tumour. The right ovary was atrophied; there was no ascites. I had operated on a younger sister some years previously for fibroid of the uterus complicated with a cystic ovarian tumour.

FIVE SPECIMENS OF FIBROID TUMOUR OF THE OVARY, WITH OBSERVATIONS ON THEIR PATHOLOGICAL ANATOMY.

By John S. Fairbairn, M.A., M.B.Oxon.

(Received March 17th, 1902.)

(*Abstract.*)

Attention is first directed to the descriptions of these growths as given in the text-books and monographs on the subject. The general statement is that these tumours are formed by hyperplasia of the whole stroma, so that the organ is converted into a hard tumour retaining more or less the original shape of the ovary. Five specimens, varying in size from a small growth the size of a hen's egg up to a large tumour of over four pounds in weight, are described in detail. In all of them the new growth has arisen within the ovary, and affected only a portion of the stroma, leaving a considerable part of the organ as a separate and easily recognisable structure. The microscopic appearances are also noted, and a short clinical history of the cases from which they were obtained is added.

After looking through a large number of recorded cases of fibroma and fibro-myoma of the ovary, some fifteen or sixteen are selected as similar to those described in the paper, and a short abstract of them is given. When such specimens have been shown at societies, they have given rise to some discussion from the unusual persistence of a portion of the ovary. The number of instances quoted, together with the five specimens under review, is sufficient to show that the descriptions usually given are misleading.

While the difficulty of detecting unstriped muscle-cells among

fibrous tissue cells is acknowledged, the evidence of a comparative examination of sections from these tumours appears to be in favour of their being considered fibromata. The sections provide a very good opportunity of contrasting the minute structure of the growth with the ovarian stroma from which they have originated; the results of such a study are adduced in favour of considering these firm hard growths of the ovary as simple fibromata, and not as fibro-sarcomata. The question of these tumours arising from a chronic oöphoritis is discussed very briefly, and the importance of the tunica albuginea in forming a strong covering to ovarian growths is pointed out.

In conclusion, the fibromata of the ovary are divided into three classes for purposes of description.

(1) The ovary is entirely replaced by the new formation. This occurs in small as well as large growths, and therefore does not depend on the size to which the growth has attained.

(2) A local growth of the stroma leaving part of the ovary unaffected, except by compression. The growth tends to remain within the capsule of the ovary.

(3) Pedunculated fibromata like subperitoneal fibroids of the uterus. These may either have originated in the stroma and later been extruded, or they may be growths of the tunica albuginea.

These specimens of fibroma or fibro-myoma of the ovary seem to deserve some attention from the fact that they do not correspond to the usual descriptions of such growths as given in the text-books and monographs on the subject. In all of them some part of the ovary can be recognised as a separate structure, more or less spread out over the growth, while the Fallopian tube and mesosalpinx remain free.

Leaving out of consideration the small fibrous nodules and the superficial and corpus luteum fibromata, the account of ovarian fibromata as generally given is, that they are formed by a fibrous transformation of the stroma, by which the whole organ is converted into a hard tumour, retaining more or less the original shape of the ovary. For instance, the description in Allbutt and

Playfair's 'System of Gynæcology' is as follows:—"As they are formed by hyperplasia of the whole stroma, they maintain the general contour of the ovary. As a rule they are freely movable, having no adhesions, and are surrounded by fluid. The oviduct, though often thickened, apparently by simple hyperplasia, is not stretched over the growth, as in the case of cystic tumours, but lies free, because the mesosalpinx is not opened up by the growth." * Virchow, as will be referred to later, gives an account more in accordance with what is found in the specimens under review, but the more recent works keep closely to the quoted description, though some mention a variety of "circumscribed fibromata;" these, however, are small fibromatous nodules, of no clinical importance, and evidently not parallel to those forming the subject of this paper.

In the monographs and papers on this subject a very similar version is found. Coe † says, "These fibromata originate, not by a local change, but as a result of a general hyperplasia of the ovarian stroma." Stratz,‡ speaking of dermoid tumours of the ovary, considers the stroma as a whole as the seat and origin of the new growth, the organ thus becoming equally enlarged in all directions, while the true ovarian tissue disappears entirely. In an exhaustive paper on the "Pathological Anatomy of the Solid Tumours of the Ovary," Dartigues § says that the fibromata and fibro-myomata are not encapsuled like those of the uterus, but are rather of the nature of a complete fibrous degeneration of the ovary,

* Griffith, article on "Diseases of the Ovary," p. 843; compare also Pfannenstiel in Veit's 'Handbuch der Gynäkologie,' p. 388; Orthmann in Martin's 'Handbuch,' Bd. ii, p. 633; Gebhart, 'Pathol. Anat. der weiblichen Sexualorgane,' p. 378; Pozzi, 'Traité de gynécologie,' p. 872, etc.

† Coe, 'Amer. Journ. of Obstetrics,' vol. xv, 1882, p. 877.

‡ Stratz, 'Gynäk. Anat.: die Geschwülste des Eierstockes,' Berlin, 1894, pp. 3 and 24.

§ L. Dartigues, "Étude étiologique et anatomo-pathologique des tumeurs solides de l'ovaire," 'Revue de gynécologie et de chirurg. abdom.,' tome iii, 1899, p. 601.

which is uniformly hypertrophied in such a way that its shape and connections are not altered. He, however, mentions, as not in accordance with this account, a specimen of Mundé's * where the fibroma seemed to have grown at the expense of a part of the ovary, while the rest of the organ remained intact and normal.

These examples will serve as a short summary of the usual description of fibrous tumours of the ovary. Though no doubt true of the great majority of these tumours, these descriptions do not hold good for the five specimens under review; and, as I have collected records of several others of a similar nature from the literature, it is evident that in order to be quite accurate they should be considerably modified.

When the first of these specimens came to my notice, I was somewhat puzzled to make out the origin and exact connections of the growth, as it did not correspond to any examples of these tumours I had seen before, nor to the accounts of them as given in the books. The other and smaller specimens, which I obtained later, made it plain that they all belonged to the same type of fibroid tumour of the ovary. The difficulty I had in finding an accurate account of them, has appeared to me to justify my describing them at some length, so I propose first of all to give an account of the naked-eye and microscopic appearances of each specimen, together with a short clinical note of the cases from which they were obtained, and afterwards to discuss any deductions which may be made as to the nature and classification of these tumours.

Three of the specimens came under my notice in the course of my work as Pathologist to the Chelsea Hospital for Women, and I am indebted to those members of the staff, under whose care the patients were, for their kind permission to use the material. The other specimens were kindly given me for inclusion in this series by Dr. Tate and Mr. Bland-Sutton.

* Mundé, 'Amer. Journ. of Obstetr.,' 1889, p. 282.

Specimen No. 1 weighs just over 4 lbs., and measures $7 \times 7\frac{1}{2} \times 4$ inches. It is roughly globular in shape, and except for some ragged tags of adhesions, is smooth and regular externally. Attached to it is the Fallopian tube, $3\frac{1}{2}$ inches in length, lying free from the tumour, and apparently quite normal; the fimbriated end is patent, and the ovarian fimbriæ can be traced running down on to a portion of the ovary lying on the surface of the growth. About the fimbriated end are a number of small subserous cysts, the largest of which, when fresh, was about the size of a pigeon's egg.

The mesosalpinx connecting the tube with the tumour is $1\frac{1}{4}$ inches in depth, and though somewhat ragged, apparently from adhesions, is complete, and does not appear to have been opened up by the growth, though, as usual in ovarian tumours, its layers of peritoneum may be traced for a short distance on to the surface of the growth. At the attachment of the mesosalpinx and just below the peritoneal opening of the tube is the expanded fibrous and atrophic ovary; on section it shows a few small cystic spaces and some fibrous scars, and measures $\frac{5}{8}$ of an inch in thickness and about $1\frac{3}{4}$ inches in length; it is stretched out over a part of the tumour, but is separated from it by a layer of loose connective tissue, which allows its easy separation from the underlying growth by simply inserting the handle of a scalpel. At its thinned out borders the ovary becomes continuous with the white fibrous capsule of the growth.

On section the tumour shows a uniform structure, except in a few places where degenerative changes of a cystic nature have taken place. In the neighbourhood of the pedicle the expanded ovary forms the only capsule to the growth; elsewhere there is a smooth white capsule, which is best marked round the thinned out margin of the ovary, where it can be easily stripped off as a separate layer, but becomes thinner and less separable as it passes over the tumour, until it is recognisable only as

a thin white layer on the surface, and too intimately blended for removal to be possible.

There are several areas where cystic degeneration has taken place,—one, the largest noted, was just under the capsule, and measured 3 × 1¼ inches; it contained a clear glairy fluid and some white stringy material, which formed bands across the cavity and lined its walls. This space was exactly similar to the cavities seen in a uterine myoma which has undergone cystic degeneration.

Portions of the growth and of the ovary were submitted to microscopical examination.

The growth is made up of irregular spindle-cells, with much fibrous stroma. In some parts there is abundance of nuclei and little ground substance; in other parts the nuclei are sparse, and the fibrous stroma abundant. In the cellular portions the nuclei are seen to be oval and spindle-shaped; in some places they run in intersecting bundles, and here they are more elongated and drawn out in the axis of the bundle; in other places they are arranged more irregularly, and here the oval and spindle cells predominate. Where the cells are less abundant, and the fibrous ground substance more developed, the nuclei are smaller and more irregular in shape, often having a somewhat crinkled appearance. Though there are no vessels with muscular walls, the growth is well supplied with capillary blood-spaces, in which a definite lining epithelium may often be seen. The surrounding tissue is also arranged round them so as to form fairly definite walls, and in this way the blood-channels are much more differentiated than is seen in a sarcoma. The thin layer of capsule on the surface is formed of parallel layers of fibres, with very few cells and no vessels.

The section of the ovary shows follicles with remains of the membrana granulosa, scars, and a dense spindle-celled stroma, much more cellular than the growth.

The specimen was removed by Mr. Bland-Sutton from a patient in the Chelsea Hospital for Women. The patient

was a single woman of twenty-seven, who was admitted on September 7th, 1900, complaining of a hard lump in the abdomen, and pain over the sacral region. The lump had been noticed three months before admission, and had appeared first in the right iliac region; it had increased in size somewhat rapidly during the three weeks immediately preceding her admission, though the pain in the sacral region had only been present for a few days. Her general health was good. Menstruation had been of the twenty-eight-day type; the loss being fairly profuse, and extended over three to four days. Three years before admission it had become more frequent, of a three-weekly type, and for a short time had occurred once a fortnight; the amount lost had not changed.

On examination a large solid mass was felt in the abdomen, extending to above the umbilicus, and passing down into the pelvis. *Per vaginam* the mass could not be differentiated from the uterus, and appeared to move with it. The rounded lower end could be felt in the pouch of Douglas, and in the right posterior quadrant of the pelvis. Abdominal section was performed by Mr. Bland-Sutton on September 10th, when the tumour was found to arise from the right ovary. The uterus was pushed over to the left. The tumour was removed in the usual way by ligature of the pedicle and the abdomen closed. No note was made as to the condition of the other ovary, nor as to the presence of ascites. The patient made a very good recovery. She was admitted to the hospital a year after the operation for a stitch abscess. Her health was very good, and no sign of any disease could be detected in the abdomen or pelvis. Shortly after her second admission the patient was married, and has since written to say that she is in excellent health (eighteen months after operation).

Specimen No. 2 weighs 2 lbs., and measures $6\frac{1}{2} \times 4\frac{3}{4} \times 4$ inches. It is ovoid in shape, smooth and regular externally, with a white shiny surface, on which some injected veins may be seen. The cut surface of the

pedicle shows that the tube, mesosalpinx, and the edge of the inner pole of the ovary have been divided in removal. The Fallopian tube, three inches in length, is quite normal; the fimbriated end is patent, and lies just free of the growth, while the ovarian fimbria runs along its surface towards the spread-out portion of the ovary. The mesosalpinx appears to be normal; its two layers are easily movable over one another; its depth measured from the tube to the surface of the tumour is one inch; its peritoneal layers spread out on to the growth for a short distance, and can be moved over the underlying mass. Further out from the attachment of the mesosalpinx, no separate layer of peritoneum can be differentiated, and it is impossible to separate any such layer. The tubules of the parovarium are not visible in holding the mesosalpinx up to the light. The ovary is partly spread out over the tumour, and partly projects from it as a separate body, forming a tail-like appendage to it. Measuring from the cut edge on the free pole of the ovary to the last ovarian tissue clearly recognisable on the tumour, its length is three and a half inches, and its breadth seven-eighths of an inch. The ovary is quite distinct from the growth, and between the two is a definite cellular-tissue layer into which the handle of the scalpel can be pushed, and the ovary in this way detached from the tumour beneath. Part of the ovary is so spread out over the solid mass as to render difficult the exact identification of its limits, though the wrinkled appearance characteristic of the outer surface of the ovary is easily recognisable for some distance over the tumour.

The outer covering of the tumour is pearly white, with fibres running in different directions. From the ovarian fimbria running downwards and then inwards is a line marking a slight depression and forming a V-shaped area, inside which the wrinkled appearance of the ovary is recognisable; from this line, which seems to mark the limits of the ovarian tissue, are fibres radiating out over the capsule of the tumour and giving it an appearance

DESCRIPTION OF PLATE V,

Illustrating Dr. Fairbairn's paper on "Five Specimens of Fibroid Tumour of the Ovary, with Observations on their Pathological Anatomy."

Specimen No. 2, showing the relation of the fibroma to the ovary. The tumour has developed in the outer part of the ovary, leaving the unaffected inner part as a tail-like appendage to the mass.

The loose layer of tissue between the ovary and the growth has been separated, and is seen as a space between the two. A small simple cyst of the ovary has been cut across.

The growth is contained within the ovarian capsule.

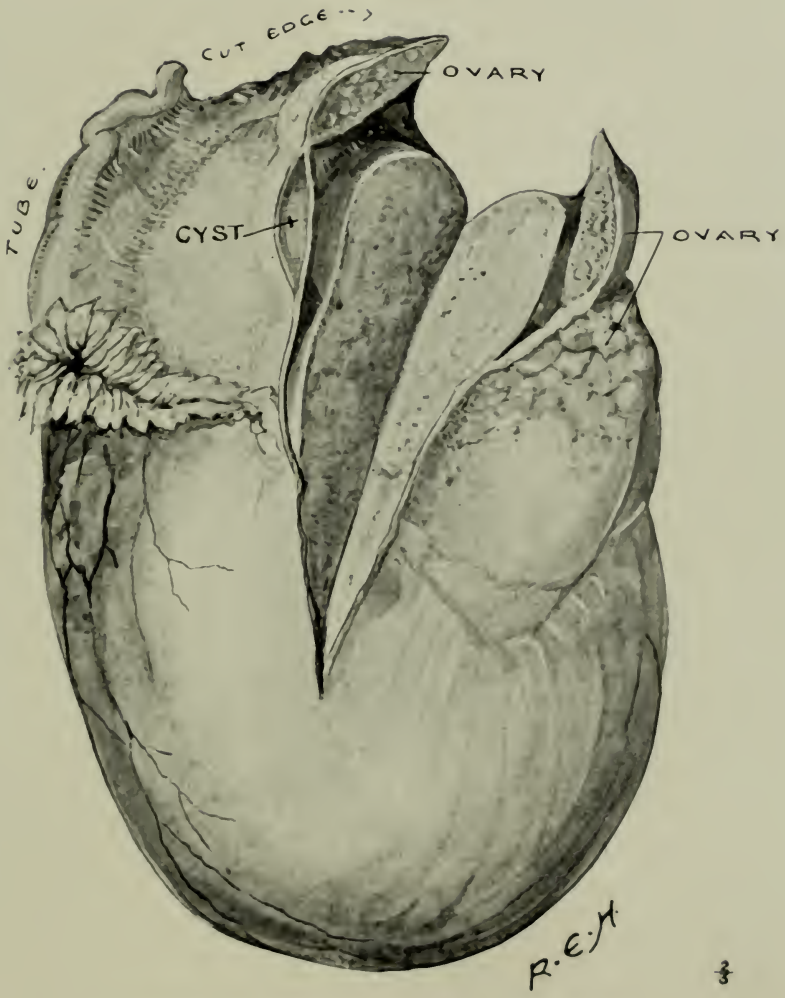

Illustrating Dr. FAIRBAIRN's Paper on Five Specimens of Fibroid Tumour of the Ovary.

Engraved and Printed by Bale and Danielsson, Ltd.

DESCRIPTION OF PLATE VI,

Illustrating Dr. Fairbairn's paper on "Five Specimens of Fibroid Tumour of the Ovary, with Observations on their Pathological Anatomy."

Specimen No. 3, showing a fibroma arising in the ovary and contained within a capsule formed of the expanded ovary and its tunica albuginea. To indicate the loose connection between the two the capsule has been partly separated from the underlying growth.

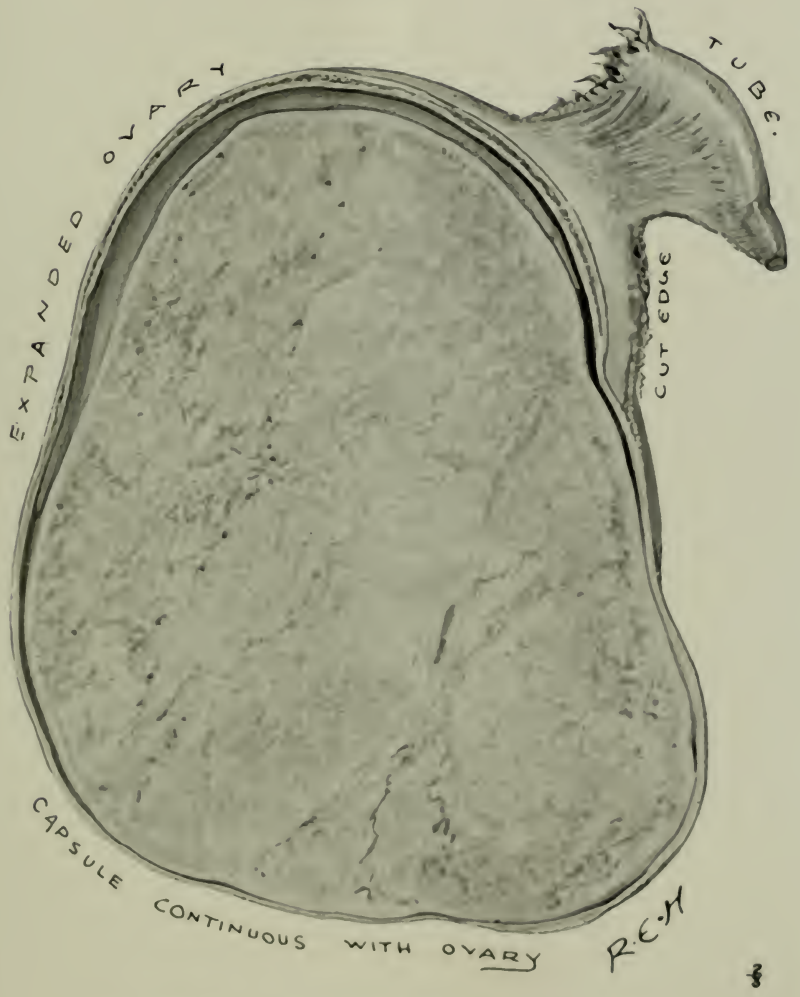

Illustrating Dr. FAIRBAIRN's Paper on Five Specimens of Fibroid Tumour of the Ovary.

Engraved and Printed by Bale and Danielsson, Ltd.

very similar to that seen on the external surface of the heart, where the ventricular fibres spread out from the auriculo-ventricular septum.

On section the tumour is firm, hard, and white, and shows no evidence of any degenerative change. The white fibrous capsule covering it, both from its appearance and from its continuity with the expanded ovary, seems to be formed from the tunica albuginea. Near the ovary it is separable from the growth, but at the opposite point of the circumference is firmly attached to the underlying tissue.

A portion of the growth with the ovary spread out on its surface was taken for microscopic examination. It is seen to be made up of intersecting bundles of elongated spindle-cells running in all directions, so that the nuclei are cut across in many different planes. The nuclei are very abundant all over the section, but where they are least crowded together, a well-marked stroma of wavy fibrous tissue may be seen. The growth is well supplied with blood-vessels, which in places have well-marked walls made up from the surrounding tissue, the nuclei arranging themselves parallel to the vessels when seen in longitudinal section, and concentrically round them in transverse section. Between the growth and the ovary is a layer of loose-meshed connective tissue, with numerous lymph and blood spaces. The stroma of the ovary is similar to that of the growth, except that the spindle-cells are smaller, and the bundle arrangement not so well marked.

The tumour was removed by Dr. Fenton from a patient, a single woman of thirty-four, in the Chelsea Hospital for Women. The patient was admitted to the hospital complaining of a lump in the abdomen, dysmenorrhœa, and frequency of, and difficulty in, micturition. Menstruation was regular, lasting three or four days. The periods had slightly increased in amount for some time before admission, but there had never been any floodings. Eight years before, pain had been noticed in the right side.

There had been trouble with micturition for five years, at first only at the time of the periods.

On examination a hard tumour was found in the abdomen reaching halfway to the umbilicus. *Per vaginam* the cervix was small and lay to the front, and behind it was a hard solid mass impacted in the pelvis, and capable of only slight mobility. Laparotomy was performed, and the tumour with some difficulty delivered from the pelvis; it had a long pedicle, and was found to be blended with the right ovary. The pedicle was ligatured and the tumour removed. The patient made an uninterrupted recovery.

Specimen No. 3 differs from the others in that the ovary is more spread out, and instead of appearing as a definite mass on the tumour, only forms a thick capsule over part of it. It weighs 2 lbs. 5 oz., and measures $6\frac{1}{2} \times 4\frac{1}{4} \times 3\frac{1}{2}$ inches. It is of an ovoid shape, white and smooth on the surface, though showing a slightly lobulated appearance in places. The Fallopian tube, with mesosalpinx, is present with it. The tube is normal; its length is three and a half inches; the fimbriated end is patent, and the ovarian fimbria is seen running down on to the surface of the growth. The depth of the mesosalpinx is one and a half inches, and it is not in any way opened up by the growth. The cut edge of the pedicle runs out from the base of the mesosalpinx over the surface of the tumour for two and a half inches. On section the growth is very hard, and of a fibrous appearance; it is fairly uniform in texture, showing lighter spots surrounded by fibrous bundles, which stand out from the cut surface, and feel very hard, though not gritty. The ovary is seen to be spread out over the surface of the growth; when fresh cut, it was of a watery and œdematous appearance, and contained several small cystic spaces: it is thickest just below the attachment of the mesosalpinx, measuring at this point three-eighths of an inch in thickness, and from there becoming thinner and thinner as it passes over the circumference of the growth. The

spirit in which the specimen has been preserved has had the effect of shrinking up the ovarian tissue, but it has brought out the distinction between it and the tunica albuginea, so that the continuity of the latter with the capsule covering the growth can be very well seen. This capsule is continuous right round the tumour; where the stretched-out ovary is present it can be seen on the surface of the ovary, with immediately below it the thin layer of ovarian stroma containing a few minute cysts, and quite distinctive in appearance; between this and the growth is a definite plane of separation, so that the handle of a scalpel can be easily run in between the two. Ovarian tissue can be recognised below the white capsule over quite one-third of the circumference of the tumour; elsewhere only the capsule continuous with the tunica of the ovary is seen, and is everywhere capable of being stripped off the underlying tissue, though with more difficulty at the end of the tumour opposite to the pedicle.

In this case, also, a portion of growth with the attached layer of ovarian tissue was taken for microscopic examination. The growth contains much more wavy fibrous tissue than in the previous specimens; in many places the cells have almost completely disappeared, but there is a patchy distribution of deeply stained nuclei, of the same elongated spindle form, running in intersecting bundles. In those places where the tissue is mainly fibrous many faintly stained cells are seen of irregular shape, lying frequently in a small empty space, and evidently undergoing a retrograde change. Vessels with completely formed muscular walls are present, and as round them, the nuclei are usually well stained, a good opportunity is offered to compare the cells forming their walls with those of the tissue. On examining a transverse section of these vessels, the cells of the surrounding tissue appear to be concentrically arranged round the lumen of the vessel, and no distinction can be drawn between the cells of the vessel walls and those of the tissue itself. The ovary is atrophic and fibrous, and is much less

cellular than in the other cases; between the growth and the ovary the same loose tissue is present as was seen in the previous specimen.

The tumour was removed by Dr. Tate from a woman of fifty. The patient had been married twenty-one years; the external genitals were undeveloped, there was no vaginal canal, and menstruation had never occurred. The tumour had been noticed for five years, and had been increasing in size more markedly for a year or so before the patient came under observation. There had been discomfort in holding the water for four or five years, and inability to hold it for some months. On examination, a hard smooth tumour was felt reaching halfway between the umbilicus and pubes. *Per rectum* the tumour felt hard and nodular, and was firmly impacted in the pelvis. A cord was felt in the situation of the uterus and cervix. At the operation the tumour was impacted in the pelvis, from which it was brought out with a gurgle. It was attached by a broad pedicle to the right uterine appendages; there was no ascites; the uterus was represented by a cord the thickness of the little finger. The left uterine appendages were not seen. The tumour was removed, and the patient made an uninterrupted recovery. Six months after the operation she reported herself as perfectly well.

Specimen No. 4 weighs 8 oz., and measures $3\frac{3}{4} \times 2\frac{3}{4} \times 2\frac{1}{4}$ inches. It is somewhat globular in shape, and the ovary with a small cyst is plainly seen on its outer surface. The tube is healthy, and the fimbriated end is patent. The inner end of the mesosalpinx is free, but the outer end has been expanded by the growth so that the outer inch and a half of the tube is closely applied to the ovary, while the inner two and a half inches are free. At the inner end, the mesosalpinx is one inch in depth, gradually becoming less towards the outer end.

On section the ovary is seen to be perched on the outer surface of the tumour; at its thickest part it is one inch in thickness, and in it is a small follicular cyst which con-

tained a little blood-stained fluid. On further examination the thinned-out ovarian tissue can be traced right round the whole circumference of the tumour, and the connection between the two is found to be sufficiently loose to allow of the tumour being shelled out of its ovarian bed. The growth itself is hard and fibrous, and cuts like a uterine myoma; the appearance of the intersecting bands seen on the surface of the section is also very similar to that seen on section of a uterine tumour.

A portion of growth with the adjoining ovary was again taken for microscopic examination. It is so exactly similar to that of No. 2 that a full description is scarcely necessary. It shows the same elongated spindle-cells, crossing and recrossing in all directions. There is little fibrous stroma, and a plentiful supply of blood-channels, formed exactly like those of the other specimens. The same widely meshed tissue is present between the growth and the ovary. The nuclei of the ovarian stroma do not show the same bundle arrangement as in the growth, but are rather collected into irregular masses, and individually they are smaller, of a fusiform or oval shape, and not drawn out as in the growth.

The tumour was removed by Dr. Eden from a patient in the Chelsea Hospital for Women. She was a married woman of thirty-nine, who had had one child and one miscarriage, and was admitted in September, 1901. Ventro-fixation of the uterus had been done on account of prolapse in 1891, perinæorrhaphy in 1893, and ventro-fixation a second time in 1895. She had afterwards worn a ring. She came up to the hospital on account of bearing-down pain and discomfort, which made her think that the uterus was coming down again. On examination a small solid tumour, the size of a cocoa-nut, was found in the pouch of Douglas, causing very considerable depression of the vaginal walls. It was thought to be ovarian, and abdominal section was therefore performed on September 30th. The uterus was found firmly adherent to the anterior abdominal wall. The growth was found

to be one of the left ovary with a very short thick pedicle. There was no ascites. The patient made a good recovery.

Specimen No. 5 is the smallest of the series. It is about the size of a hen's egg, and measures $2\frac{1}{2} \times 1\frac{5}{8} \times 1\frac{1}{4}$ inches. It is oval in shape, smooth on the surface, and slightly nodulated at one pole. Just below the pedicle is a slight peak with a wrinkled surface, which appears to be the inner end of the ovary. On the surface opposite to the attachment of the pedicle are some very fine silky adhesions. The upper half of the tumour below the ovary is smooth, with a slightly marked depression running obliquely round it and forming a slight shoulder on it.

The portion of Fallopian tube removed with it measures three inches, and is quite normal; the ovarian fimbria can be seen running down on to the surface of the tumour. The mesosalpinx is one and a quarter inches in depth, and is complete; the tubules of the parovarium are plainly seen. The cut edge of the pedicle takes in tube, mesosalpinx, and inner pole of ovary, so that the ovarian ligament has been cut away.

The tumour cuts with a creaking sensation, and shows on section a firm greyish-white surface, with lighter strands showing up as an irregular meshwork. It has an appearance very characteristic of a hard fibroma. The pinker and softer ovary stands out in relief on the upper surface just below the attachment of the pedicle, and has the "cocked-hat" appearance of the adrenal on the kidney. A yellow-stained corpus luteum is plainly seen on its cut surface. There is a distinct plane of separation between the ovary and the tumour. The ovary measures one inch and a quarter in length by half an inch in thickness. At the margin of the ovary a thin white capsule can just be recognised, but it becomes so intimately blended with the rest of the tumour that it cannot be made out as a distinct structure at a short distance from the ovary.

A portion of the growth with the adjoining ovary was taken for microscopic examination. The growth is seen to be made up of interlacing strands of cells with oval nuclei, which are drawn out in the direction of the bundles. The nuclei are everywhere abundant, and there is also much wavy fibrous tissue. It is well supplied with blood-vessels with distinct walls, the cells of which cannot be differentiated from those of the tissue. There is the same layer of loose-meshed areolar tissue between the growth and the ovary. The ovarian stroma shows a similar structure to that of the growth, except that the cell nuclei are smaller and more irregularly grouped, and the bundle arrangement is not so well marked. Several fibrous corpora lutea are present, and the columnar epithelium on the surface of the ovary is seen in places.

Mr. Bland-Sutton has furnished me with the following history of the case :—The patient, a married lady of thirty years of age, is the mother of three children. The last confinement was in December, 1900, the child being stillborn. During the last pregnancy she suffered great pelvic pain and numbness in the left leg. After delivery the numbness disappeared, but the pelvic pain continued, and this eventually led to an examination and the detection of an enlarged left ovary lying low in the recto-vaginal fossa. In February, 1902, I performed cœliotomy. The lower third of the ovary was lodged in the recess of the recto-vaginal fossa beside the rectum. The weight of the ovary had stretched the Fallopian tube, so that it exceeded the length of its fellow by about 3 cm. At the time of the operation the surface of the ovary lodged in the recess and presented a covering of delicate villous tufts. The right ovary and tube were normal in size and position. No ascites. Recovery uneventful.

To sum up, these specimens show a solid tumour of a simple connective-tissue type arising within the ovary, and leaving on its outer surface a variable quantity of ovarian tissue as a separate, distinct, and easily recognis-

able structure. Where a capsule to the growth can be made out—and this is possible in the first four—it is continuous with the outer surface of the ovary, and evidently formed from its tunica albuginea. The loose plane of tissue between the portion of ovary remaining and the growth beneath admits of easy separation; where the white capsule is the only covering it may be too firmly bound down to admit of removal, as in specimens Nos. 1 and 2, or it may be stripped off with some division of its deep attachments, as in No. 3: in No. 4 the growth can be separated all round from its ovarian bed, showing that it could be enucleated from the ovary like a fibroid from the uterus. Indeed, in all these tumours the relation of the new growth to the ovary is very similar to that of a myoma to the wall of the uterus.

In none of them does the tumour appear to have arisen in the hilum; the mesosalpinx is not opened up to any appreciable extent; the amount of ovarian tissue left is greatest at the attachment of the pedicle. In Nos. 2 and 5 the growth seems to have arisen in the outer end of the ovary, as the inner pole is left free and unaffected, and has been cut through in the division of the pedicle. Attention also may be drawn to the fact that ascites was absent in all these cases. In the first two cases no mention was made of its presence or absence in the notes, but I afterwards ascertained that it was not present in either.

Owing no doubt to the rarity of ovarian fibromata, many examples of these tumours have been put on record. In order to obtain some idea of the frequency of the type of tumour seen in these specimens, I have looked up a large number of recorded cases, and have collected some fifteen or sixteen similar to those under consideration. For the most part they are found in the 'Transactions' of societies where they have been shown, and in this event have usually given rise to some discussion from the very fact of their involving only part of the ovary. I

propose to give a short abstract of such cases as I have come across, and also to note any opinions which have been expressed on the subject.

In the 'Transactions' of this Society, I have found only one parallel case. This is a fibroma of the left ovary, discovered post mortem, and recorded by Crawford in 1894.* It was the size of an orange, and weighed six and a quarter ounces; on section it was solid throughout, "while the ovary, from the hilum of which it apparently arose, was spread over the tumour from the attachment of the pedicle." The right ovary was normal, and there was no ascites. A specimen described by Rutherfoord † in 1892, in which some doubtful granular material, thought to be the remains of Graafian follicles, was seen on microscopical examination, is evidently not on a line with the others.

In the 'Transactions' of the Pathological Society, I have not found any account of a specimen which can be recognised as quite parallel to these five. There are three in which a portion of the ovary was present with the tumour; in two the growth apparently originated from the tunica albuginea, and in the third it was attached by a pedicle to the ovary. In none of them is the growth described as within the capsule of the ovary. The first of these was a small fibroma, one and a half inches in diameter, which was seen on section to spring from the outer layer of the ovarian stroma (tunica albuginea), and was shown by Goodhart ‡ in 1874. The second was shown by Walsham § in 1876. It was obtained from a dissecting-room subject; it was the size of an orange, and is described as having its origin in the fibrous capsule of the left ovary. The third was a large globular fibroid tumour of eight pounds weight, recorded by Crisp ‖ in 1877. It was attached by a small pedicle

* Crawford, 'Trans. Obstet. Soc. Lond.,' 1894, vol. xxxvi, p. 190.

† Rutherfoord, ibid., 1892, vol. xxxiv, p. 88.

‡ Goodhart, 'Trans. Path. Soc. Lond.,' 1874, vol. xxv, p. 199.

§ Walsham, ibid., 1876, vol. xxvii, p. 216.

‖ Crisp, ibid., 1877, vol. xxviii, p. 195.

to the left ovary, so that the end of the ovary appeared to form part of the tumour.

The earliest work I have consulted is Virchow's* 'Lectures on Tumours,' where a small fibrous growth of this type is described and illustrated. The tumour originated in the free end of the right ovary, and measured 5·5 cm. in length and breadth, and 4 cm. in thickness; attached to it were the ovarian ligament, and the intact portion of the ovary with a thickened tunica albuginea and several corpora fibrosa. Microscopically the growth showed no definite muscle-fibres, but only a thick connective-tissue formation, with small spindle and reticular cells, which had undergone a certain amount of fatty degeneration in places. In discussing ovarian fibromata Virchow says that the ovary may either be completely merged in the tumour formation, so that its origin can only be recognised by its occupying the position of the ovary at the end of the broad ligament, or the tumour formation may be only partial, so that a greater or lesser portion of the ovary remains still recognisable in the structure. In opposition to the descriptions quoted at the beginning of this paper, he says, "according to my experience the latter is the more frequent." He further states that the outer free end of the ovary—the part turned away from the uterus—is the most frequently affected, as appears to be the case in Nos. 2 and 5 in my series. The illustration of Virchow's specimen shows it to be very similar to No. 5. Leopold,† in his paper on the "Solid Tumours of the Ovary," describes them as retaining the special form of that organ, at any rate until they reach about the size of a man's head; and in the single new case of fibroma of the ovary (a small one the size of a walnut) which he added to those he had collected, he states that no trace of ovarian

* Virchow, 'Die Krankhaften Geschwülste' (1867), vol. iii, pp. 224, 225.

† Leopold, "Die soliden Eierstocksgeschwülste," 'Archiv für Gynäk.,' 1874, Bd. vi, p. 189.

tissue could be found. He, however, draws attention to a case recorded by Lücke and Klebs, in which portions of ovarian tissue remained, and says, "Whilst in my case the ovary was completely transformed into a fibroma, in this one the new growth only involved half the ovary; in the sound half follicles were still recognisable." Reference to this case of Lücke and Klebs * shows it to have been another small fibroma, the size of a walnut, in which the growth had involved the half of the ovary turned away from the mouth of the tube.

Mundé † brought before the Obstetrical Society of New York a fibroma of the right ovary, which is described and illustrated in the American 'Journal of Obstetrics' for 1889. From the illustration it appears to be exactly similar to the five specimens described in this paper. "It has the usual pedicle, and at one spot on the tumour the ovary and the portion from which it sprang can be seen."

It weighed 773 grams (or about 1 lb. 11 oz.), and had undergone some cystic degeneration. At the discussion which followed, Coe said that he considered it a rare specimen, as in the cases he had seen the ovary had been uniformly enlarged, and these tumours were supposed to originate from a chronic hypertrophy of the ovary, while this one seemed to have grown from one part of the ovary and to be firmly continuous with the cortex of that organ. Mundé, in reply, mentioned that Gusserow had reported a case of Olshausen's in which the ovary held a similar relation.

Feis ‡ described a case of fibro-myoma of the ovary of the size of a goose egg, and of the shape of the normal ovary, which was surrounded by a firm capsule, which could easily be stripped off the growth, except over a few

* Lücke and Klebs, "Beitrag zür Ovariot. und zur Kenntniss der abdom. Geschwülste," 'Virchow's Archiv,' 41, 4.

† Mundé, 'Amer. Journ. of Obstet.,' 1889, p. 282.

‡ Feis, "Ein Fall von Fibromyoma ovarii," 'Centralblatt für Gynäk.,' 1894, p. 133.

spots where it was firmly adherent. This capsule was found to consist of firm connective tissue, poor in vessels, with below it a layer of looser connective tissue, with its strands widely separated, and rich in vessels. At one part of the surface—that turned towards the uterus—was a Graafian follicle, with its epithelial lining intact, lying just below the capsule. Except for its smaller size this specimen seems to be very similar to Specimen No. 3 in the present series. The growth had stretched out the ovary on its surface, so that its capsule, which was for the most part easily peeled off, was formed from the tunica albuginea and the compressed ovarian stroma. Another point of similarity is the layer of wide-meshed connective tissue containing vessels between the capsule and growth.

Among the eight cases of fibroma of the ovary (in one of which both sides were affected) described by Briggs* is one which involved only part of the ovary. There is an illustration of it in the paper; the account of it (No. 6) is as follows:—"The tumour had a pale reddish-pink colour; it was a spindle-celled fibroma; it lay within the capsule of the ovary, and carried two-thirds of the normal ovary on its surface." The weight of the tumour is not given, but its size is recorded in an accompanying table as four by three inches, *i. e.* a little larger than No. 4 of these specimens, but considerably smaller than the first three. Another case (No. 8) is described by Briggs as a hard tumour, "enclosed in a capsule formed of the remains of the ovary, which could be stripped off the growth, which was so completely calcified that it had to be sawn. After decalcification the portion of the tumour examined showed an almost structureless fibroma." This tumour was also of small size, measuring three by three inches.

Pfannenstiel,† in 'Veit's Handbuch,' states that he had

* Briggs, "Fibroma of the Ovary and Ovarian Ligament," 'Brit. Med. Journ.,' 1897, vol. i, p. 1083.

† Pfannenstiel, "Fibrome und Fibromyome des Eierstocks," Veit's 'Handbuch der Gynäkologie,' Bd. iii, p. 389.

found a perfectly medianly developed fibroma of the ovary of the size of a child's head, to which the unaffected portion of the ovary was attached like an appendix—a description which closely fits the second specimen of my series. He goes on to suggest that such tumours may arise from the radiating bundles of the ovarian ligament in the ovary.

Orthmann,* in 'Martin's Handbuch,' describes a small myoma of the left ovary, measuring in length and breadth 5 to 6 cm., and in thickness 3·5 to 4 cm., which was removed with the uterus at an abdominal hysterectomy for fibro-myoma. The tumour appeared to retain the form of the ovary, but was very hard: opposite the hilum was a small corpus luteum hæmatoma. On section it was seen to be a hard white tumour, surrounded by a capsule, which was thickest opposite the hilum, and which contained corpora lutea and fibrosa, and other distinctive ovarian constituents. The tumour was made up of muscle bundles with connective-tissue between. He considered that it probably represented a pure myoma growing from smooth muscle-fibres in the hilum. Orthmann† also showed a myoma of the ovary (evidently the one just described) at the Gynæcological Society in Berlin, the account of which is reported with the discussion in the 'Transactions' of that Society. In the discussion Pfannenstiel said that he had mentioned such another in his article in Veit's 'Handbuch' (cf. above); while Gessner thought that the fact of the tumour being covered on its outer surface with a layer of ovarian tissue indicated that it had arisen in the ovarian ligament and involved the ovary. In support of this he instanced a specimen which he had put on record‡ of a small myoma of the ovarian

* Orthmann, 'Pathol. Anat. der Ovarialneubildungen,' Martin's 'Handbuch d. Krankheiten d. weibl. Adnexorgane,' Bd. ii, pp. 643, 644.

† Orthmann, 'Verhandlung der Deutsch. Gesellsch. für Gynäk. Versam.,' 1898-9, p. 490.

‡ Gessner, 'Zeitschrift für Geburtsh. und Gynäk.,' Bd. xxxiv, p. 297.

ligament found in a case of fibroma of the ovary. This tumour was about the size of a bean, and was separate from the uterus and from the ovarian tumour; it was proved microscopically to arise from the ovarian ligament. By the further growth of such a tumour the ovary might become spread out over it so as to simulate a myoma of the ovary.

Shober* records the case of "a rounded oval tumour, measuring $5\frac{1}{2} \times 2\frac{1}{2} \times 3\frac{1}{2}$ inches, springing from a portion of the ovary, the unaffected part of which remains intimately connected with the lateral surface near one end of the growth. . . . The capsule, which resembles peritoneum, is too adherent to be stripped off." On microscopic examination this growth was found to be a fibroma. In a specimen described by Weir † remains of ovarian tissue were found, but the details given are not sufficient to allow of this being quoted as an example of this type of ovarian fibroid.

Laidley,‡ in a paper on ovarian fibromata, says that in these tumours "the fibrous growth is never disposed in a bed from which it can be shelled out," and that "they do not form circumscribed new growths, but seem rather to be a fibrous degeneration of the whole ovary, which is so uniformly hypertrophied that its shape and relations are not altered." In the same paper he describes a fibroma of the ovary weighing 2 lbs., and measuring $6 \times 5 \times 3$ inches, where the ovarian origin of the growth was "shown by the remnants of the cortical zone, with distorted and compressed follicles and corpora lutea. It consists of a mass of thick fibrous tissue, with comparatively few connective-tissue cells."

Rouffert § has described a fibroma of the ovary with twisted pedicle, which he considered remarkable, as the

* Shober, 'Amer. Journ. of Obstet.,' vol. xli, 1900, p. 72.

† Weir, ibid., vol. xlii, 1900, p. 383.

‡ Laidley, ibid., vol. xlii, 1900, p. 661.

§ Rouffert, 'Bullet. de la Soc. Belge de gynéc. et d'obstet.,' vol. xi, 1900-1901, p. 34.

solid tumour had developed not, as is usually the case, at the expense of the whole ovary, but only from one of its poles, the rest of the gland preserving its ordinary appearance.

Lauwers* showed at the Belgian Society of Gynæcology and Obstetrics a fibroma attached to the outer extremity of the right ovary, which in size and shape appeared normal. The tumour weighed over 2 kilogrammes (4¼ lbs.), and microscopically was proved to be a pure fibroma. In making some remarks on this specimen, he drew attention to the fact that Pozzi described these tumours as formed by a uniform fibrous hypertrophy of the ovary, whereas this one had developed at the expense of one of the extremities of the ovary. He also recalled Virchow's statement, that this was the usual seat of these tumours, though Pfannenstiel had recorded one arising in the central segment of the ovary.

Piering† describes a fibroma of the right ovary of the size of two fists, on the lower median side of which, close to the pedicle, was a small zone of ovarian tissue with a corpus luteum and some small smooth-walled cysts with papillomatous excrescences on their inner surface.

No doubt a more exhaustive search in the literature would reveal further examples of fibromata or fibromyomata of the ovary similar to the five described in this paper, but a sufficient number has been collected to show that these growths may attain considerable size without affecting the whole organ. At the same time the examination of recorded cases shows that the great majority correspond to the usual description, and that the ovary is entirely taken up in the new growth; while the cases of partial involvement, especially where the tumour has reached any considerable size, are rare. The only record of one of the size of the first and largest of any series which I have been able to find is that recorded by Lauwers, while those recorded by Shober, Laidley, and

* Lauwers, ibid., p. 131.

† Piering, 'Prager med. Wochenschr.,' 1900, No. 42, p. 501.

Mundé are rather smaller than Specimens 2 and 3, and the others for the most part small growths of the size of Specimens 4 or 5.

A few words may be said with regard to the nature of these growths as shown by microscopic examination. The difficulty in deciding between fibroma and fibro-myoma made me take the non-committal title of "fibroid tumours" for the heading of this paper. As an instance of the divergent opinions in the text-books, it may be noted that while Pfannenstiel * groups fibroma and fibro-myoma of the ovary together, and expresses no surprise at the frequent occurrence of muscular fibres, Gebhart † is very sceptical on this point, and advises great caution in accepting the recorded cases of fibro-myoma, though he recognises that many trustworthy observers have described muscle-fibres in fibroid tumours of the ovary. Virchow ‡ says that though these tumours are very similar to those of the uterus in their gross anatomy, in their appearance on cross section, and in their consistence and degenerative changes, they are distinguished from them in their histological structure by the absence or sparse occurrence of developed muscle-fibres. Coe § thinks that the resemblance between microscopic sections of ovarian and uterine fibroids is so close that the differential diagnosis is very difficult, if not impossible. Doran, ‖ by comparing the cells of these tumours with those of the uterus, and of the walls of blood-vessels, endeavours to show how such a distinction can be made, and considers that fibro-myomata may develope in the ovary. Bland-Sutton ¶ states that tumours of the ovary composed mainly of unstriped muscle-fibre, or a

* Pfannenstiel, loc. cit., p. 389.

† Gebhart, loc. cit., p. 381.

‡ Virchow, loc. cit., p. 223.

§ Coe, loc. cit., p. 897.

‖ Doran, "On Myoma and Fibro-myoma of the Uterus, and Allied Tumours of the Ovary," 'Trans. Obstet. Soc. Lond.,' 1888, vol. xxx.

¶ Bland-Sutton, 'Surgical Diseases of the Ovaries and Fallopian Tubes,' Lond., 1896, p. 42.

mixture of muscle and fibrous tissue—fibro-myomata,—are more frequent than the pure fibromata, though they are not by any means common; and Dartiques * that fibro-myomata constitute the great majority of the simple solid tumours of the ovary, while the pure fibroma and pure myoma are very rare. The difficulty of distinguishing these two kinds of cell is not remarkable when we consider that the smooth muscle-cells forming the walls of vessels and other structures are formed originally from specially differentiated connective-tissue cells, and that in these tumours, where there is no functional activity, their development never reaches that of well-formed muscle-fibre, while retrograde changes soon take place, and add greatly to the confusion. Virchow † draws attention to the difficulty of separating these small, poorly developed, and atrophic muscle-cells from connective-tissue corpuscles.

Looking at these specimens for evidence of the presence of muscle-cells, it may be noted that in none of them does the surface section show the concentric or whorled appearance so characteristic of the uterine growth, though the very distinct interlacing bands on the cut surface of No. 4, and to a less degree of No. 5, are similar to what is frequently seen in these tumours.

Microscopically the sections show a very similar structure in all: in No. 1 the growth is older, and the cells have undergone some degenerative change, and there is more extensive formation of connective-tissue ground substance; in No. 3 there is also much well-formed wavy fibrous tissue, but in the patches where the nuclei remain, the structure is seen to be exactly like that in Nos. 2, 4, and 5. In these three the bundles of cells with elongated nuclei running in strands in all directions are, in their general aspect, very similar to what is seen in a section of a uterine myoma, and suggest a fibro-

* Dartiques, loc. cit., p. 612.

† Virchow, loc. cit., p. 223.

myomatous structure, especially in the light of Doran's paper, where the sinuous bands of fibres with small elongated fusiform nuclei lying in their long axis, as seen in a fibroma, are contrasted with the straighter rows of muscle-cells with larger nuclei seen in a myoma. On the other hand, the extensive formation of fibrous tissue, best seen in Nos. 3 and 5, is greatly in favour of the growths being purely fibromatous. Where the cells have disappeared in No. 3, the growth is entirely made up of wavy fibrous bands. There is nothing suggestive of muscular tissue in No. 1.

In this way a comparative study of the histology of these growths tends to show that they are all fibromata of a very cellular character at first, later becoming more fibrous, and that they are closely formed on the type of the ovarian stroma, in which they have arisen.

Also it is evident that what one observer would call a fibroma another might describe as a myoma or a fibro-myoma, and we must, therefore, consider cases recorded under any of these headings as all belonging to one group of tumour.

The other and clinically more important question of fibro-sarcoma has not been considered in regard to these cases. Specimen No. 1 is the only one in which the microscopic appearances might give rise to some uncertainty between a fibroma and a fibrifying sarcoma. Its cells are somewhat irregular in shape and arrangement, though this is rather the result of a retrograde change than a primary characteristic of the growth. In its more cellular, and therefore more active parts, the same well-marked bundle arrangement, as is seen in the others, is present, and, where the cells are few and irregular and degenerate, much fibrous stroma has been developed. The vascular channels are better differentiated than in sarcomatous tissue. Also the after history of the case, with eighteen months' good health after removal of so large a growth, is in favour of its being simple.

In these specimens the question of malignancy scarcely

requires consideration. Apart from the histological examination, the appearance of the cut surface, the hard, firm, well-circumscribed nature of the growth—which has not invaded the ovary, but has merely expanded it,—the absence of adhesions and ascites, and of any serious effect on the health of the patient, all go to prove their innocence.

The after histories collected by Doran,* Briggs,† and others afford sufficient evidence to show that these firm hard tumours of the ovary, even when they have reached a considerable size before removal, have no tendency to recur. Still, reference to Doran's paper demonstrates the uncertainty about the result of the microscopic examination which occurred in several of the cases which he quotes.

The first case in Doran's table is one of Cullingworth's,‡ which was first reported on by Dreschfeld as fibroma, and afterwards on examination by a committee of the Obstetrical Society, consisting of Doran and Knowsley Thornton, pronounced sarcoma, and on a still later re-examination by Doran decided to be a fibroma. Another is a case of Handfield-Jones §—a tumour of stony hardness—in which sarcoma was suspected from the microscopic examination, though later this proved unfounded. An equally instructive case in this paper is one recorded by Cullingworth ‖ and reported on by Shattock as fibro-sarcoma. Five years after removal there was no sign of recurrence, so another examination was made by Shattock, and the tumour again pronounced a fibro-sarcoma. Dr. Cullingworth informs me that this patient has no sign of recurrence up to the present time, *i. e.* nearly eleven years

* Doran, "Fibroma of the Ovary and Ovarian Ligament," 'Trans. Obstet. Soc. Lond.' for 1896, vol. xxxviii, p. 187.

† Briggs, loc. cit.

‡ Cullingworth, "Fibroma of both Ovaries," 'Trans. Obstet. Soc. Lond.,' 1879, vol. xxi, p. 276; Report of Committee on same, p. 314.

§ Handfield-Jones, "Fibro-sarcoma of the Right Ovary," 'Trans. Obstet. Soc. Lond.,' 1889, vol. xxxi, p. 126.

‖ Cullingworth, 'Trans. Obstet. Soc. Lond.,' vol. xxxvi, 1894, p. 314.

after operation. Horrocks* mentions another case where the same thing happened.

The fact that these tumours often contain elements very suggestive of sarcoma tissue, and that they bear so striking a resemblance to sarcoma in other parts, is the cause of this uncertainty, and it may be argued that it is more correct to look on them as fibro-sarcomata, though much less malignant than sarcoma elsewhere. This is the position taken up by Bland-Sutton† when he states that "so-called fibromata of the ovary are so rare, and in naked-eye and microscopic characters so allied to slowly growing spindle-celled sarcomata, that they will be discussed with the sarcomata," and classes even the hard tumours with a glistening tendinous-like surface, and with the whorled arrangement of uterine fibro-myomata, under the heading of sarcomata. On the other hand, connective-tissue growths will vary in appearance according to the character of that tissue in the organs from which they arise, and it is surely more reasonable to consider the special features of the ovarian stroma as the cause of this doubt as to the exact nature of these tumours. Many observers have laid stress on this. Coe,‡ in describing the structure of an ovarian fibroma, says, "It presents the ordinary connective-tissue basis of the class to which it belongs, showing, however, a higher grade of development than is possessed by similar tumours elsewhere in the body, as denoted by the prevalence of cellular elements, so that in another locality it might have been called a sarcoma; but, observing its close resemblance to the normal organ, we recognise it as a true fibroma, stamped with the peculiar marks of its origin." Griffith§ has also called attention to the difficulty in determining the nature of a growth arising from the pure spindle-celled structures with little

* Horrocks, 'Trans. Obstet. Soc. Lond.,' vol. xxxviii, 1896, p. 208.

† Bland-Sutton, 'Tumours, Innocent and Malignant,' Lond., 1901, pp. 67 and 125.

‡ Coe, loc. cit., p. 572.

§ Griffith, 'Trans. Obstet. Soc. Lond.,' vol. xxx, 1888, p. 432.

fully developed fibrous tissue, which forms the ovarian stroma, and advised that the general characteristics should be considered as well as the results of the microscopic investigation.

In the sections which I have shown a very good opportunity is afforded of comparing the growth with the ovary from which it has arisen, for both are present on the one slide. It will be noticed that, as a rule, the ovarian stroma is more cellular, that the nuclei are smaller, and that there is not that tendency to bundle formation which is present in the growth. Otherwise the elements are so similar that there can be little doubt that these tumours have started as a new growth of a portion of the ovarian stroma, and that they recall the type of tissue from which they originate.

The probability, then, is rather that many cases considered as fibro-sarcoma from their abundance in spindle-celled elements are really fibromata or fibro-myomata ; and that, as Doran * and Briggs † have stated, the hard, heavy, circumscribed connective-tissue growths of the ovary belong to these innocent orders.

Besides showing that ovarian fibromata need not arise as a general hyperplasia of the stroma, but may develop as a localised growth in the ovary, like fibro-myomata in the uterus, these specimens suggest a few words on the question of their origin from a preceding condition of chronic oöphoritis. Virchow ‡ considered that the part of the ovary not involved in the tumour formation showed the changes due to a chronic oöphoritis as indicated by the induration of the stroma, the thickened and sclerotic albuginea, and the conversion of the follicles into corpora fibrosa, and his views have been copied freely by subsequent authors. No doubt the unaffected portion of the ovary shows these changes, but they are no more than would be expected as the result of the compression

* Doran, 'Trans. Obstet. Soc. Lond.' for 1896, vol. xxxviii, p. 187.

† Briggs, loc. cit.

‡ Virchow, loc. cit., p. 226.

and expansion caused by the tumour growth. A general fibrous hyperplasia could be more easily understood to arise in a chronic inflammatory process, but a localised growth from a portion of the stroma can scarcely be accounted for satisfactorily in this way. Further, the absence of adhesions or disease of the Fallopian tube, or other evidence of previous pelvic peritonitis, helps to show that the sclerotic condition of the ovary is a secondary one.

The part taken by the thickened albuginea in forming a capsule for these growths is a point of considerable interest. Where any reference is made to the presence of a capsule in these cases it is usually described as a more compact layer of connective tissue at the periphery, made up almost exclusively of fibrils with few cells.* In view of the slight anatomical development of the tunica albuginea of the ovary, especially as compared with that of the testicle, it is remarkable how much strength it shows in pathological conditions. In Specimen No. 3, for example, it can be traced right round the circumference of the tumour, and everywhere forms a very distinct capsule to it, though the growth has reached a considerable size. In all of them it appears as a distinct structure near the ovary, but in some it becomes too intimately blended with the underlying tissue to be separated when at some distance from the ovary. This covering of resistent albuginea is seen in many other forms of ovarian tumour; it is often well shown in dermoids, and I have called attention to it in a case of carcinoma of the ovary which I brought before this Society.† Many cases of solid tumour of the ovary will be found to possess such a capsule if carefully examined.

Finally, as the result of an examination of recorded cases, and in the light of the five specimens discussed in this paper, it is possible to recognise three different types

* Compare Borreman, "Fibrome de l'ovaire," 'Bullet. de la Soc. Belge de Gynéc. et d'Obstet.,' vol. vii, 1896, p. 169.

† 'Trans. Obstet. Soc. Lond.,' vol. xliii, 1901, p. 208.

of fibroid tumour of the ovary,—apart from the small surface fibromata and corpora fibrosa.

(1) The first type is that for which the common description holds good. The whole ovary is converted into a hard tumour, maintaining to some degree its original shape, but leaving no recognisable portion of its original structure. It is quite unnecessary to make any further observations on this form, as it is fully treated of in the larger books, but it may be worth while to draw attention to the fact that this complete fibrous transformation of the whole organ does not depend on the size to which the growth has attained. It occurs in small as well as large tumours, and does not seem to depend on the growth having reached a size sufficient to destroy the ovary. Thus Leopold's specimen, referred to earlier, was only the size of a walnut, and he states that no ovarian tissue was present; and Coe's was the size of a pullet's egg, and he states also that there was "nothing remaining to suggest portions of the normal ovary." This would seem to indicate that the pathological change involves the ovary in a different way from what takes place in the next variety.

(2) The second type is that to which the specimens described in this paper belong; the growth forms a hard tumour within the substance of the ovary, which it spreads over its outer surface, so that it is more or less encapsuled within the organ. The amount of ovarian tissue remaining appears to depend on the position in which the growth originates. When it commences towards one or other pole, there is naturally more of the ovary left as an appendage to the tumour; while, if the growth begins in the more central part, the ovary will be more thinned out over the growing tumour, and hence suffer more compression, and be less recognisable. This difference is well shown in Specimens 2 and 3 of this series; in No. 2 the new growth has evidently started in one end (the outer) of the ovary, leaving the other end free as a tail-like appendage; while in No. 3 the growth

is more central, and the ovary is thinned out over a wide area of the circumference, so that its stroma can be recognised over nearly half the tumour, and its tunica albuginea over the whole. Similarly No. 4 is another fairly central growth with ovarian tissue entirely surrounding it, while No. 5 is a small growth from the outer end of the ovary.

(3) There is another type which has not hitherto been touched on in this paper, but which may be mentioned here. This third type includes those pedunculated fibromata like subserous myomata of the uterus. Virchow describes this class of ovarian fibroma, and quotes a specimen, obtained from the post-mortem room, of a flat roundish growth, of the shape of a placenta, which measured 5 to 5·5 cm. on surface section by 2·2 cm. in thickness, and was attached by a short pedicle to the ovary. Crisp's specimen in the 'Transactions of the Pathological Society' seems also to belong to the same class, and very good examples have been recorded by Doran* and Lloyd Roberts.† Keiffer,‡ in describing a somewhat similar specimen, suggests that fibromata of the ovary may follow part of their development in the centre of the gland, and then be extruded towards the periphery and become pedunculated like subperitoneal fibroids of the uterus. Possibly many of these cases are growths from the fibrous capsule of the ovary, like those recorded by Goodhart and Walsham.

Mr. Alban Doran remarked that he had shown three specimens that night in order to support his opinion that fibroma and myoma of the ovary were two different diseases. In the case of the small solid tumour of the ovary, almost a pure myoma, the connection of the growth with the ovarian ligament (which contained muscle-cells from the uterus) was evident. On the other hand, the instructive specimen of a solitary fibroma, only one third of an inch in diameter, showed

* Doran, 'Edinb. Med. Journ.,' May, 1898, p. 449.

† Lloyd Roberts, 'Brit. Med. Journ.,' 1872, vol. i, p. 138.

‡ Keiffer, 'Bullet. de la Soc. Belge de Gynéc. et d'Obstet.,' vol. vi, 1895, p. 56.

that the growth may be a pure fibroma from the first, as pure as in the larger specimen of undoubted fibroma. This little tumour arose, it is important to note, far from the ovarian ligament. The myoma which he had exhibited seemed to come under Dr. Fairbairn's Class 3. Mr. Doran, turning to the relation of fibroma to sarcoma, believed that many fibromata were reckoned as sarcomata; they were merely œdematous, and did not recur. Subtracting these fibromata, which were by no means rare, from malignant tumours, we must come to the conclusion that, as Martin believed, carcinoma of the ovary was more frequent than sarcoma. Mr. Doran asked Dr. Fairbairn why the tube and mesosalpinx so seldom increased in size when attached to a fibroma or other solid tumour. He had, in more than one case, found that the small pedicle, hidden between protuberances in the tumour, was difficult to secure. On the other hand, in the most innocent cystic tumour the tube and mesosalpinx were always hypertrophied.

Mr. Bland-Sutton was particularly interested in this communication, and congratulated Dr. Fairbairn on his good fortune in being able to obtain such a large number of ovarian fibroids, and in establishing the fact that the encapsulation of the tumour could be relied upon as a generic and distinguishing feature. When the fibroid was of moderate size, as in the smallest specimen of his series, the disproportion between the ovary and the tumour was not so marked; but when the mass had a circumference of 20 or even 30 cm. or more, then the small bud-like remnant of the ovary at the uterine end of the tumour appeared very incongruous. The leading features of these tumours could be summarised thus:—encapsulation, ovoid shape, intense hardness, and the whorled disposition of the tissue as displayed on the cut surface. These were a group of signs presented by no other tumour of the ovary, and their clinical value was equal to their simplicity. Our 'Transactions' during the last few years contained many quibbles in regard to the minute structure of these hard tumours. Give us some sign, said the quibblers, whereby we might decide between a spindle-called sarcoma, a fibroma, or a myoma! We reply: Differential staining was unequal to the task, and now we might turn our backs on histological chemistry, and had we only studied the figure of an ovarian fibroid in Virchow's incompleted, it was true, but nevertheless unequalled 'Die Krankhaften Geschwülste' with sufficient care, we should have found therein the means of differentiation. We were, however, "intellectually blind," and Dr. Fairbairn's acumen served to remind us of this unwelcome fact. In future, on removing one of these solid tumours we should hunt for the remnant of the ovary at the insertion of the ovarian ligament, then bisect the tumour in order to ascertain if it were encapsuled and presented a whorled

pattern on the cut surface, and then many would congratulate themselves that they could thus easily (and no less certainly) determine the nature of the tumour independently of the laboratory. There was an important feature by which ovarian fibroids were distinguished from similar tumours in the uterus. It was well established that uterine fibroids did not arise after the menopause, whereas ovarian fibroids occurred in the aged, and on two occasions Mr. Bland-Sutton had successfully removed them at the ages of sixty-four and sixty-six, and the clinical histories indicated that the tumours had only been noticed two years before removal. The extreme hardness of these tumours was a valuable clinical sign, and in one of the cases in Dr. Fairbairn's series Mr. Bland-Sutton was able to diagnose accurately the character of the tumour from this sign alone. The paper was valuable even if only regarded from the point of view that its author had rescued a genus of tumours from a group notorious for containing members with extremely bad characters. It was an excellent paper, and Mr. Bland-Sutton hoped that it was only an instalment of many more of the same good quality.

Dr. W. S. A. Griffith fully agreed with the conclusions arrived at by Dr. Fairbairn in his interesting paper. He had endeavoured to show in the paper referred to by Dr. Fairbairn that all tumours of the ovary, whether cystic or solid, were, in the main structure of their solid parts, connective tissue, derived from and having the essential character of the spindle-celled stroma of the normal organ. Corpora fibrosa are physiologically the ultimate stages of the corpora lutea, and where they are enlarged their structure appears to remain of the spindle character of the normal bodies, and not spindle-celled.

Dr. Briggs (Liverpool) believed that the effect of Dr. Fairbairn's excellent paper would in future be revealed by figures denoting more fibromata and less sarcomata amongst solid connective-tissue tumours of the ovary. Dr. Briggs said he was not aware, when he came to London that day, of the title of the paper, otherwise he would have looked closely into the records of his own materials. He thought he had doubled the eight cases he originally described in his own paper published a few years ago. Amongst his original cases, and amongst recent ones, he had figured and noted circumscribed growths to which Dr. Fairbairn had paid conspicuous attention. The writers were correct in alluding to both diffuse and circumscribed growths. Dr. Briggs suggested that Dr. Fairbairn had shown a want of courage in selecting fibroids, and not fibromata, as the title of the paper founded on the five cases he had described. Mr. Alban Doran's specimen exhibited that night, if not actually a myoma, was the nearest approach in its microscopical characters to a myoma of any he had ever seen.

Dr. Briggs thought that would be a general opinion, which meanwhile, in the face of so much evidence to the contrary, might be held in reserve. The main danger had been, as Mr. Bland-Sutton said, in ascribing malignant properties to cellular structures without adequate clinical proof. In Dr. Briggs' experience this impeachment was not limited to gynæcologists. The proof of the innocence of cellular growths described as fibromata of the ovary had been substantiated by Mr. Alban Doran and himself in the published papers referred to by Dr. Fairbairn. Dr. Briggs cited the case in which he operated almost immediately after he had published his paper. In a girl aged seventeen there was a large brain-like solid growth of the ovary. The girl now lived, and was an active hospital nurse. The tumour was proved to be a highly cellular growth —a myxoma. The rarity, as alleged, of fibromata of the ovary was not justified by facts which had now accumulated. Dr. Briggs added that all his patients from whom he had removed these tumours still lived.

Dr. Herbert Spencer was surprised at the number of writers cited by the author, who regarded ovarian fibroids as diffuse growths involving the whole of the ovarian tissue. His own experience was opposed to such a view, for out of five cases under his own care, in four the growth was very definitely limited to a portion of the ovary, and in the fifth (a large tumour) he thought possibly the tumour was so limited, but without spoiling the museum specimen by a series of thin sections it was impossible to settle this point. Ovarian fibroids were certainly benign growths, and had much in common with uterine fibroids. The latter did not invade the whole tissue of the uterus, but sometimes displaced and compressed it to a remarkable extent. It seemed to him most unlikely that such a benign fibroid growth would invade and destroy the whole of the tissue of the ovary; and, as a matter of fact, in the first case alluded to and in several others he had seen it did not do so. A most interesting point in connection with these growths, not alluded to by any speaker, was their origin. Two of his (Dr. Spencer's) cases suggested, and a third he thought clearly demonstrated the origin of an ovarian fibroid in the tunica fibrosa of a Graafian follicle. This mode of origin had been mentioned by Rokitansky, though he did not know upon what evidence. Patenko's *corpora fibrosa* were, as Mr. Doran had pointed out, merely degenerated corpora lutea, and were entirely different in structure from true fibroids. He (Dr. Spencer) would shortly bring his specimens before the Society.

The President pointed out that these tumours, and also sarcomatous and malignant tumours generally, differed from fibroids in that the cut surfaces remained flat like a cut raw potato, whereas fibroids always became slightly convex on the

cut surfaces immediately on being incised, and this convexity gradually increased in quantity owing to the shrinking of the elastic and muscular fibres. He considered that it was of great importance to be able to say that a given tumour was a fibroma and innocent, or a sarcoma and malignant, and he hoped the work of Dr. Fairbairn would assist in this direction. He mentioned a case he had shown himself, where equally competent observers had expressed diametrically opposite opinions regarding the microscopic sections. So far as he had gathered, the chief distinction seemed to be that in fibromata the blood-vessels were much more clearly defined, but he wished to know if this distinction could be relied upon.

Dr. Fairbairn, in reply, acknowledged the justice of Dr. Briggs' criticism of his use of the term "Fibroid Tumour" in the title of the paper. His original intention had been to keep to the ordinary nomenclature, and to head the paper "Fibromata of the Ovary," but on second thoughts he had adopted the less scientific description in order to obtain a more inclusive term. Although microscopic examination gave no positive evidence of the presence of muscle-cells in these tumours, the intersecting bundles of parallel fibres with elongated nuclei—very well seen in the sections from specimen No. 4—were so suggestive of fibro-myomatous tissue that the possibility of their presence could not be excluded entirely. Further, in discussing the examples of similar tumours in the literature of the subject, many of which are recorded as myomata and fibro-myomata, the wider though less accurate term "fibroid tumour" seemed to serve the purpose better than the more exact one of "fibroma." Mr. Doran's specimen of pure myoma of the ovary was made up of undoubted muscle-fibre, and proved the occurrence of tumours of this type in the ovary. In a mixed growth the detection of muscular tissue was much more uncertain. As he mentioned in the paper, he had tried to recognise muscle-cells by comparing the cells of the growth with those of vessel walls—as suggested by Mr. Doran in a paper read before this Society in 1888,—but he had found himself too lacking in imagination to be able to make out any distinction between them. But that did not appear to prove the existence of muscle-cells, for the extensive formation of fibrous tissue showed that the tumours were largely, if not entirely, made up of fibrous tissue cells. Mr. Doran thought that in his specimen the tumour might have arisen in the ovarian ligament near the ovary. If this were the case its muscular structure was easily understood. In the five specimens on which the paper was based the growth had arisen within the capsule of the ovary; and though tumours of the purely myomatous structure of Mr. Doran's might arise within the ovary from strands of muscular tissue passing in from the

ligament, the type to be expected as the result of a new formation in the stroma would rather be that of a very cellular fibroma.

The convex appearance of the surface of a uterine tumour on section, to which the President had drawn attention, was not observed in the case of these ovarian tumours. This was another point against the presence of muscular elements in their structure. Dr. Fairbairn agreed with Mr. Bland-Sutton that the weight of evidence was greatly in favour of the non-sarcomatous nature of these tumours. The difficulty in deciding on their nature was increased by the degenerative changes which so frequently occurred, and caused differences in the appearance of the cells which were very suggestive of sarcomatous elements. As an example of this, a specimen brought before this Society by Dr. Handfield-Jones some years ago might be quoted. On microscopic examination it was thought to be a fibroma, showing myxomatous and in some parts sarcomatous change. On further examination the growth was acknowledged to be simple.

Another point which had been brought forward in the discussion was the question of the possible origin of these tumours from corpora fibrosa. Dr. Spencer said that he had a preparation which appeared to show a small fibroma, arising in a corpus fibrosum, and which he intended to bring before the Society at a near future meeting. A specimen of this kind would be of great interest, for the structure of these tumours did not at all suggest the likelihood of this mode of origin. It appeared much more probable that a growth of a very cellular connective-tissue type should arise in the ovarian stroma, the elements of which it closely simulates, rather than in the corpora fibrosa, with which it has much less in common.

Dr. Spencer also expressed his surprise at the description of fibromata of the ovary, which had been quoted from the books. Dr. Fairbairn could assure Dr. Spencer that the accounts given in the text-books on gynæcology and pathology, and in the monographs, almost unanimously followed on the lines he had quoted. Virchow's description in the 'Krankhaften Geschwülste,' published in 1867, was certainly far the most accurate in the light of the specimens now before the Society. Probably a more careful examination of such tumours would show that most of them only partially involve the ovary. In the specimen which Mrs. Boyd had shown there was a small portion of what appeared to be ovarian tissue attached to the surface of the growth, together with the cut end of the ovarian ligament. In several other specimens which he had seen recently he had noticed this same thing,—that when a small portion of ovarian tissue is left, it is usually

that portion adjacent to the ovarian ligament. This was exactly what was to be expected from Virchow's description of ovarian fibromata, written nearly forty years ago. Sometimes the ovary is completely merged in the tumour formation; more often there is a greater or lesser portion of the ovary still recognisable. Also the outer free end—the part turned away from the uterus—is the part most frequently affected. In other words, the portion of the ovary nearest the ovarian ligament will be the part most frequently left, and that was certainly the case in the majority of fibromata of the ovary which he had examined.

JUNE 4TH, 1902.

PETER HORROCKS, M.D., President, in the Chair.

Present—51 Fellows and 4 visitors.

Books were presented by the Royal Medical and Chirurgical Society, Madras Maternity Hospital Staff, and the North of England Obstetrical and Gynæcological Society.

H. Simpson Newland, M.B. (Adelaide, South Australia), was declared admitted.

The following candidates were proposed for election:—Jessie George, L.R.C.P., L.R.C.S.Ed.; Mary Thorne, M.D.; Clement White, M.B., B.C.Cantab.; W. Burslem Rotheroe, L.R.C.S. and P.Edin.; Richard Henry A. Whitelocke, M.B., C.M.Ed.; William Henry Breffit Brook, M.D., B.S., F.R.C.S.; Edward Marten Payne, M.B., C.M.

PRIMARY OVARIAN GESTATION.

By A. W. MAYO ROBSON, F.R.C.S.

WHEN I vacated the chair of the British Gynæcological Society in February, 1898, I reported a series of twenty-three cases of ectopic gestation on which I had operated, twenty-two having recovered completely. One of these, operated on in 1892, I thought might have been an ovarian pregnancy, and in the light of recent events I

have little doubt that it really was one; but the specimen having been sent to a pathological laboratory for further examination and report, was unfortunately lost by the porter, hence it was and is impossible to prove it.

I have operated on about fifty cases of extra-uterine gestation, and the specimen I am showing is the only one of the series in which I have been able to prove primary ovarian gestation.

Doubtless many of the cases described previously as ovarian pregnancy have been of that nature, but this is apparently only the fourth case in which absolute proof has been furnished, by showing an early embryo in its membranes and contained in a sac in the ovary.

The other cases are those of Dr. E. O. Croft, published in the 'Lancet' of June 24th, 1899, and reported on in the Obstetrical Society's 'Transactions,' vol. xlii, p. 316, and vol. xliii, p. 24; Dr. Catherine van Tussenbroek's, described in the 'Annales de Gynécologie,' December, 1899; and Messrs. Anning and Littlewood's case, described in the forty-third volume of the Obstetrical Society's 'Transactions,' 1901.

It is a curious coincidence that three out of the four undoubted specimens of primary ovarian pregnancy should come from Leeds.

For the following notes I have to thank my house surgeon, Dr. J. C. Forsyth.

Martha C—, aged 24, was admitted to the Leeds General Infirmary on April 11th, 1902, in a state of profound collapse.

History.—She stated that on the previous night, six weeks after her last menstrual period and a fortnight after missing her menses, she was seized with sudden pain in the right side while engaged in "black-leading" a grate. She became very faint and pallid, and soon vomited. She was put to bed, but the pain continued during the night, and was much worse next morning. The pallor also increased. She was seen by her doctor (Dr. H. Towers), who diagnosed extra-uterine gestation,

and advised her removal to the infirmary. She said she was a married woman but had never had any children, and her husband had been abroad for some months. On admission the patient was very pale indeed. Temp. 98°; pulse 130; respirations 48. She complained of pain on the right of the abdomen, which was distended, and did not move on respiration. It was very tense and tender, rendering palpation difficult, but a fluid thrill could be obtained on flicking with the finger. No tumour could be felt.

Examined *per vaginam* the uterus was found to be fixed, and Douglas's pouch was prominent. There was no history of bloody discharge from the vagina.

A diagnosis of ruptured extra-uterine gestation was confirmed, and immediate operation advised.

The patient was wrapped in warm blankets and taken to the theatre, where she was put on a heated operating table and anæsthetised with ether. The skin of the abdomen was then quickly washed and purified, and a vertical incision made above the pubes. When the peritoneum was opened there was a sudden gush of blood and clot. The right appendage was at once seized and clamped as bleeding was going on, but before it could be brought to the surface it was necessary to detach the Fallopian tube, which was firmly adherent to the bottom of Douglas's pouch, the ovary projecting above the tube, to which it was not adherent in any way. On the top of the ovary there was a firm mass surrounded by clot, and on lifting this from the ovary a cavity was found in the ovary itself, into which the small ovum would easily fit. The left ovary and tube were examined and found to be healthy. The mesometrium was then transfixed, and the tube and ovary removed after ligature. The abdomen was then cleared of clots and washed out with saline solution. A glass tube was inserted into the pelvis, and the wound closed around it in the usual way. During the operation the patient was infused to four and three-quarter pints with saline solution, and had 10 minims of

Liq. Strychniæ and 30 minims of spirit of camphor administered hypodermically. Patient made a rapid recovery from the operation. The glass drainage-tube

Fig. 1.

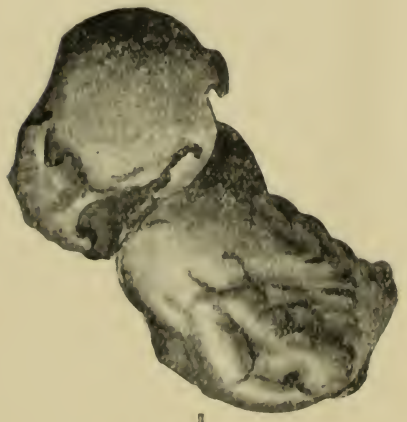

Fig. 2.

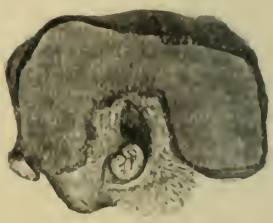

Fig. 3.

Fig. 4.

Fig. 1.—Ovary with ovum and clot, as discovered at time of operation.

Fig. 2.—Clot containing ovum, removed from the top of the ovary.

Fig. 3.—Fallopian tube with small cysts attached.

Fig. 4.—Ovary with cavity that lodged the ovum.

was taken out at the end of thirty-six hours and the stitches were removed on the eighth day, the wound having healed by first intention. At the end of three

weeks she was sent to the Ida Convalescent Hospital. The parts removed at the time of operation were examined under water. The tube was not dilated. Two translucent cysts were attached at the fimbriated end. The fimbriæ could be distinctly seen. The ovary was seen to have a rupture into what appeared to be a small sac. The small ovum was found in the mass of clot taken from the top of the ovary. On immersing it in water the chorionic villi were distinctly seen.

For the following description of the specimen, which is in the Royal College of Surgeons' Museum, I have to thank Mr. S. G. Shattock :—"The parts removed are an ovarian pregnancy. They comprise the fimbriated end of the right Fallopian tube, the ovary, and the ovum partly surrounded by and embedded in recent blood-clot. Connected with the fimbriated extremity of the tube are two small pedunculated cysts, the larger about half an inch in diameter. The ostium is crossed by a thin membranous band of adhesion, beneath which a black bristle has been passed. The tube was firmly adherent to the bottom of Douglas's pouch and quite free of the ovary, the highest part of which projected above its level. At the inner pole of the ovary is a partly collapsed cavity about three quarters of an inch in diameter. This cavity is widely open through a sharply defined semicircular rent of recent origin; in the thin summit of the lid-like portion there is a second narrow, less regular slit, half an inch in length."

Over the cavity in the ovary lay the lens-like recent clot, which is mounted separately in the preparation. The clot is about an inch and a quarter in diameter, and of concavo-convex form; in its concavity, partly embedded in it and partly free, there lies a villous chorional sac. The sac has been opened in the right half of the clot, and the membranes everted; connected with the everted membranes there is displayed a minute embryo about four millimetres in length. From the position of the right tube, the fimbriated extremity of which was firmly

fixed to the bottom of the pouch of Douglas, leaving the ovary free above it, I suspect that the spermatozoa must have reached the right ovary through the healthy left tube.

It is worthy of note that in two of the Leeds cases intra-peritoneal hæmorrhage had been excessive. In my own case the abdomen was so filled with blood that very little was apparently left in the vessels. Intra-venous saline injections became necessary while the operation was being carried out on the abdomen.

The absolute proof of primary ovarian pregnancy by this and the other three cases referred to raises the suspicion that some of the blood-cysts or hæmatomas not infrequently found in ovaries may be due to the impregnation of an ovum within the ovary. In order to settle the question it is important that all such cases, when discovered, should be carefully examined microscopically without delay in order to gain evidence of impregnation, although in some of the cases, owing to the early death of the embryo, the subsequent changes will make identification difficult and perhaps impossible.

Note.—The day after operation a blood-count showed only half the normal number of red corpuscles and five times the normal number of leucocytes. This is interesting as showing the great loss of blood before operation.

Mr. Alban Doran believed that Mr. Mayo Robson, Dr. van Tussenbroek, and the other recent observers had established the fact that a primary ovarian pregnancy was possible. The necessary circumstances to be considered in the study of a report of a new case were the competence of the observer and the condition of the structures concerned. There was no doubt of the competence of the observer in these recent cases. As for the condition of the parts, it was probable that some cases had been overlooked, for the tube and ovary were often much torn in the operation, and when in doubt the operator reported the case as a tubal gestation. When the pregnancy was advanced the most competent observer might be mistaken. Mr. Doran had pointed out fallacies about reports of "primary" ovarian gestation in his notes on Dr. Arthur Beale's case of a minute fœtus found in the peritoneal cavity ('Trans. Obst. Soc.,' vol. xxv, 1893, p. 222). When the corresponding Fallopian tube was

normal the pregnancy might still have originated in it, for it soon recovers after shedding an early ovum out of its ostium. Second-hand quotations from brief reports were dangerous. Thus there was a note in the May number of the 'Monatsschrift für Geburtshülfe und Gynäkologie,' p. 842, headed "Ovarian Pregnancy;" Dr. Füth, of Leipzig, removed the gravid ovary. The right ovary, it was said, was continuous with the sac; the fœtus, a lithopædion, and of about the fifth month of development, was tightly wrapped up in omentum. The patient had been delivered normally six months before the sac was removed; the abnormal pregnancy had occurred about three years previously. Nothing is said about the relation of the tube to the sac, nor is the ovarian pregnancy defined as primary or secondary. Hence such a case should never be quoted unless a more complete report be published by Dr. Füth.

SPECIMENS OF CANCER OF THE CERVIX FROM EIGHT CASES TREATED BY THE SUPRA-VAGINAL AMPUTATION, IN WHICH FROM FOUR TO FIFTEEN YEARS HAD ELAPSED WITHOUT RECURRENCE.

Shown by A. H. N. Lewers, M.D.

Dr. Lewers showed sections under the microscope from eight cases of cancer of cervix treated by the supra-vaginal amputation, in which from four to fifteen years had elapsed without recurrence.

He said that in recording cases of cancer in which it was claimed that the disease had not recurred, two things were especially necessary. In the first place, the sections of the growth in each case should be submitted to independent examination; and in the second place, the nature of the evidence from which it was concluded that the disease had not recurred should be given with the utmost precision.

As regards the first condition, he had obtained an independent report from Mr. Targett—acting for the Clinical Research Association—on each of the eight speci-

Table of 8 *Cases* (*out of* 33) *of Supra-vaginal Amputation of the* *without recurrence from* 4 *to* 15 *years after the operation.* *Supra-vaginal Amputations*

No. in the series of 33 cases of Supra-vaginal Amputations.	Disease.	Date of operation.	Place of operation.
6. Mrs. P.	Cancer of cervix	March 19th, 1887	London Hospital
12. Mrs. C.	,,	May 31st, 1888	,,
16. Mrs. A.	,,	August 26th, 1889	,,
17. Mrs. B.	,,	February 18th, 1890	Private, with Dr. Godson
20. Mrs. K.	,,	January 29th, 1893	Private, with Dr. Godson and Dr. Garry Simpson, of Acton
29. Mrs. H.	,,	October 11th, 1896	Private, at Fitzroy House
31. Mrs. C.	,,	July 16th, 1897	London Hospital
33. Mrs. D.	,,	March 26th, 1898	Private, Fitzroy House

rvix for Cancer, in which the patients are known to have been B.—The numbers refer to the consecutive series of 33 *the Cervix for Cancer.*

Interval since operation without recurrence.	Microscopic characters of growth.
5 years to April 2nd, 1902, the date on which I last heard from her by letter. Last examined Sept. 6th, 1900, at the London Hospital. The patient was sent to me by Dr. Grant	Extract from the Clinical Research Association's Report (Mr. Targett): "The growth is a squamous-celled epithelioma of the cervix uteri."
Nearly 12 years to April 2nd, 1900, the date on which I last examined her at my house. She was sent to me by Dr. Cursham Corner, of Mile End	Extract from the Clinical Research Association's Report (Mr. Targett): "This section shows an early squamous-celled epithelioma of the portio vaginalis of the cervix uteri. An exceptional amount of inflammatory infiltration of the substance of the cervix far away from the growth."
7 years to Nov. 5th, 1896, the date on which I last examined her at the London Hospital	Extract from the Clinical Research Association's Report (Mr. Targett): "A squamous-celled epithelioma which has penetrated deeply into the substance of the cervix uteri. There are very few cell-nests."
12 years to April 28th, 1902, the date on which I last heard from her	Extract from the Clinical Research Association's Report (Mr. Targett): "The growth is a columnar-celled carcinoma of the type known as 'malignant adenoma.'"
9 years to February, 1902, when I last heard from her by letter	"A squamous-celled epithelioma of the cervix uteri."—Extract from the Clinical Research Association's Report (Mr. Targett).
5½ years. Saw and examined her at my house, May 5th, 1902	Extract from the Clinical Research Association's Report (Mr. Targett): "This growth in the cervix is a squamous-celled epithelioma, with thick down-growths of epithelium into the subjacent tissues."
4 years to June 6th, 1901	Extract from the Clinical Research Association's Report (Mr. Targett): "This portion of cervix uteri is deeply invaded by a squamous-celled epithelioma. The epithelial processes are large and branching, and a few cell-nests may be seen in different parts of the section."
4 years to April 11th, 1902, the date on which I last examined her at my house	Extract from the Clinical Research Association's Report (Mr. Targett): "These sections of the cervix uteri exhibit a squamous-celled epithelioma in an early stage of development."

mens in question. He also had brought the sections before the Society on the present occasion.

As regards the second condition, in the table of cases he held in his hand full information was given, namely, the exact date when he had last examined the patient, or the exact date when he had heard from her by letter.

Up to April, 1899, he had performed the supra-vaginal amputation for cancer in thirty-three cases, and in eight of these cases (*i. e.* 24 per cent.) (6, 12, 16, 17, 20, 29, 31, 33) from four to fifteen years had elapsed without recurrence. Such long intervals without recurrence might, he thought, be fairly considered as equivalent to a cure of the disease.

In spite of the satisfactory results he had had from the supra-vaginal amputation for cancer, he had practically at the present time given up performing this operation, and now treated all cases of cancer of cervix in which a radical operation was indicated by vaginal hysterectomy. He had done so chiefly because the supra-vaginal amputation was not rarely followed by troublesome sequelæ, especially moderate or even severe dysmenorrhœa, and in one instance he had met with, complete occlusion of the opening into the uterus with hæmatometra and hæmatosalpinx occurred. He also considered that to perform the operation of supra-vaginal amputation in such a manner as to give the patient the utmost chance of non-recurrence was a more difficult thing, as a rule, than to perform vaginal hysterectomy.

The particulars of the eight cases are given in the accompanying table.

Dr. R. Boxall thought it remarkable that in seven out of eight cases under notice cancer was of the squamous-celled variety, and he asked whether Dr. Lewers could state the proportion of squamous to columnar-celled epitheliomata met with in the whole series of cases on which he had operated. The form of cell growth as disclosed by the microscope seemed to him to have an important bearing on the question of the liability to recurrence.

ADENO-CARCINOMA OF BOTH OVARIES.

By Arnold W. W. Lea, M.D.

Dr. Arnold W. W. Lea showed a specimen of adeno-carcinoma of both ovaries, with microscopic sections and photographs. The specimen was referred to the Pathological Sub-committee for a full report to be published later.

UNUSUAL CASE OF ECTOPIC GESTATION.

By Herbert Williamson, M.A., M.B.

Dr. Williamson stated that he was indebted to Dr. Rudolph Smith, of Stockton-on-Tees, for the clinical history of the patient from whom this specimen was removed by operation.

R. C—, aged 27, has had two previous pregnancies, both of which have been perfectly normal, and labour has occurred in each instance, quite naturally, at full term.

In March, 1901, twelve months after the birth of her last child, she missed a period and believed herself to be pregnant. She suffered from slight vomiting; the breasts became larger and somewhat tender, and gradual enlargement of the abdomen occurred.

During the whole of this pregnancy she noticed no abnormal symptoms whatever; there was never bleeding of any kind nor discharge of membrane, and up to full term she had no reason whatever for thinking that there was anything unusual in her condition.

Dr. Smith writes: "At the end of the nine months, *i.e.* January, 1902, she sent for me, thinking that she was

in labour, but the pains were feeble and nothing happened, and after two days passed off; at this time there was a free discharge of what appeared to be amniotic fluid, but no membrane was passed.

"After this spurious labour there was an escape of milk from the breasts, and the abdominal swelling rapidly diminished in size.

"From the absence of any history of rupture, and from the general feel of the tumour, I diagnosed bicornuate uterus.

"On May 2nd I operated. When the abdomen was opened I found the uterus of natural size, and a gestation sac lying between the layers of the left broad ligament. The right ovary and tube were quite normal. The tumour appeared to be quite unconnected with the uterus, except by the Fallopian tube. The pedicle, consisting of the two layers of the broad ligament, was ligatured and the tumour removed. Except for a slight temperature for two or three days the woman made an uneventful recovery."

From the condition found at operation Dr. Smith came to the conclusion that the case was one of tubal gestation.

Turning now to the specimen itself, the tumour, which is almost spherical in shape, measures twenty-one and a half inches in circumference. The wall is smooth and covered by peritoneum, except over a small triangular area measuring four inches in length and two inches in breadth at its widest part, situated over the lower portion of the tumour on its right side. This area evidently corresponds to the lines of reflection of the two layers of the broad ligament. At the apex of this portion is a rounded cord-like structure, probably the proximal attachment of either the undeveloped horn of a bicornuate uterus or of the Fallopian tube. The lumen is closed; a probe cannot be passed into it. From the opposite pole of the tumour the Fallopian tube is seen to issue. It runs a wavy course for four inches, and terminates at its fimbriated extremity.

The abdominal ostium is not closed; a probe passed into it can easily be made to traverse the tube. Attached to this extremity is a rounded fluid swelling three quarters of an inch in diameter, probably a cystic hydatid of Morgagni. Two inches in front of the point of exit of the Fallopian tube, and at one of the angles of the triangular bare area already described, is seen (cut off very close to the wall of the tumour) a rounded fibrous structure measuring nearly half an inch in its largest diameter, probably the attachment of the round ligament. On the posterior aspect of the mesometrium is the ovary. The ovarian ligament is seen to be inserted directly into the wall of the tumour. Beneath the peritoneum large veins ramify in all directions. At one part an incision seven inches in length has been made. The wall is found to measure one third of an inch in thickness, and to resemble very closely in appearance the wall of a pregnant uterus. Sections stained by van Giessen's method show that it consists chiefly of fibrous tissue containing only very little muscle. It is lined by what appears at first sight to be a decidua of one quarter of an inch in thickness—sections which I have prepared of this structure, however, show it to be the placenta—which has undergone very considerable degenerative changes. It is easily separated from the tumour wall. Inside this are seen the fœtal membranes. The cavity is occupied by the body of a child apparently well developed. Both legs and one arm present at the aperture, and lying over the arm is a somewhat shrivelled umbilical cord; by raising up the band the scalp is brought into view.

Careful consideration of this specimen leads to the conclusion that it is a case of pregnancy in an undeveloped horn of a bicornuate uterus. The ovarian ligament and the round ligament are normally attached to the body of the uterus, and not to the Fallopian tube; both these structures are seen to be attached to the tumour wall. The very considerable thickness of the muscular and fibrous wall of the sac, and the patency of the abdominal

ostium of the tube, also seem to point to a uterine origin. The placenta has undergone such advanced degeneration as to give little help in diagnosis.

Dr. Williamson's Specimen of Pregnancy in Rudimentary Horn of a Uterus Bicornis.

We have examined this specimen, and find that it is a dilated rudimentary left uterine cornu bearing a fœtus.

The relations, left appendages, and left round ligament are well preserved.

J. S. Fairbairn.
Corrie Keep.
C. Hubert Roberts.
G. Bellingham Smith.
J. H. Targett.
H. Williamson.
Alban Doran, *Chairman.*

June 17th, 1902.

CASE OF EXTRA-UTERINE FŒTATION.

By Peter Horrocks, M.D.

The President showed a fresh specimen from a Welsh woman operated on the day before. She had been sent up by Dr. John Morgan, who diagnosed pregnancy and a tumour. The latter could be felt filling up the pelvis, and was so like bone that it was thought likely to be a dermoid cyst. The uterus was pushed upwards and to the right, so that the os uteri was on a level with the top of the symphysis pubis. The sound passed easily for seven inches, and this led to the diagnosis of pregnancy *plus* a tumour, probably ovarian dermoid cyst. It proved, however, to be an extra-uterine fœtation, the fœtus being

quite five months in size. Although greatly deformed it was alive. The placenta was above the fœtus and to the right, and seemed to blend with the right Fallopian tube. The fœtus was apparently adherent in places to the sac. The uterus was large and globular, and though not so large as an intra-uterine five months' gestation, yet it was much bigger than the uterus in a mere extra-uterine gestation of five months. It was thought, therefore, that in all probability it contained a fœtus. This, however, had not yet come away, although she was having pains like labour pains.

The specimen was referred to the Pathological Committee.

Dr. Horrocks's Specimen of Ectopic Gestation.

We have examined this specimen, and find that the placenta lies in the inner half of the distended Fallopian tube. The outer sac which contained the fœtus shows a few rugæ continuous with the plicæ in the canal of the tube, so that this sac is in part formed of Fallopian tube, but appears to be in part adventitious. We regard this specimen, therefore, as a case of tubal gestation. The sac occupied by the fœtus represents either the dilated outer end of the tube or an adventitious sac formed round the fœtus, which has escaped in its unruptured amnion.

J. S. Fairbairn.
Corrie Keep.
C. Hubert Roberts.
G. Bellingham Smith.
J. H. Targett.
W. Williamson.
Alban Doran, *Chairman.*

June 17th, 1902.

Dr. Galabin said that he thought it would be of interest to know whether the intra-uterine fœtus proved to be of the same age as the extra-uterine, since twin pregnancy had been alleged to be one of the causes of extra-uterine fœtation, through one ovum impeding the other on its way to the uterus. The

evidence relied upon was that twin pregnancy was said to be much commoner in proportion (four times) with one fœtus extra-uterine, than in uterine pregnancy; and that in these cases there was generally no previous sterility. He had met many years ago with a case of combined extra- and intra-uterine pregnancy, in which the fœtuses were of equal development, between four and five months. The extra-uterine sac ruptured and an operation was performed. The placenta had to be left, as its attachment extended to the back of the pregnant uterus. At the time he regarded it as a case of abdominal pregnancy; but he thought that now he should probably interpret it as one of intra-ligamentous pregnancy, which had stripped the peritoneum off the back of the uterus. In the sequel this attachment of the placenta proved very unfortunate. The patient, who lived eighty miles from London, aborted about three days after the operation. The retraction of the uterus separated the extra-uterine placenta, and she quickly died from hæmorrhage.

PREGNANCY AFTER REMOVAL OF BOTH OVARIES FOR CYSTIC TUMOUR.

By Alban Doran, F.R.C.S.,
SURGEON TO THE SAMARITAN FREE HOSPITAL.

(Received April 3rd, 1902.)

(*Abstract.*)

A woman aged 25, after bearing one child, underwent ovariotomy for a multilocular adenomatous cystic tumour of the left ovary. She then bore four more children, and afterwards, when thirty-nine years of age, came under the author's care, and he removed a similar tumour of the right ovary. The base required enucleation, part of the capsule was ligatured like a pedicle with silk, and the greater portion cut away, but in that part no trace of the Fallopian tube could be detected. A small tubercle on the left of the uterus was the sole remnant of the left appendages. After convalescence the period recurred, and continued till the patient became pregnant and bore a child at term two years after the operation. The period then returned, and ceased abruptly when the patient was forty-five. The consequent menopause symptoms were distinct though mild.

The author briefly reviews a few cases already reported where pregnancy ensued after the removal of both ovaries for tumour or chronic inflammatory disease.

(1) Schatz. Both ovaries removed for cystic tumour; one tube and a piece of ovarian tissue were purposely left behind. Five years later the patient gave birth to a child at term.

(2) Stansbury Sutton (Pittsburgh, U.S.). Both ovaries removed for cystic disease; right pedicle severed by cautery, left by scissors. Patient twice pregnant afterwards.

(3) Gordon (Portland, Maine, U.S.). Removed both tubes and ovaries for inflammatory disease; patient delivered of a child two years later. Other reported cases are doubtful.

The presence of ovarian tissue is essential in these cases. In the author's case it was probably a detached area lying in the right ovarian ligament; the cyst itself was certainly enucleated entire. The author suspects that the Fallopian tube escaped ligature and removal altogether, the base of the tumour being enucleated from the posterior layer of the broad ligament. The condition after operation would then be as in Schatz's case, the tube remaining entire. It was not absolutely certain, however, that the tube was not included in the ligature and in part removed. This occurred in Stansbury Sutton's and Gordon's cases, and reference is made to a case where pregnancy occurred after Cæsarean section and ligature of both tubes with silkworm gut for "sterilisation" (Galabin-Horrocks). The ligature may either loosen or perhaps ulcerate through the tube, which manages to heal behind it without stricture of its canal. The tube may then resume its functions, even if reduced to a stump.

In the summer of 1894 I performed ovariotomy upon two patients who had already undergone that operation. In both cases the disease was cystic tumour. I reported them in the 'Lancet' for December 15th, 1894,* mainly on account of the case with which we have not to do at present. In 1889 I removed from a woman aged fifty a multilocular papilloma of the right ovary, and noted "the left was elongated and atrophied." The patient had reached her menopause. The disease appeared again, and in July, 1894, I operated, removing a multilocular papilloma of the left ovary. At the present time, eight years later, she was free from any sign of recurrence.

The entire aim of the article which I wrote on these two cases was to turn attention to Pfannenstiel's opinion that "in all cases of tumours which have a notorious tendency to become bilateral, namely, carcinoma, sarcoma,

* "Two Cases of Ovariotomy performed Twice on the same Patient," 'Lancet,' vol. ii, 1894, p. 621.

endothelioma, *as well as papillary tumours, be they adenomata or carcinomata,* the opposite ovary should be removed *even when it appears healthy,* whatever may be the patient's age." I conclude that the above case rather strengthened this opinion of Pfannenstiel's, "nevertheless the removal of a healthy ovary is not to be lightly undertaken."

I made much less of the case now to be considered. I simply removed a cystic tumour of the right ovary fourteen years after a similar growth on the left side had been taken away by a distinguished authority. That authority spared the ovary which I had afterwards to remove, as when he operated it showed no sign of disease. I, too, in my first operation on the case of papilloma did not feel justified in amputating the opposite ovary, which in that instance seemed atrophied. In the case to be considered there was a cystic ovarian tumour which I had to remove. I noted that there was no recurrence in the pedicle of the other ovary, and no further details were necessary on an article devoted to the question of recurrence.

It happens, however, that the patient not only menstruated regularly after the second ovariotomy, but also bore a child to term two years after the operation. I will, therefore, quote in full the notes which I took directly after the ovariotomy. They have proved of great value as throwing light on the question now to the point—pregnancy after double ovariotomy.

The patient in the summer of 1894 was thirty-nine years old. She had been married for eighteen years, and after bearing a child underwent ovariotomy, Dr. Robert Barnes removing a multilocular cyst of the left ovary. This happened fourteen years before she came under my care. She bore four children after the first operation, the youngest being three years old in 1894, and she had never aborted. In the summer of 1893 the patient's abdomen began to swell. Sir Spencer Wells saw her, and diagnosed an ovarian cyst and sent her on to me.

There could be no difficulty in diagnosis. On June 14th, 1894, I operated. I will quote my notes entire.*

"Parietes very thin, no adhesions. A multilocular cyst came in sight; the omentum ran on to it, firmly adherent to its capsule. I tapped two loculi; about a pint of chocolate-coloured ovarian fluid escaped. Then I detached omentum and a coil of small intestine closely adherent to the cyst wall, somewhat to the left, and at the fundus of the cyst, at the level of the umbilicus. The mesentery formed a kind of capsule to the back and to the right side of the cyst. I separated the intestinal adhesion partly with my index nail, partly by cutting with scissors. A sponge was applied to the separated intestine; the adhesion oozed considerably; then the coil was kept out of the upper angle of the wound, and covered with a warm damp towel.

"The mesentery and broad ligament were detached from the cyst, the base of which was drawn up and then seen to lie close against the uterus on the left and the vermiform appendix on the right. The base of the capsule was tied with a Bantock knot (this term signifies that, after transfixion, one end of the silk was drawn through the loop and tied to the other end, according to Dr. Bantock's practice).† An artery had been divided on the *upper* aspect of the base of the capsule (probably the ovarian artery, course diverted by the burrowing of the cyst); ‡ it was secured by a forceps and drawn into the ligature. Two ragged pieces of adherent omentum and one tag, running into Douglas's pouch, were tied with No. 1 silk. There was no blood in Douglas's pouch, and the separated adhesion on the small intestine (which after the dividing of the ligatured base of [the] capsule had been returned into the abdomen covered by a sponge) had ceased to bleed. No drainage. Iodoform freely applied to wound" (an ancient custom).

* I headed the case "Ovariotomy (second, first fourteen years ago); Enucleation," in my note-book.

† I used, as I still use, silk No. 3, China twist.

‡ This parenthetic sentence is part of the original text.

"*Description of tumour.*—A multilocular cyst, five and a half ounces, three main loculi exogenous; a fourth, nearest uterus, contained glandular material.* Fluid two pints *plus* some lost." Here comes a line which I thought trivial at the time, but which has proved to be of great importance: "(no trace of Fallopian tube in capsule, see p. 6)." On turning to page 6 of the note-book I see that I entered under *Generative system*, "Period regular, three-weekly, very free show (not a trace of ovarian tissue found in tumour; I must have left the tube in the capsule: note effects), see p. 22." On turning to page 22 I find note under *Subsequent history*, "November 1st, 1894, visited me. In no pain, *but period has been seen regularly since operation;* last period during last week in October."

The note on "Description of tumour" ends—"The uterus was pushed to left, and on its left side the broad ligament was much shortened; the stump of ovary removed fourteen years was a small tubercle." I have been careful not to corrupt the text of this ancient document. Hence I have retained the expression "capsule" twice used in a manner tending to mislead, as will be explained. I remember that it was the base alone of the tumour that burrowed into the broad ligament. The patient made a good recovery, as noted above. I saw her five months after the operation, and was surprised to learn that she had menstruated.

Until this year I never heard directly from the patient after November, 1894, though a friend of hers occasionally informed me that she was in good health. In March, 1902, she consulted me, fearing a recurrence of the tumour, as there was pain and swelling. The distension was purely flatulent. The pain was caused by a mass of scybala, which I felt in the left fornix and succeeded in getting away; they were as hard as pebbles, and had caused diarrhœa. The uterus was quite mobile, and both

* Had this glandular cyst in the base of the tumour not been enucleated recurrence would have been almost certain.

fornices were free from any deposit, etc., after the scybala had been cleared away. The patient then said she was troubled with flushings occasionally. I asked her about the period, expecting that it would have ceased within a year or two after the operation. Then she told me that it was last seen as late as December, 1900, when she had a severe shock owing to a sudden death in her family, and the period never returned; she was therefore just over forty-five at the menopause. I was interested with this after history, but my surprise was great when she volunteered the statement that she had borne a child since I removed her second ovary. I asked her for further information, and then she explained that she had given birth to a child in the summer of 1896, just two years after the operation.

I at once wrote to Dr. Stacey Burn, of Richmond, who attended the patient on that occasion, and he replied, "I remember Mrs. —— very well. I find she was confined on July 23rd, 1896, of a girl. I had to use forceps, though there was apparently no obstacle to the descent of the head, but I believe she has always had to have forceps used. I quite well remember her telling me about her two operations, and that you had told her that she would not have any more children. I have no notes of the case, but there was nothing abnormal about it beyond what I have said."*

From the above records of this case it is clear—

(1) That a cystic tumour of the left ovary was removed by Dr. Barnes when the patient was twenty-five.

(2) That after the operation she bore four children, and then a cystic tumour of the right ovary developed, which I removed when the patient was thirty-nine, finding the stump of the pedicle on the left side reduced to a mere tubercle.

(3) That not only did the period recur soon after the second operation, the menopause not being established till

* The patient was unable to suckle this or any other of her children; the mammæ were very ill-developed.

the patient was forty-five, but she also became pregnant and bore a child at term two years after the operation.

Again, it seems equally clear—

(4) That the tumour removed by Dr. Barnes was an ovarian or oöphoritic cyst, not a paroöphoritic cyst; whilst whatever the tumour might have been, the tube and ovary were practically extirpated.

(5) That the tumour which I removed was certainly a true ovarian (oöphoritic) cyst, multilocular, with adenomatous tissue (never seen in a paroöphoritic cyst) in some of its loculi, and with characteristic brown fluid.

(6) That the base but not the rest of the cyst burrowed considerably into the right broad ligament, whence it was enucleated. The strong adhesions have nothing to do with the question under discussion, and when I noted that the omentum was adherent to the "capsule"* I simply meant the "surface" of the upper part of the cyst. I found the base of the cyst "close against the uterus," and enucleated it.

(7) That I trimmed away the greater part of the capsule after the enucleation, and made two notes, which have proved to be more important than I expected: "No trace of Fallopian tube in capsule;" and "not a trace of ovarian tissue found in tumour; I must have left the tube in the capsule." I meant by this that the tube remained in the part of the capsule left behind.

(8) That the base of the capsule was transfixed and tied like a normal pedicle, whilst the tube, probably entire, was not included in the ligature. I will discuss presently the possibility that the tube was included in

* I reported, "The mesentery formed a kind of capsule to the back and to the right side of the cyst." The term "capsule" so used is a little confusing; but I added, "the mesentery and broad ligament were detached from the cyst, the base of which was drawn up," etc. What I signified was that the mesentery was freed from its adhesion to the back of the cyst, and the broad ligament peeled off the base of the cyst, which was then drawn up, and the base of the capsule ligatured as a pedicle.

the ligature, and that I did not recognise the portion that must, in that case, have been cut away.

(9) That some ovarian tissue must have been left behind, free from any trace of cystic adenoma, which is almost certain to recur if not thoroughly extirpated.

I will now consider, firstly, some reported cases of pregnancy after the removal of both ovaries; and secondly, the possibility of the restoration of the function of a ligatured tube.

Under the first heading come cases reported by Schatz, Stansbury Sutton, and Gordon.

Schatz, of Rostock,* performed ovariotomy on a single woman aged twenty on February 20th, 1880. He removed a cystic tumour of the left ovary, and with it the outer third of the corresponding tube. The right ovary was of the size of a walnut, and showed evidence of cystic degeneration. He removed it, but purposely left some ovarian tissue in the stump, and spared the Fallopian tube altogether. Menstruation returned on May 9th, 1880, after attacks of hypogastric pain in March and April. The patient was married on April 23rd, 1884. The period ceased after August, and on May 12th, 1885, she was delivered at term of a girl. The forceps was used as the labour was lingering.

Stansbury Sutton's (Pittsburgh, U.S.A.) patient † was thirty-two years old, and had a child six years of age when he operated on March 20th, 1892, removing a multilocular cyst of the left ovary and a colloid cyst of the right ovary. The right pedicle was severed by the cautery, the left with scissors. The uterus being retroverted, it was fixed to the lower angle of the wound. On June 10th, 1894, she gave birth to a male child weighing ten and a half pounds. In 1896 she was safely delivered of another child. Stansbury Sutton believed

* "Schwangerschaft nach doppelseitiger Ovariotomie," 'Centralbl. f. Gynak.,' 1885, p. 353.

† "Double Ovariotomy followed by Pregnancy and Delivery at Term," 'Amer. Journ. Obstet.,' vol. xxxiv, 1896, p. 92.

that there must have been a detached piece of ovarian tissue in the left stump to which the cautery was not applied. He thought that if the ligature were tied sufficiently close up to the uterine cornu so as to cut the sympathetic nerve there would be no more menstruation. He added another case in his own experience where he removed both ovaries with the tubes for chronic inflammatory disease or some similar affection. Nine months later, less forty days, she was delivered of a child.

In the discussion which followed the reading of Stansbury Sutton's case before the American Gynecological Society, Lapthorn Smith stated that he had removed the tubes and ovaries from a woman aged twenty-eight subject to dysmenorrhœa. She bore a child about nine months later, but it was probable that a fecundated ovum had entered the uterus very shortly before the operation. Engelmann, Palmer Dudley, and Arthur Johnstone spoke on the merits of the practice of leaving pieces of ovarian tissue when the ovaries were removed for inflammatory disease; some left a tube. Ovarian tissue had been noted as left behind in the proximal side of the pedicle in some of these cases. Here I must note that I should be very averse to leaving ovarian tissue behind when there was a true tumour to be removed.

S. C. Gordon,* of Portland, Maine, records one not very perfect case where a woman aged thirty-six became pregnant in June, 1894, and was delivered in February, 1895. In May, 1891, she had undergone an operation, her husband understanding at that time that both ovaries were removed; but the operator, J. R. Chadwick, had mislaid his notes, so that there was some uncertainty about how much of the appendages were taken away. Presumably the operation was performed for chronic inflammatory changes. Gordon himself removed both ovaries and tubes in March, 1894, from a woman over

* "Two Pregnancies after Removal of both Ovaries and Tubes," 'Amer. Gyn. and Obstet. Journ.,' vol. ix, 1896, pp. 28, 79.

thirty subject to chronic pelvic inflammation. So far as he knew there were no fragments of ovarian tissue left. In June, 1895, the patient became pregnant. She was delivered of a healthy child in March, 1896. In the first case, where Chadwick had operated, menstruation had been irregular between the operation and the pregnancy. After the latter it became regular. In the second case menstruation began within three months of Gordon's operation, and continued regular till the pregnancy. Gordon's cases were read with Stansbury Sutton's at the same meeting of the American Gynecological Society, May, 1896. Both are to be found reported, with the discussion, in two American journals, but a different order is followed in the two reports.

Both in the case where Gordon alone operated and in that which he records on imperfect evidence, the ovaries were removed for inflammatory disease. Under such circumstances it is not easy to get away all ovarian tissue, as the ovaries are small and the ovarian ligaments short. When the pedicle is short the operator rightly dreads slipping of the ligature, and so is apt to make it too long, and leaves a piece of ovary behind. This often happened when oöphorectomy for relief of uterine fibroid disease was popular. In operating for a cyst those ligaments are elongated, so that complete removal is easier unless, as in my own case, the tumour be sessile.

In all the cases, except that recorded by Schatz, the tube was included in the ligature and divided, and its stump must have recovered its functions afterwards.

Schatz deliberately left the tube and a piece of ovarian tissue on one side. In my case, I without doubt enucleated the cyst entire, but there must have been some detached tissue containing follicles in the ovarian ligament, a condition which I have observed.* As for the tube, I

* "There is no authentic instance on record of a third ovary" (Bland-Sutton, 'Surgical Diseases of Ovaries,' etc., 2nd edit., p. 416). Schultzenstein's case is doubtful (see 'Trans. Obstet. Soc.,' vol. xli, p. 198, foot-note to my paper "Fibroid of the Broad Ligament weighing 44½ lbs.").

enucleated the base of the tumour from the posterior layer of the mesosalpinx and apparently missed the tube altogether, hence the notes which I quote above. I tied the ovarian artery, and then must have transfixed the posterior layer of the mesosalpinx alone; thus the tube was not included in the ligature.

Had I transfixed the entire broad ligament, that is to say, the two layers of the mesosalpinx, the tube must necessarily have been included. It would also have been divided, and I would have found it in the part of the capsule removed with the tumour. I did not find it, hence my notes copied above.

On the other hand, supposing that the tube had been ligatured and divided, it might yet have resumed its functions. Such must have occurred in Stansbury Sutton's and in Gordon's cases. This possibility must be considered, since I cannot feel sure that I might not, after all, have included the tube in the ligature, divided it with the rest of the capsule, and failed to recognise its distal end afterwards. When a capsule has to be torn freely the outer part of the tube is not always easy to distinguish; it may be torn or cut off separately and taken for a fibrous band, etc. The separation of numerous adhesions which extended posteriorly to the base of the cyst, as stated in the above account of the operation, confused the relations of the cyst, so the tube might easily have been torn away and its end included, as a mere shred, in the ligature. Altogether I suspect that I did not include the tube in the ligature and did not tear any part of it away. Still I might have done so, and in the other cases the tube was certainly ligatured.

The ligature of the Fallopian tubes was, till recently, considered sufficient to ensure sterility. Mr. Bland-Sutton, when performing a Cæsarean section in March, 1892, "took the opportunity of sterilising the patient by tying each Fallopian tube near the uterus by a single piece of silk. Tying in two places and dividing between

the ligatures is unnecessary, as one ligature will obliterate the lumen of this soft duct." *

Further experience has proved that one ligature will not permanently obliterate the lumen of the Fallopian tube. Dr. Horrocks † recently "mentioned a case in which the patient had been sterilised after Cæsarean section by ligaturing the Fallopian tubes. In spite of this she became pregnant again, and the uterus ruptured along the line of the incision when near full term, and the child and a portion of the placenta escaped into the abdomen. Dr. Galabin removed the uterus, and the specimen is now in the Guy's Museum. The patient recovered. The ligature on one side had cut through the tube, and the severed end lay about half an inch apart. On the other side the tube and ligature looked as if the tying had only just been done, and on experimenting it was impossible to force a coloured liquid through the tube. Still it was thought that in all probability the ovum which had become impregnated had got past the constriction produced by the ligature and so entered the uterus."

Dr. Horrocks informs me that the Cæsarean section was in this case performed by Dr. J. Shaw, and reported in the 'Transactions of the Obstetrical Society,' vol. xxxiv, 1892, p. 98; silkworm gut was used for tying the tubes (ibid., p. 101). In about two years later she was brought into Guy's Hospital in a state of collapse, and hysterectomy was performed as noted above. I understand that in another case, where a single ligature was applied to each tube to sterilise a woman with a narrow pelvis, pregnancy occurred within a few years.

Thus it is easy to understand how the stump of the

* "Discussion on Cæsarean Section," 'Trans. Obstet. Soc.,' vol. xxxiv, 1892, p. 139. For Champneys' method of tying a loop of tube and excising it see ibid., p. 140, third paragraph. See also Kehrer, "De la Stérilité Tubaire," 'L'Obstétrique,' March, 1902, p. 139. I have not been able to obtain the original article by that authority.

† Ibid., vol. xlii, 1900, p. 243.

tube resumed its functions in Stansbury Sutton's and Gordon's cases, and in mine also if I really tied it. Either the ligature loosens, or else it ulcerates through the tube which heals behind it, and without complete stricture of its canal.

In conclusion, pregnancy certainly occurred in my case after the complete extirpation of two cystic adenomatous tumours of the ovary proper. There must have been ovarian tissue remaining in the right ovarian ligament, whilst the tube was either left intact, as explained above, or if divided after inclusion in the ligature, the stump resumed its functions.

Addendum.

Since reading the above communication I find that I have overlooked some published cases. I therefore add a few short notes briefly recording their principal features.

J. Anderson Robertson.—"Renewal of Menstruation and Subsequent Pregnancy after Removal of both Ovaries," 'Brit. Med. Journ.,' vol. ii, 1890, p. 722. Patient aged twenty-three; both ovaries removed on Jan. 26th, 1889, for chronic inflammatory changes; no note about tubes. Patient married in June, ceased menstruation on October 25th, and was delivered with the aid of forceps on August 13th, 1890. Dr. Robertson believed that possibly a small portion of healthy ovarian tissue extended up to or beyond the hilum of the right ovary. Most probably a piece of ovarian tissue was left on the distal end of the ovarian ligament, which is very short when there is no true new growth in the ovary, as I have explained above.

Kossmann.—'Amer. Journ. Obstet.,' vol. xli, p. 839. Another case of oöphorectomy for chronic inflammatory disease of the appendages. *The tubes were not removed.* Patient became pregnant about a year and a half later, and was delivered spontaneously of a living child. Afterwards she again became pregnant.

M. M. Morris, Boston, U.S.A.—"Pregnancy following

Removal of both Ovaries and Tubes," 'Boston Med. and Surg. Journ.,' vol. cxliv, 1901, p. 86. Another oöphorectomy for inflamed ovaries. In July, 1898, "the ovaries and tubes were tied off with silk quite close to the uterus and removed." The right ovary contained a cyst as large as a hen's egg, and the left a hæmatoma nearly as large as the cyst. Menstruation returned; then the patient became pregnant, and was delivered of a live child on September 12th, 1899. The child died within three weeks and menstruation returned.

J. E. Engelmann (M. M. Morris, loc. cit.).—"Pregnancy followed a double ovariotomy in which the right tube was left intact. A microscopic examination made of the specimen later showed that some ovarian tissue had been left." This statement explains the pregnancy. I regret that I have not been able to obtain a copy of the original report in the 'Transactions of the Southern Surgical and Gynecological Association,' September, 1899. It would be interesting to ascertain whether the pedicle on each side was long, consequently bearing an elongated ovarian ligament, or whether the cyst on one side burrowed in the broad ligament and came in close contact with the uterus, as in my case.

M. M. Morris mentions in his paper a case of "Pregnancy after Ovariotomy" reported by C. F. Harding ('Lancet,' vol. i, 1880, p. 193). But on referring to the original report under the "Notes, short comments," etc., in that journal I find that it was a case of the removal of one large tumour by Walter, of Peterborough, followed by pregnancy directly after convalescence, and labour at term. Morris's quotation is therefore somewhat misleading, as it is placed between notes of Robertson's and Palmer Dudley's cases. "C. F. Harding reports a pregnancy after ovariotomy:" nothing more is said, so that the reader might naturally conclude that the ovariotomy was double.

Mr. Bland-Sutton observed that Mr. Doran's interesting communication really raised two important questions for con-

sideration, namely, the occurrence of pregnancy after double ovariotomy, and the effect of a ligature on the continuity of the lumen of a Fallopian tube. Probably no one in England had studied so closely the "fate of the ligature" after successful ovariotomy as Mr. Doran, and he certainly was the first to study the changes which took place in the stump of the pedicle after intra-peritoneal ligature.

Mr. Bland-Sutton's opportunities for dissecting stumps of the Fallopian tubes after successful ovariotomy were seven. In each instance the stump of the Fallopian tube was clean and rounded as the figure. This drawing was made from the parts removed from a woman supposed to have had both ovaries

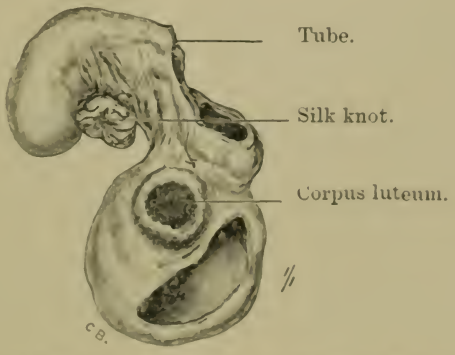

The rounded stump of a Fallopian tube two years after oöphorectomy.

completely removed nearly two years previously. The fragment of ovary contained ripe follicles and a well-formed corpus luteum.

It is now quite certain that when a Fallopian tube is ligatured in continuity, it does not necessarily permanently obliterate the tubal lumen. In his Cæsarean section (the case alluded to by Mr. Doran) for pelvic contraction, Mr. Bland-Sutton (1891) tied the Fallopian tubes with thin silk within an inch of the uterus; this patient has remained sterile. On a subsequent occasion, when it was deemed prudent to induce labour for uncontrollable vomiting and epileptic seizures, an attempt was made to sterilise the patient by drawing out each tube and transfixing the mesosalpinx with a needle armed with thin silk, and then tightly tying the tube near its middle. This failed, for the patient quickly conceived again, and has reconceived many times, though her constitutional condition has never allowed a pregnancy to go to term. Since this experience, Mr. Bland-Sutton had always tied the tubes in two

places, and exsected a piece of the tube when it was desirable to sterilise a patient. The occasions when such a course will be necessary will fortunately in the future be very few, because it is now becoming the recognised practice (save in exceptional cases) to perform hysterectomy in preference to Cæsarean section followed by sterilisation.

The fact that pregnancy supervened after ligature of the tube in continuity led Mr. Bland-Sutton to look into the matter, and in the collected works of John Hunter he had come across an account of some experiments, whereby this distinguished man had proved that simple ligature of the elongated uterine cornua of sows did not produce infertility. In recent years L. Fraenkel had carried out a valuable series of experimental observations on the oviducts and uterine cornua of rabbits ('Archiv für Gynäkologie,' Bd. lviii, S. 374, 1899), and had arrived at the conclusion that simple ligature of the uterine cornua in these animals could not be relied upon to sterilise them; and he expresses the somewhat startling conclusion that to be quite sure of sterilisation in women, it is not only necessary to remove the tubes, but to exsect their uterine terminations and bring the peritoneal surfaces of the uterine gap into apposition with sutures. Doran's suggestion that "the ligature may perhaps ulcerate through the tube, which then heals behind it without stricture of its canal," is probably true, and the following case in a measure supports it. In 1898 Mr. Bland-Sutton removed an ovarian cyst; its very slender pedicle was tied with thin silk. Although recovery was uneventful, the patient complained during many weeks of cramp-like pain on the side from which the cyst had been removed. The pains gradually passed away, and ten months later, during menstruation, the patient accidentally noticed on her napkin a tiny loop of silk, which she saved. This was the loop of silk used to secure the Fallopian tube; it had ulcerated into the tube and had been very slowly conducted into the uterus, and so escaped. A silk ligature applied to the cut end of a ureter in the course of a nephrectomy is sometimes conveyed to the bladder in the same manner. Mr. Bland-Sutton was glad to have the opportunity of stating that the opinion he expressed to the Society in 1892 had not been borne out by subsequent experience; and it is now abundantly clear to all that the mere application of a silk ligature to the Fallopian tubes could not be depended upon to permanently obliterate their lumina, and thus prove an obstacle to pregnancy.

Dr. Galabin said that he had met with two cases in which the attempt to sterilise by tying the Fallopian tubes had failed, and which were those referred to by the author. In that in which Dr. John Shaw had tied the Fallopian tubes with silkworm gut in performing Cæsarean section, it was certain that the ovum had passed by the tube on which the ligature

appeared to remain *in situ;* for on the side on which the ligature had cut through, and the tube was divided, the divided ends were absolutely closed. In the second case he had himself, in performing Cæsarean section, tied the tubes with kangaroo tendon, and the patient became pregnant again within a year or so. Taught by the experience of these cases, he had since then adopted the plan of cutting a piece out of the tubes between two ligatures, then pulling out the stump on each side as far as possible and cutting it off, so that the open lumen was left at the bottom of an inverted cone of cellular tissue. None of the patients so treated had become pregnant again, and he was inclined so far to regard this as a reliable method.

Dr. Herbert Spencer thought that some portion of one of the tumours had probably been left behind in separating the adhesions. He had known an ovarian tumour develop after double ovariotomy from this cause. The case alluded to by Mr. Bland-Sutton had recently been under his care. She had been pregnant seven times since the tubes had been tied by Mr. Sutton. Mr. Alban Doran had not alluded to the remarkable case of pregnancy occurring after double oöphorectomy for fibroids, published by Jacobs.* This operation had been performed in 1890, and was followed by amenorrhœa for three years. Subsequently menstruation recurred, and the patient married in 1900. She became pregnant, and Cæsarean section with hysterectomy was performed in December, 1901. The heading of the case stated that the mother recovered ("guérison de la mère"), but at the end of the notes it was reported that the patient died of embolism before she left the hospital, apparently shortly after the fifteenth day. He hoped statisticians would note this.

Mr. Butler-Smythe asked Dr. Herbert Spencer if he could give any information relative to the pregnancies of Mr. Bland-Sutton's patient. She had attended at the Samaritan Hospital, and stated that subsequent to the operation she had twice miscarried with twins, which rather surprised her, inasmuch as all her previous pregnancies had been single. He also wished to know if the fits had been benefited by the operation.

The President had expected to hear a hot discussion on how pregnancy could have taken place when both ovaries had been removed, but Mr. Doran had frankly admitted that a piece of ovarian tissue had been left behind at the second operation, so that there was nothing strange about the case. He was surprised to hear Mr. Doran advocate the removal of both ovaries

* Jacobs, 'Bulletin de la Société Belge de Gynécologie,' vol. xii, No. 6, p. 134.

entire when it was possible to leave a healthy piece. He thought it better to leave some ovary whenever possible.

Dr. Amand Routh thought that sufficient cases could now be collected to explain the occasional occurrence of menstruation and ovulation after double ovariotomy, and he observed that in most of the reported cases a latent period of a few months or even years elapsed before menstruation again appeared. He thought it likely that a small piece of the hilum of one ovary might be left, containing no Graafian follicles sufficiently developed to immediately come to maturity. He believed that such a piece of ovarian stroma, together with the follicles, became in a few months further developed, and ovulation and menstruation then recurred. He instanced the case of a young woman aged twenty-eight, both of whose ovaries had been removed in Bristol for severe dysmenorrhœa and epilepsy. In this case both Fallopian tubes were removed close to the uterus, yet amenorrhœa lasted only a few months, and since then both the epilepsy and dysmenorrhœa have recurred as severely as before.

Dr. Boxall remarked on the impossibility of making absolutely sure that sterility will necessarily result from ligature of the Fallopian tubes. The importance of the question often arises when operation is undertaken, and the tubes are at the same time ligatured with the object of rendering the woman sterile, but may also arise when, from disease of the appendages, operation is indicated. For instance, he had recently met with a case in which, owing to long-continued and recurrent attacks of inflammation, it became necessary to urge surgical interference with the appendages. To this procedure objection was raised, both by the patient and by her husband, solely on the ground that complete removal of the appendages would entail sterility. In that event, being Jesuits, cohabitation would be forbidden by the Church. Eventually the symptoms became so urgent that operation was rendered imperative. Fortunately it was found possible to retain a healthy part of one ovary, in consequence of which the menses have not been discontinued; and, notwithstanding that the greater part of both tubes as well as one ovary and part of the other were of necessity removed, no occasion arose for the separation which they both so much dreaded; for it was possible to assure them that impregnation was not, by the operation at any rate, put beyond the bounds of possibility.

Mr. Alban Doran was much interested in the discussion on attempts to sterilise a patient by tying or cutting the Fallopian tubes. He believed that in his own case a trace of healthy (not cystic) ovarian tissue was left in the right ovarian ligament. It was easy to extirpate all ovarian tissue when the ovaries were taken away with the uterus, and not difficult when a peduncu-

lated ovarian cyst was removed, as the ovarian ligament was elongated and very prominent. But when the base of the cyst burrowed, and lay close against the uterus, the ovarian ligament could rarely be distinguished. In one case where Mr. Doran was obliged to remove the uterus with the burrowing adherent tumour, he found, on examining the specimen, that it would have been practically impossible to leave the ovarian ligament as part of a pedicle without leaving also ovarian tissue, morbid or healthy. As it was with a burrowing cystic tumour, so it was with inflamed adherent appendages, and so it very often was with an ovary removed to check the growth of a uterine fibroid. In all these cases the operator dared not cut the pedicle sufficiently short to remove all ovarian tissue, for he knew that if he did so the ligature would probably slip. Hence it was not very hard to understand that in some cases menstruation or even pregnancy occurred after removal of both ovaries. In his own case the ovarian ligament with some healthy tissue had probably been flattened against the uterus, and had thus escaped the ligature. After-histories of all abdominal operations were very valuable, especially as to the fate of ligatures, which were shed sometimes eight or ten years after they had been applied.

JULY 2ND, 1902.

PETER HORROCKS, M.D., President, in the Chair.

Present—33 Fellows and 2 visitors.

Books were presented by the College of Physicians of Philadelphia.

The following candidates were proposed for election :—Salvatore Gréch, M.D., Univ. Malta; Edward Lynn, M.R.C.S.

The following candidates were elected Fellows of the Society :—Jessie George, L.R.C.P., L.R.C.S.Ed.; Mary Thorne, M.D., L.S.A.; Clement White, M.B., B.C.Cantab.; W. Burslem Rotheroe, L.R.C.S. & P.Edin.; Richard Henry A. Whitelocke, M.B., C.M.Edin.; William Henry Breffit Brook, M.D., B.S., F.R.C.S.; Edward Marten Payne, M.B., C.M.

Report of the Pathological Committee on Dr. Fothergill's specimen of Decidual Uterine Cast of seven weeks' growth, together with an Ovum of about five days' growth (shown June 5th, 1901).*

WE, the undersigned, have met this day, and after examining the microscopic sections of the specimens

* Vol. xliii, 1901, p. 162.

named above, have drawn up and signed the following report:

The sections of the uterine cast have the structure of a typical decidual membrane, and the sections of the ovum show it to be in a very early stage of development. We therefore agree with the general description of the specimens given by the author.

ARCHIBALD DONALD.
W. E. FOTHERGILL.
J. H. TARGETT.
T. W. EDEN, *Convener.*

May 30th, 1902.

Report of the Pathological Committee on Dr. Tate's specimen of Sarcoma of the Uterus (shown May 7th, 1902).*

WE are of opinion that this specimen is a primary sarcoma of the body of the uterus, and that it is associated with a fibro-myoma. There is no evidence that the sarcoma represents a malignant degeneration of a fibro-myoma. There is a distinct line of demarcation between the two tumours. The microscopical appearances show that the malignant tumour is a mixed round- and spindle-celled sarcoma, whilst the innocent tumour is undoubtedly a fibro-myoma. There is no evidence of invasion of the fibro-myoma by the sarcomatous growth.

WALTER W. H. TATE.
J. S. FAIRBAIRN.
CORRIE KEEP.
C. HUBERT ROBERTS.
G. BELLINGHAM SMITH.
J. H. TARGETT.
W. WILLIAMSON.
ALBAN DORAN, *Chairman.*

* P. 165.

A CASE OF PUERPERAL ECLAMPSIA, WITH AUTOPSY AND REMARKS.

By R. H. Bell, M.A., M.B., B.C.Cantab.

Comparatively few cases of eclampsia, in England at any rate, are followed by autopsy, with microscopical examination of the organs principally affected ; and on this account, as stated by Herman,* our knowledge of the morbid anatomy of the disease is behind that of its clinical phenomena.

In the present instance sections of the liver and kidneys are available for the personal examination and criticism of the Fellows. The macroscopic appearances of the liver can also be studied. It seemed therefore worth while to bring the case, although an isolated one, before the Society. For permission to do so I am indebted to Dr. Tate, under whose care the patient was admitted to St. Thomas's Hospital. The clinical history was as follows :

E. M—, a single woman aged 21, was brought up to the hospital February 26th, 1902, in a state of coma following a fit. The history of her illness was obtained from her mother. The first definite symptoms occurred about Christmas, 1901. These were severe headache, faintness, swelling of eyelids, and shortness of breath. Swelling of the feet and severe pain in the loins followed.

A doctor saw her for the first time on the 24th of February, and said she had "dropsy." He also tested the urine, and said it was "very bad." On the 26th she vomited several times, and at 10.30 a.m. the first fit occurred. This was followed by another an hour later. Her mother was then present, and describes it thus :—It began by her saying that she could not see anything, then her face went black and twitched ; the jaws were clenched. Urine was passed unconsciously, but not the fæces. The

* Clifford Allbutt's 'System of Medicine,' vol. vii, art. "Eclampsia."

tongue was bitten, but there were no definite convulsive movements and no screaming.

Four more fits occurred before admission to the hospital at 4 p.m., and she was taken up to the ward in a state of coma. A little later she could be made to answer "yes" or "no," but any further attempt to rouse her was resented. On examination there was considerable œdema over the whole body, the skin was dry, the mucous membranes pale. Temperature was 97·8°, pulse 78. The breasts were large, with both primary and secondary areolæ; serum was present. The uterus could be felt high in the epigastric region. Evidently the pregnancy was eight months or more. A catheter specimen of the urine showed a heavy trace of albumen.

A fit occurred soon after admission, and lasted five minutes. It was followed by deepened coma and stertorous breathing. Chloral and bromide of potassium (āā gr. 40) were given *per rectum*, followed a little later by an injection of morphia (gr. ½).

On vaginal examination the os was found tightly closed, the cervix not obliterated and somewhat hard. The vertex was presenting. The fœtal heart was plainly audible.

An hour later the cervix was rapidly dilated under chloroform to a size sufficient to admit de Ribes' bag. No further attempt was made to hasten labour, and the bag was *in utero* twenty-four hours. During this time the patient remained in a semi-comatose condition, but no fits occurred. The temperature, which soon after admission was 99·6°, rose to 100·6°, and then rapidly, just before delivery, to 104·8°. Directly the bag was removed forceps were applied and an easy delivery effected. The placenta was expressed, and appeared normal. An intra-uterine douche was given. There was no excessive bleeding, but shortly after delivery the pulse became weak and running. Intra-venous injection of saline (four pints) caused temporary improvement only, but upon its repetition a few hours later, combined with a hypodermic

injection of strychnine, there was a decided rally, the patient becoming fully conscious. At the time of infusion a few ounces of blood were withdrawn, and were subsequently used in the experiments on toxicity recorded later.

The following morning temperature was 97·8°, pulse 108, respirations 32 per minute, breathing laboured. There was occasional dark brown vomit, slight in amount. The œdema was more marked. The urine was acid, sp. gr. 1022. Albumen one sixth; no blood, sugar, or deposit. Measurement for the twenty-four hours was thirty-three ounces. A slight tinge of jaundice was now noticed for the first time. The liver could not be felt. Its area of dulness was normal. There was no hepatic tenderness. The spleen was not felt. Slight shifting dulness was noted in the flanks.

The next day (March 1st) the condition was very similar save that the jaundice was more marked. There were no hæmorrhages. The maximum temperature was 100·2°. The bowels had now been well opened by aperients and enemata. The stools were not clay-coloured.

On March 2nd the urine was dark in colour. It contained albumen—still one sixth only. No attempt was made to distinguish between serum-albumen and paraglobulin. Microscopically some blood-cells were seen (possibly a contamination from the vagina), and a few hyaline and granular casts, stained with bile. Also some ammonium urate crystals and débris.

An attempt was made to examine the fundi, but it was found impossible without anæsthesia.

The girl was lying in a semi-comatose condition. The skin being dry and pungent, hot-air baths were ordered, and diaphoresis followed. Towards evening, however, the breathing became worse, and then suddenly the pulse failed. Saline infusion (ten pints) caused a temporary rally, but death took place at 1.30 a.m. on March 3rd. The temperature just before death was 101·4°.

The autopsy took place twelve hours later. It was conducted by Dr. Colman, and the following notes are from his report. I was unfortunately unable to be present.

"*Autopsy.*"—The body was very fat. All the tissues were moderately bile-stained.

The liver was not much altered in shape or size, but was extremely flabby. It weighed 55¼ ounces. On the anterior margin, and also at the convexity of the right lobe, there were two infarcts, wedge-shaped, firmer than the surrounding tissues, and slightly raised. They were evidently quite recent (a few days), and had a very definite margin. There was no trace of suppuration; there was no blocking of the main trunk of the portal vein.

On section the liver generally was of a dull ochre colour; the outlines of the lobules were not apparent; the whole organ was very friable, and evidently fatty. The affection was uniform. There were no advanced "red" patches, and the organ as a whole was not diminished in size, but there seemed little doubt that the liver was in an early stage of acute yellow atrophy.

The kidneys were not enlarged. The capsule stripped off readily. On section, except for some mottling of the cortex, probably due to fatty change, there was no macroscopic evidence of disease.

The spleen was much swollen. On section it was soft and diffluent.

Heart.—The valves were normal. There were numerous hæmorrhages under the endocardium of the left ventricle, but no other abnormality.

The lungs were healthy. There was calcification of one or two of the bronchial glands, but no recent tubercle anywhere.

The uterus was relaxed. There was a good deal of decomposed clot in its cavity. Fallopian tubes and ovaries were normal.

The brain was not examined.

Portions of the liver and kidney were cut and stained in the clinical laboratory at the hospital. Some of the sections were stained by the ordinary double stain (eosin and hæmatoxylin); others by special stains for fat, such as osmic, scharlach, etc.

Dr. Seligmann, the superintendent of the laboratory, also kindly undertook the investigation of the toxicity of the blood, and examined a small quantity of urine passed just before death for leucin and tyrosin. I do not propose to give the details of the somewhat complicated chemical method employed, but will simply state the result. Leucin balls were found; tyrosin was not found.

The method adopted to determine the toxicity of the blood was roughly as follows:—The blood was received in a clean vessel, and a small quantity of guaiacol added to preserve it. It was kept in an ice chamber for some weeks, and then the clear serum was injected into a guinea-pig, the method employed being that of subcutaneous injection.

For purposes of comparison the blood withdrawn from two cases of uræmia, in hospital at the same time, was examined. One case may be shortly described. He was a man aged 32, suffering from fits and subsequent coma. The urine contained hyaline, granular, and fatty casts. No blood. Albumen 2 grammes per litre. Urea 4 grains per ounce. The arteries were thickened. Post mortem the kidneys were seen to be small; the capsule stripped, but the surface was granular. The cortex was soft, pale, and dirty yellow. The liver was engorged and fatty. There was hypertrophy of the left ventricle. It was a case of chronic nephritis, with the most marked changes occurring in the convoluted tubes.

The other case was rather a chronic "interstitial" nephritis, with the clinical phenomena of chronic uræmia.

Five c.c. of the "eclamptic" blood were injected into two guinea-pigs, weighing respectively 170 and 205 grammes. Both animals died in less than twenty-four hours. Post mortem there were no very obvious naked-

eye changes. The toxicity of the blood-serum was therefore 2·5 per cent., or at least it was not more than this, though possibly less.

The comparison was made by injecting roughly proportionate quantities of serum from the cases of chronic uræmia.

The actual quantities used were—

(*a*) 9 c.c. from case of chronic tubal nephritis injected into guinea-pig weighing 287 grammes.

(*b*) 6 c.c. from case of chronic interstitial nephritis injected into guinea-pig weighing 220 grammes.

In neither case did death follow; in fact, the only visible change produced was a certain loss of briskness.

The microscopic appearances will now be shortly described.

Liver.—(*a*) Low power. The outlines of the lobules are for the most part fairly distinct. There is little cell infiltration round the interlobular vessels, which are themselves not thrombosed. The cells are faintly stained and vacuolated. Although the change is fairly uniform it is most marked in the central zone of the lobule.

(*b*) High power. The cells are seen to present various stages of degeneration. In those least affected the nucleus is still present, and stains fairly well with hæmatoxylin. The protoplasm is granular, and contains a number of fatty masses, or appears vacuolated, the spaces being, no doubt, due to the dissolving out of fat. These cells are mostly situated at the periphery of the lobule. More centrally there is extreme degeneration. The nuclei are very faintly marked, or exist as fragments only. The protoplasm has shrunk and is vacuolated. In many of these cells, indeed, no nucleus is to be seen, and the protoplasm is represented by a few irregular strands stretched across the cell.

The connective-tissue cells have not degenerated, and their nuclei stain well, suggesting a possibly fictitious increase in their number.

There is a desquamative catarrh of the bile-ducts, the

epithelium being shed, and in places blocking the lumen, but the cells are apparently not themselves degenerate.

The sections stained with osmic appear almost uniformly black, and microscopically the greater part of the cells are seen to be almost entirely filled with fat.

Kidney.—(*a*) Low power. The changes are most marked in the cortex. The majority of the convoluted tubules are seen to be affected. The protoplasm of their cells is clouded. The cells themselves often contain no nuclei, so that whole transverse sections of tubules may be observed with one, two, or even no nuclei.

The glomeruli seem for the most part unaffected, and the wide space sometimes present between them and Bowman's capsule is probably due to defective preparation. In the medullary rays the loops of Henle appear practically normal. The connective tissue is not increased, and there is little or no infiltration of leucocytes. The capsule is not thickened.

(*b*) High power. In the tubules in which nuclei are present the cells are seen to be granular. In those in which the nuclei are not differentiated they are not only granular, but also the part of the cell towards the basement membrane is for the most part occupied by fairly large discrete fatty globules.

In a few tubules there is desquamation of epithelium, and here and there it seems as if there was an attempt at the formation of new epithelium. Although the glomeruli are little affected a few cells appear vacuolated, with their nuclei stained irregularly. There is no trace of a fatty change.

Remarks.—I do not propose to enter into any discussion of the treatment of eclampsia. Morphia, induction of labour, saline infusions, etc., were all tried, but without success. The clinical history is interesting, and has been detailed at some length, but the main interest of the case lies in the autopsy and the light which it throws on the pathology of the disease.

Speaking generally, the post-mortem signs were those

of a case of acute yellow atrophy of the liver in an early stage. It was, in fact, so described by Dr. Colman at the head of his report. But clinically it was a case of eclampsia. It is true that shortly before death the skin became jaundiced and the urine high-coloured. But the occurrence of jaundice in cases of eclampsia is now well recognised. In the discussion on eclampsia at the meeting of the German Society for Gynæcology at Giessen in May, 1901 (reported in the 'Centralblatt für Gynäkologie,' June, 1901, p. 700), Schmorl, of Dresden, in an analysis of seventy-three cases, with autopsies, mentions that icterus was present in ten cases, and that in three of these the clinical symptoms suggested the diagnosis of acute yellow atrophy. But he adds that exactly the same changes were found in the liver as in the cases of eclampsia without jaundice, and he goes on to deprecate any separate classification of the cases where jaundice occurred.

The onset of the illness must also be remembered—headache, vomiting, dyspnœa, and dropsy, culminating finally in fits and coma. When admitted to the hospital she was comatose, with marked general œdema and albumen (one sixth), but no jaundice or other indication of acute yellow atrophy.

It must be admitted that the urinary changes were not characteristic. The exact quantity of urine passed was difficult to measure, but certainly it was little diminished from the normal. On two days the amount measured was respectively thirty-three ounces and forty ounces. Albumen was always present in considerable quantity, but never more than one sixth. I regret that there was no estimation of urea.

It should be noted, too, that the liver dulness was not diminished, and that after death the organ was found little altered in shape or size, and weighed 55¼ oz.

With regard to the microscopical characters I would call attention to the following points:—(1) there was none of the infiltration round the portal vessels and

formation of embryonic fibrous tissue, which has been described in acute yellow atrophy, at least in advanced stages of the disease; (2) the degeneration of the individual cells is most marked at the centre rather than at the periphery of the lobule; and (3) the amount of fat present is far more than is usually seen in acute yellow atrophy, where the granular débris is in excess of the fat.

The lesions are characteristic not so much of acute yellow atrophy as of some acute toxæmia.

Since Pilliet described them in 1889 similar changes have been found in almost all cases of eclampsia where the liver has been subjected to microscopical examination. They were present to a greater or less degree in seventy-one of the seventy-three cases referred to by Schmorl in the discussion at Giessen previously mentioned, and their resemblance to those of acute yellow atrophy and phosphorus poisoning has often been pointed out. The question of phosphorus poisoning need not, I think, be considered in this case. There was no reason to suspect it, and the history of the onset is against the diagnosis.

It is perhaps permissible to suggest that the distinction between eclampsia and acute yellow atrophy occurring in a pregnant woman is of no very great importance. The latter is, after all, only a name describing a certain morbid condition of the liver found post mortem, and produced by some toxic agent, or agents, at present unknown. Puerperal eclampsia, too, is now very largely regarded as a toxic disease, though the toxin remains undiscovered, and its source uncertain.

But from reading the English text-books, and the discussion in this Society last year on Dr. Hey Grove's paper, there would seem to be some confusion and considerable difference of opinion. It is doubtful whether at least two classes of cases are not commonly described under the heading eclampsia: (1) where the kidney is primarily at fault, and the case is one of poisoning due to imperfect elimination of toxins; and

(2) where the production or absorption of toxins is excessive.

In the first case the lesions post mortem are most marked in the kidney, and are primarily of an inflammatory character. The disease is really uræmia, occurring during pregnancy.

In the second case the most characteristic lesions are in the liver, and are degenerative, the kidney showing similar changes but to a less extent.

The case here recorded seems to me to belong to the latter class, and to be very closely allied to acute yellow atrophy. Perhaps we have reached the stage when the term eclampsia might be given up, and all such cases considered and reported under the heading puerperal toxæmia, while recognising that the actual toxin or toxins have still to be discovered.

I have not ventured to adopt this heading myself, but it has been done already in America, for example, by McCone in a short article in the 'American Journal of Obstetrics' for May, 1902, p. 660.

That the blood in this case was very highly toxic is proved by the experiments of Dr. Seligmann. Certainly in a recent paper Eden* has criticised the methods adopted for determining the toxicity of urine and blood-serum, and has pointed out especially how the experiments of Stewart proved that the older results, where care was not taken to prevent contamination, might be practically disregarded. Some of the later results seem, however, to be generally accepted, *e. g.* those of Tarnier and Chambrelent, who in two cases of eclampsia found the toxicity of the blood-serum to be from 3·3 to 4·3 per cent., that of normal blood-serum being 10 per cent.; *i. e.* in the one case 3·3 c.c. would kill 100 grammes of rabbit, while in the other case it would require 10 c.c.

In the case here reported, if the precautions used justify us in accepting the result, as I assume, the toxicity of the blood was even greater than in either of

* 'Journal of Obstetrics and Gynæcology,' Feb., 1902, p. 192.

Tarnier and Chambrelent's cases ; 5 c.c. of blood-serum was sufficient to kill first 170 grammes of guinea-pig, and then in a later experiment 205 grammes, which is equivalent to a toxicity respectively of 2·94 and 2·5 per cent. The fact that guinea-pigs were employed by Dr. Seligmann, while Tarnier and Chambrelent used rabbits, may to some extent vitiate the comparison, but the high degree of toxicity is made especially apparent by the control experiments with blood from cases of chronic uræmia.

Where the "eclamptic" blood had caused death in less than twenty-four hours proportionate doses of "uræmic" blood produced only loss of briskness. So far, therefore, as one comparison can carry us this would seem to indicate that the blood-serum of a patient suffering from "puerperal eclampsia" has a considerably greater toxicity than that drawn from ordinary cases of uræmia, even in the stage of coma.

Dr. Williamson considered that under the term "eclampsia" we grouped together, at the present time, conditions which had very little in common with one another. On the one hand there was a well-marked group of cases in which the patients were the subject of chronic nephritis ; in these patients what we termed eclampsia was really a uræmic condition, and, though modified by pregnancy, still differed in no essential from uræmia occurring in a non-pregnant woman. But there was another and an entirely different class of case, in which the convulsions appeared to depend upon an acute toxic poisoning, the stress of which fell more especially upon the liver, and the kidneys might almost entirely escape damage. In support of this contention he quoted a case recently seen in which forty eclamptic fits occurred within twenty-four hours of delivery. The urine was not reduced in amount, the percentage of urea never fell below 1·6 per cent., only a slight cloud of albumen was present, and no tube-casts were found. After the cessation of the fits, however, the patient became deeply jaundiced, and bile was found in the urine. The patient recovered.

Dr. Drummond Robinson referred to a case in which, at Dr. Champneys' request, he had made some experiments with the blood-serum of a patient who, during her first pregnancy, had developed jaundice and albuminuria. Considerable quantities of the blood-serum from this case were injected into guinea-

pigs without producing any effect. This patient had no fits, and made a good recovery after the induction of premature labour.

Dr. Eden said he thought the case, which had been so admirably reported by Dr. Bell, was a very important one. It served to support the view, now gaining much favour abroad, that it was possible to divide cases of eclampsia into two principal groups—hepatic and renal. The morbid anatomy of eclampsia had not perhaps received as much attention of late as had been paid to experimental work in connection with the toxæmic theory of this disorder. But the occurrence of well-defined changes in the liver, consisting chiefly of hæmorrhages and degeneration of hepatic cells, was now well established, and it had, of course, been long recognised that marked changes might also be found in the kidneys. Dr. Bell's case appeared to belong to the hepatic class, and the relation of this class to cases of acute yellow atrophy was one of the most interesting problems connected with the subject. Dr. Bell appeared to sympathise with the view that eclampsia was produced by a toxic condition of the blood. This might be so, but toxæmia, after all, was only a symptom, like eclampsia, and we were therefore no nearer a satisfactory explanation of the pathology of the condition. The real problem that had to be faced was, how did the toxæmia arise? Unfortunately no answer could at present be given to this question. When physiological chemists had succeeded in separating from the blood of eclamptic women definite toxic bodies, whose properties could be accurately studied, some progress might be made in settling this very difficult question.

Dr. Cullingworth said that he was present at the autopsy of the patient whose history had just been given by Dr. Bell, and he was, he believed, the first to pronounce it a case of acute yellow atrophy of the liver. At any rate, he quite agreed with Dr. Colman in the view he took. The case was one in which an advocate might present a strong case both for and against that diagnosis. The matter had been put before the Society very fairly by Dr. Bell. There was much that was still to be elucidated both about the pathology of puerperal eclampsia and that of acute yellow atrophy of the liver, and it was quite possible that some day both might be found to be capable of being classed under one general heading. The difficulties of such a case as this would then be cleared up, and indeed this case might prove valuable as a sort of connecting link, all the more valuable from its having been recorded without any attempt to fit the facts on to some favourite theory. There was just one point on which he should like to ask Dr. Bell a question. The hæmorrhages found in the liver were extensive and remarkable. He was not sure that their extent had been

actually measured and recorded in figures, but from *his* recollection he should say the larger one had a sectional area of at least three inches by two and a half inches. He feared he was not a sufficiently expert pathologist to be able to say whether such a condition was ever met with in puerperal eclampsia with kidney lesions only. He would be glad to hear Dr. Bell's view on this point.

Dr. Amand Routh rather doubted the diagnosis of acute yellow atrophy in this case owing to the absence of atrophy. He saw a lady six months pregnant who was seized with severe vomiting, slight albuminuria, jaundice, and passage of blood *per rectum*. A diagnosis of acute yellow atrophy was made and the uterus emptied. The following day puerperal eclampsia ensued and she died, but no post-mortem examination was allowed.

The President did not think this was an ordinary case of puerperal eclampsia. On the contrary, it was a very unusual case, for on the one hand the urine was never loaded with albumen, and on the other albumen was not quite absent. Again, there was marked jaundice, which was uncommon in puerperal eclampsia. Hence, although the pathological changes in the liver and other viscera were of great interest, it did not follow that they would be found in ordinary cases. He deprecated the use of the term puerperal toxæmia, for it was founded upon a still unproved theory, and gave no picture of the case like the term puerperal eclampsia did.

RETRO-PERITONEAL LIPOMA WEIGHING THIRTEEN POUNDS TWELVE OUNCES.

By Alban Doran.

I consider it my duty to exhibit this specimen of a lipoma, not omental, but in every sense entirely retro-peritoneal. Its removal proved extremely difficult, and the result, I regret to say, was death. Already Homans, of Boston, has very properly made public the equally unfavourable results following the removal of two still larger tumours of the same kind; whilst Terrier and Guillemain have shown that even an exploratory operation may

prove fatal, and have questioned, not without reason, whether it be justifiable to attempt the removal of a tumour of this kind.

M. D. A—, aged 47, came under the care of Dr. Cuthbert Lockyer early in June. She complained of abdominal swelling, and states that ten months ago her uterus came down and a ring-pessary was applied. Discharge occurred and gave her trouble. Dr. Lockyer examined her in the out-patient department of the Samaritan Hospital, and removed the pessary. He detected an abdominal tumour, ill-defined in character, and sent her into my wards at the hospital.

The patient was pale and rather stout. She had been married twenty-five years and borne seven children; the youngest was eight years old. She seems to have had an attack of pelvic inflammation after her sixth child, but no traces remained of it, as I verified at the operation. Her friends had recently told her that she was growing stout.

The abdominal walls were much distended, though not actually tense. There was resonance in front and, after the administration of purgatives, also in the flanks. A soft tumour could be felt in the umbilical region; it did not come down to the pubes, and lay entirely above the pelvic brim; the uterus was small and moved freely. The borders of the tumour seemed easy to define; it was about six inches in vertical, and a little less in transverse diameter. It felt not unlike a tumour of the parietes, but when the patient lay down there was resonance over its surface.* There was some lateral movement, not very free. The tongue was clean and slightly glossy, the appetite good, and the bowels well opened. The temperature rose to over 100° on the night of admission. The urine was clear, medium yellow, sp. gr. 1022, and free from albumen. There was no œdema of the lower extremities, and no dilatation of their veins. The pulse was 84, small and regular.

* I once detected a resonance over a broad flat fibroma of the parietes

Dr. Hamilton Bell detected "first sound at apex blowing in character, but no distinct murmur; sounds at base healthy."

Diagnosis was very uncertain; I therefore operated on June 21st, assisted by Mr. Butler-Smythe.

On opening the abdomen an enormous fatty tumour came in view. It was its prominent anterior portion which alone could be detected on palpation. The omentum and transverse colon lay high up; the omentum, I may add, was remarkably short and thin. The tumour was covered anteriorly by the posterior parietal peritoneum below the mesentery; I could trace the serous membrane on to the pelvic viscera, which were quite normal.

I enucleated the tumour with ease in front inferiorly; there was little difficulty in freeing its sides, but above it passed up very high, behind the abdominal viscera. It was bilobed, with a deep vertical fissure, complete excepting for a bridge of fat about two inches thick, which connected the lobes a little below the umbilical level.

I succeeded in getting my hand above the left lobe, high up in the flank; its upper part looked like a sarcomatous kidney, but had no vascular connections and no duct. Then I drew the whole left lobe out of the wound after securing a few vessels. I could now detect on the inner aspect of the right lobe a small, very spleen-like organ, purple from congestion. There was a distinct capsule, which seemed inclined to peel off, like the capsule of a kidney and unlike that of a spleen. The vessels ran from the hilum into some main artery and vein at the normal level of the bifurcation of the aorta. I did not search for a ureter. At first I took this organ for the spleen, but as it lay mixed up with an entirely retro-peritoneal fatty tumour, I have no doubt that it was a right kidney placed abnormally low.

The upper part of the right lobe passed up very high (much higher than was the case with its fellow); I drew it out of its capsule behind the liver, but now I found

that the right lobe had a pedicle of big vessels which ran into the tumour close to the pancreas. Unfortunately there were strong adhesions of indurated fat connecting the growth with the pancreas. That organ, I fear, was damaged during the separation of the posterior part of the right lobe. The big vessels were carefully tied close to the pancreas. The left lobe was, at this stage, only connected with the body by a small pedicle of dense fat with big vessels, also traced to near the pancreas. I secured them and divided the pedicle; thus the left lobe was free altogether. The right lobe was adherent to the outer part of the displaced right kidney: I separated some vascular adhesions. Then the right lobe was separated from its pedicle near the pancreas, and the entire tumour was thus extirpated.

Very little blood was lost during the removal of the tumour; oozing was checked by ligature and pressure. The capsule shrank remarkably. I preferred neither to sew it nor to drain the connective tissue behind it. The large and small intestines fell over the area of operation, and when I had applied the deep sutures to the abdominal wound I found that oozing had practically ceased. The abdominal wound was therefore closed without drainage.

The patient did not show any signs of severe shock when she recovered from the anæsthetic, and did well for about twelve hours; Liquor Strychninæ, digitalis, and enemata of artificial serum were administered. But only six ounces of urine, highly albuminous, were secreted during the first twenty-four hours. Then the suppression became complete, and after a rise of temperature and pulse the patient died thirty-eight hours after the operation.

Unfortunately I was unable to obtain permission for a necropsy. I suspect that some damage was done to important structures in the region of the pancreas. I never saw the left kidney nor anything like its ureter during the whole operation, whilst the right was placed abnor-

mally low down, and was deeply congested, so as to look like spleen.

Description of the tumour.—The entire mass weighed 13 lbs. 12 oz., and consisted of two lobes, separated during the operation.

The *right* lobe measured 37 inches at its widest circumference, 13 inches vertically, 11 inches horizontally, and 5 inches antero-posteriorly. Anteriorly it was smooth; posteriorly it had taken the mould of the contiguous abdominal parietes. It was, roughly speaking, fusiform and flattened.

The *left* lobe was shaped like an omega, and was much smaller than the right. It was contorted but not deeply lobed; the upper part was very firm. In circumference it measured 36 inches, vertically 8 inches, horizontally 11 inches, and antero-posteriorly 4 inches.

Both lobes were mainly made up of fat; there were wide ecchymoses at several points, and the lower part of the left lobe was very firm. Dr. Lockyer is preparing some sections to ascertain whether there be any sarcomatous elements mixed with the fat.

Fatty tumours of the abdomen may be practically intra-peritoneal, and then are usually omental. One of the most remarkable cases is recorded by my colleague, Mr. Meredith.* He styled his report "A Case of Large Omental Lipoma," and distinctly stated that "the intestines lay altogether behind it." Nevertheless Terrier, Treves, and Marmaduke Sheild † include this case amongst retro-peritoneal lipomata in their writings on that class of growth. Meredith's patient was sixty-two years old, and the omental fatty tumour weighed 15½ lbs.; recovery followed the operation.

I admit that pathologically an omental lipoma is retro-

* "A Case of Large Omental Lipoma," 'Trans. Clin. Soc.,' vol. xx, p. 206; also 'Lancet,' vol. i, 1887, p. 880.

† "A Case of Large Solid Tumour removed with Success from the Retro-peritoneal Space," 'Med.-Chir. Trans.,' vol. lxxx, p. 211, third paragraph.

peritoneal, but clinically and surgically it is as intra-peritoneal as is an ovarian cyst. Mr. William Anderson, in his excellent monograph on the "Surgery of the Sub-peritoneal Tissue,"* groups together "retro-peritoneal, mesenteric, *omental*, and parametric lipomata."† But the surgeon must make a distinction. There can be no doubt how to act when an omental tumour is detected; it should be removed, as Mr. Meredith removed his lipoma. On the other hand, doubts have been expressed as to whether a retro-peritoneal lipoma like the present specimen should be removed when exposed at an abdominal operation.

Lennander's case‡ has been repeatedly quoted as though it were clinically and surgically retro-peritoneal; the truth is that it was chiefly omental like Mr. Meredith's, but somewhat more complicated. The patient was a man aged 54, and the tumour was "an enormous lipoma which apparently arose from the great omentum. It filled the entire abdominal cavity, and lay *in front* of the small intestine, stomach, and spleen." But the transverse mesocolon was involved, and on the second day the transverse colon was resected, being gangrenous. An artificial anus remained; it was closing ten months after the operation.

Further researches into the well-known papers on tumours of this kind by Terrillon ('Archives gén. de Médecine,' vol. xvii, 1886, pp. 257 and 434) and Terrier, presently to be quoted, make me doubt whether an entirely retro-peritoneal lipoma like this specimen which I exhibit has been successfully removed save in one or two instances. Terrillon describes them as lipomas of the mesentery. He quotes Péan's case (from a *note incomplète*, let it be remembered) where a fatty tumour

* 'Brit. Med. Journ.,' vol. ii, 1896, p. 1087.

† Ibid., p. 1091, par. headed "Lipoma."

‡ "Ein Fall von Lipom in der Bauchhöhle," 'Centralbl. f. Chirurgie,' vol. xxii, 1895, p. 97, an abstract by the author from the original report in the 'Upsala Läkareförenings Förhandlingar,' vol. xxx, which I have not been able to procure.

weighing 55 lbs. was successfully enucleated from the mesentery of a woman three months pregnant. It was attached by a fibrous pedicle to the periosteum of the bodies of the vertebræ, but in my case there was no trace of any pedicle. Madelung's tumour, successfully removed, resembled mine, a prolongation reaching as high as the liver. A piece of jejunum close to the duodenum had to be resected, being inextricably mixed up with a process of the tumour. Homans* operated on two cases like my own, but even larger (one 57 lbs., the other 35 lbs.); both died close on the operation.

Surgically we must put aside Sir F. Treves' case,† where he simply enucleated a fatty tumour from the broad ligament, removing the ovary and Fallopian tube, which were stretched over it as though it were a paro-varian cyst. Pathologically, as in Meredith's case, the lipoma was retro-peritoneal, but surgically it was unlike the specimen now exhibited.

The literature of the subject shows the dangers of second-hand quotations, which in this case would, on the authority of Anderson, Terrier, and others, lead us to class Meredith and Lennander's cases, as well as Treves', with examples of absolutely retro-peritoneal tumours like that which I now exhibit.

Let us then separate and lay aside for the present omental and broad ligament tumours, and confine ourselves to the type illustrated by this specimen, where there is a big fatty tumour entirely behind the abdominal viscera. I have already referred to Homans', Péan's, and Madelung's cases, the latter two appearing to be the sole genuine cases of successful removal, though there is some doubt as to Péan's case being absolutely retro-peritoneal.

One of the most often quoted examples is Mr. Pickering Pick's "Enormous Fatty Tumour of the Abdomen"

* "On Two Cases of Removal of Immense Fatty Tumours by Abdominal Section," 'Lancet,' vol. i, 1883, p. 449.

† "A Case of Lipoma of the Broad Ligament," 'Trans. Clin. Soc.,' vol. xxvi, 1893, p. 101.

('Trans. Path. Soc.,' vol. xx, p. 337), with a drawing. It weighed 29¾ lbs.; the patient was a man aged thirty-six. The drawing, taken at the post-mortem, shows the relations perfectly, as do the sketches in Terrier and Guillemain's valuable article* on this kind of tumour. Terrier's case thus illustrated was that of a woman aged forty. He explored and found the tumour strongly adherent to the anterior parietes, and far too extensive posteriorly and superiorly to allow of removal. The patient died of intestinal obstruction on the eighth day. Terrier explored the abdomen in another case; the patient was a woman aged fifty-five. He found an enormous fatty tumour occupying the mesentery and the omentum. This fact is interesting; in my own case the omentum was small and thin. Terrier did not attempt to remove the tumour. This exploratory operation was performed in March, 1889. Over three years later the patient was in good health; "the operation," observes Terrier, "seems to have checked its growth."

The results of removal of a true retro-peritoneal lipoma of any size have been unsatisfactory, as the records published by the authorities to whom I have referred plainly show. Anderson reminded us that in seven cases the operation had been fatal, mostly from shock, but in two from intractable diarrhœa,† possibly set up from nutritive disturbance in the portion of the intestinal canal interfered with during the removal of the growth. Anderson believed that progress in asepsis, etc., would make results less discouraging in future, but doubted whether in the diffuse forms the good result of excision would always be permanent.

Asepsis, however, is no defence against damage to large vessels and other important structures in the posterior part of the abdominal cavity, during their separation from adhesions to dense fat in the adjacent part of

* "Note sur les Lipomes rétro-péritoneaux," 'Revue de Chirurgie,' vol. xii, 1892, p. 747.

† See Terrillon's case, loc. cit., p. 260 (death thirty-eighth day).

the tumour. Other injuries may be inflicted before the operator is aware of them. I found the enucleation of the anterior part of the tumour easy, and felt bound to proceed further. But with the consequent further experience, I shall not in future attempt the extirpation of a completely retro-peritoneal tumour. Terrier and Guillemain are right when they lay down a rule that an exploratory operation should be performed, and then the surgeon should not proceed further if the volume of the tumour and its relations to intestine, etc., show that total extirpation as a reasonably safe procedure is not possible. The abdominal wound must be closed, and then, as in one of their own cases, the tumour may cease to grow.

Dr. Herbert Spencer had met with a similar case of a retro-peritoneal lipoma weighing 15 lbs., which he had enucleated without difficulty. The patient unfortunately died a few days afterwards, probably from sepsis, though no peritonitis was found at the autopsy. He thought it important that the danger of operating in retro-peritoneal lipomata should be widely known, and would bring his specimen before the Society. He agreed with all Mr. Doran's observations upon the subject.

Dr. Cullingworth asked Mr. Doran whether, considering that the term "retro-peritoneal" had been used to cover other growths than those to which the term was limited in this country, it might not be well, even at the risk of being charged with pedantry, in the case of such tumours as he had shown that evening, to describe them in the title of the communication as having developed beneath the posterior parietal peritoneum. That would effectually exclude tumours in the omentum and the like from being in the same category.

Mr. Doran was interested in hearing Dr. Spencer's report of a similar case, which confirmed his opinion that, if recognised, a tumour of this kind was best left alone. Dr. Spencer's after history of Sir F. Treves's case was important. In reply to Dr. Cullingworth, who discussed a matter of nomenclature, Mr. Doran thought it best to use the term "retro-peritoneal lipoma," as it was employed by previous writers on the same kind of tumour. No doubt biological terms were more accurate, but they confused surgical writers who had forgotten their morphology. Dr. Giles had made a suggestion with which Mr. Doran agreed. These retro-peritoneal tumours seemed to have teratological associations. Let it be noted that in one

case of the few examples of retro-peritoneal lipoma ever published, namely, his (Mr. Doran's) case, a pelvic kidney was detected. Now in the forty cases which Mr. Doran once tabulated * of fibro-myoma of the broad ligament (an essentially retro-peritoneal growth) a pelvic kidney was detected during the removal of the tumour in one instance (Billroth). As to the supra-renal or renal homologies of these fatty tumours, Mr. Doran left the question for histologists and pathologists to decide.

The specimen was referred to the Pathological Committee.

* 'Trans. Obstet. Soc.,' vol. xli, p. 188.

OVARIAN TUMOUR OBSTRUCTING DELIVERY; POSTERIOR VAGINAL SECTION AND OVARIOTOMY DURING LABOUR; OPERATION AND DELIVERY AT ONE SITTING; RECOVERY.

By John W. Taylor, F.R.C.S.Eng.,

PROFESSOR OF GYNÆCOLOGY, BIRMINGHAM UNIVERSITY; SURGEON TO THE BIRMINGHAM AND MIDLAND HOSPITAL FOR WOMEN.

(*Abstract.*)

The author narrates a case of vaginal ovariotomy during labour, showing the advantages (and difficulties) of this method of treatment.

About 2 a.m. on Sunday, September 29th, 1901, the following note was brought to me from Dr. Bernays and Dr. Whitehouse of Solihull:

"We have a very awkward confinement case—some sort of tumour in Douglas's pouch. We cannot move it, and the head is above the brim, pushed forward and to the right. We have given an anæsthetic and failed to push the tumour away, and forceps and turning alike seem difficult and doubtful. Will you come out with the husband, prepared to operate if needful? The 'waters' broke at 8.30 p.m., and the pains are strong. The patient is about thirty, and this is the second pregnancy."

I arrived about 4 a.m., after a long drive of nine or ten miles, and found, as Dr. Bernays had told me, that the patient, a strong young woman of thirty years of age, who had been married three years and had one child two

years ago, was now in violent labour at full term with her second child, but with a large tumour blocking the pelvis behind the cervix, and obstructing the passage of the head.

On abdominal examination the whole of the abdomen appeared to be filled with the tumour of the pregnancy, which was not displaced laterally in any way, so that the obstructing tumour was evidently directly behind the distended uterus and filling the pelvis. There was no real malposition of the fœtus, the head being ready to engage the brim as soon as the way was clear.

The room was made ready for operation while I considered for a time what I should do. Immediate operative action was undoubtedly imperative, but it was not easy to at once decide whether abdominal or vaginal section would prove the better method of removing the tumour.

If I adopted abdominal section I should evidently have to make a large incision, and probably to eventrate the pregnant uterus, or do a Cæsarean section before I could get at the imprisoned tumour.

If I adopted vaginal section I should have an awkward field for operation; both vulva and vagina being converted, through prolonged pressure from above, into a soft cushion of dilated veins, the wound would be in a dangerous or septic situation for the subsequent delivery; but, on the other hand, I should come directly upon the tumour, and be very likely able to remove it without an abdominal incision, and without incising the uterus. I decided to operate by the vaginal route.

Getting what lamps and candles the house could afford so as to have a good light behind my head, and with aseptic instruments arranged on my right hand, I had the patient anæsthetised by Dr. Bernays, removed from her bed to a low table, and placed in the lithotomy position immediately in front of my operating chair. Dr. Whitehouse and one of my own nurses ably assisted me. It was shortly after 6 a.m., and there were faint indica-

tions of dawn as I began to operate. The vulva and vagina were carefully disinfected, and then a large incision was made behind the cervix into Douglas's pouch. This caused a tremendous gush of venous hæmorrhage, but the cyst wall was immediately seen, and almost as quickly seized and tapped. As some two or more pints of fluid from the ovarian cyst came away, the hæmorrhage lessened, and in a very short time this ceased to be any longer alarming. The collapsed cyst was then drawn down into the vagina and the pedicle felt high up on the left side of the enlarged uterus, but almost beyond reach of the fingers.

This was seized with forceps, and after gentle traction on the tumour a stout ligature was passed over the forceps and tied tightly on the uterine side of the forceps.

The tumour was cut off and the forceps removed. The only hæmorrhage still came from the incision. The pouch of Douglas was well cleaned and the wound plugged by a sterilised pad, but the ends of the ligature were not (at this stage) cut short.

The next important question was that of the delivery of the patient. She was under anæsthesia, the cervix was soft and very dilatable, and after the prolonged anxiety and trouble of the night it appeared wiser to get the labour over, if possible, before the patient had recovered consciousness.

Accordingly I delivered the child by forceps. This was done without any injury to the cervix. The placenta followed by expression, and pressure was maintained over the contracted uterus by Dr. Whitehouse, while I returned to the original field of operation. The cervix was held up by volsella and the parts well cleaned. The pad plugging the posterior incision was then removed and the ends of the pedicle-ligature cut short. This was perhaps the most difficult part of the operation. I had expected that when the uterus was emptied the ovarian pedicle would become much more accessible, and possibly visible as well as tangible. I did not find it so, and had to cut

the ends of my ligature short by the sense of touch alone, within the pelvis. Happily there was no bleeding from within the pelvis, and that of the vaginal wound was easily controlled by passing one suture at each end of the incision. The rest of the incision was filled with an iodoform gauze drain, which passed into the pelvis at the back of the uterus.

The volsella was removed from the cervix, the vagina and vulva made perfectly clean, a light binder applied to the abdomen, and the patient removed to her bed with a hot water bottle to her feet.

Dr. Bernays and Dr. Whitehouse conducted the after-treatment of the case, which was uneventful. The bowels were moved on the following day, and the patient made a good recovery.

The baby also did well.

Dr. Galabin said that Mr. Taylor had not mentioned a mode of treatment which was not always successful, but which in some cases overcame the difficulties very simply. In the last case of the kind he had met with he had punctured the cyst *per vaginam* with an aspirator. This allowed the remainder of the tumour easily to be pushed out of the way enough to permit delivery by forceps without trouble. Ovariotomy was performed about three weeks later. He had rather expected that the puncture might have set up some adhesions, as tapping used to do when performed prior to ovariotomy. No adhesion, however, whatever was found. The tumour had refilled in part, but had suffered no injury from the delivery, although its walls were so friable that it could not be brought up into the abdominal wound without rupture. If the puncture had not succeeded he should have turned the uterus out and performed abdominal ovariotomy. He quite agreed with Dr. Spencer that there should not be too much dread of a fairly long abdominal incision. Dr. Galabin had had a case under his care at Guy's Hospital—he did not know whether it might be the same as that referred to by the President,—in which a suppurating tumour obstructing labour had been evacuated through the pelvis. A suppurating cavity had persisted, discharging behind the cervix uteri. This he dilated up and found hair on the surface, showing it to be a suppurating dermoid. He enucleated the lining, and eventually the cavity closed. So far as he knew the patient remained well; but it was obvious that there might

be other cysts left which might grow, and it would have been better if the tumour could have been removed at first.

Dr. Heywood Smith said that about seventeen or eighteen years ago he had a similar case under his care; he tapped the ovarian cyst *per vaginam*, and delivered the woman. It was not till she was between three and four months pregnant again that she presented herself; he then did ovariotomy during the pregnancy. The patient did well, went her full time, and subsequently had other children.

Dr. Handfield-Jones recorded two cases of suppurating dermoid tumours which had obstructed delivery at full term. In both cases he had thought it best to open the abdomen and remove the tumours by the abdominal route. While performing these operations he had been struck by the difficulties which would have been encountered if he had endeavoured to effect the removal by the vaginal route, for in both these instances the upper wall of the tumour had been densely adherent to coils of small intestine, and great risk of tearing the bowel would have arisen if an attempt had been made to withdraw the growth through an opening in the vagina. The plan of removing the tumour by the abdominal route and then replacing the pregnant uterus and effecting delivery by the natural passages commended itself to him as by far the safest and most scientific procedure. He thought that Mr. Taylor was to be congratulated equally on the success of his operation and the good luck which had attended it.

The President congratulated Mr. Taylor on the happy termination of his case, but he could not help feeling that he had been lucky in finding this ovarian cyst so simple and so free from adhesions. Had it been a multilocular cyst with myriads of small cysts, had there been a lot of adhesions, particularly to bowel, or had the pedicle been difficult to reach, he might have been obliged to open the abdomen after all. He related details of a case in Guy's Hospital where a tumour occupied the pelvis and obstructed labour. It was under such great pressure that it was thought to be a solid tumour. There was no fluctuation, but it felt as hard as any fibroid. A needle was pushed in and pus withdrawn. Then an incision was made and a loculus emptied, a septum was punctured and another loculus emptied, and then a third one, after which it was found possible to deliver. Subsequently another loculus of this multilocular suppurating ovarian tumour opened and discharged near the navel, and the patient left the hospital and was lost sight of. After trying operations *per vaginam* he must say he preferred to tackle these tumours through the abdominal wall. One great danger was the pedicle, which sometimes tore when being pulled down in order to reach it from the vagina.

Dr. Herbert Spencer thought that abdominal ovariotomy was preferable to vaginal ovariotomy in the treatment of these cases. Mr. Taylor seemed to have chosen vaginal ovariotomy partly because he would "probably have to evacuate the pregnant uterus or do a Cæsarean section before he could get at the imprisoned tumour." It could not be too strongly insisted upon that Cæsarean section was quite unnecessary. In Mr. Taylor's case the tumour, which, he understood, contained two or three pints, would certainly have reached above the brim of the pelvis, and might have been opened there, possibly without much difficulty. But in any case by enlarging the incision (and it was surprising through how small an incision the pregnant uterus would pass if taken out one corner first) the tumour could have been easily dealt with, and then forceps could have been applied and the uterus returned. He had treated a case in this way in 1898 ('Obstet. Trans.,' vol. xl) with success to mother and child, and the patient had since had a child naturally without difficulty. Spaeth had published a similar case, and he had recently heard from Dr. Semon, of Dantzig, that he had treated a case in the same way, both these cases also being successful. So far as he knew these vaginal ovariotomies had been performed for impacted ovarian tumour during labour by Rubesca (in this case laparotomy had to be performed to separate the adhesions), by Staude, and by Rapin and Ceresole (see 'Geburtshinderniss durch Ovarialtumoren,' by Conrad Criwitz, 1902). These cases had also been successful, so that the question of the relative value of the two operations could not be settled by statistics, but by considering which operation appeared to offer the greatest safety to the patient. The vaginal operation appeared to him (while having some slight advantages alluded to by Mr. Taylor) to be on the whole inferior, in that it made a wound in the vagina, it did not permit inspection of the other ovary, nor allow of such careful treatment of adhesions or of the pedicle. Mr. Taylor had himself found difficulty in dealing with the pedicle, in that he had tied it by encircling it with a ligature applied beyond a pair of forceps, and had to cut the ligature short by the sense of touch. This appeared to him to be not free from danger of slipping of the ligature; the difficulty had also been met with by Dr. Amand Routh ('Obstet. Trans.,' vol. xliv) during pregnancy; by Dr. Griffith, in whose case the pedicle slipped up into the abdomen; and in Fehling's case, even after abdominal ovariotomy, the ligature slipped during the ensuing labour, and the patient died of hæmorrhage. This case showed the necessity of careful separate ligation of the ovarian vessels in the pedicle in cases of ovariotomy during pregnancy, which would only be satisfactorily performed by the abdominal operation.

Dr. Drummond Robinson stated that his case to which Dr. Herbert Spencer had referred was one in which he had removed an ovarian dermoid by posterior colpotomy: the uterus was found to be enlarged, and some hours after the operation a carneous mole was expelled. He did not agree with the President that a short pedicle increased the difficulty of vaginal ovariotomy in the absence of advanced pregnancy. When the pedicle was too short to be easily and carefully ligatured he was in the habit of using a clamp for a day or two, and he had never seen any but good results from its employment. In such a case as Mr. Taylor's he would not care to use a clamp for the pedicle, and would prefer abdominal to vaginal section.

Mr. Taylor, while acknowledging the good fortune for which every surgeon should be grateful, wished the Fellows to understand that the operation was deliberately chosen, and that this choice was made in consequence of an experience of vaginal cœliotomy extending now over some nine or ten years, during which he had repeatedly removed small ovarian cysts diseased tubes, small dermoid tumours, and extra-uterine pregnancies by the vaginal method. As experience widened, one could generally judge what cases were suitable for vaginal section, and it was only in the minority of cases (possibly some 5 per cent.) that an operation begun by the vaginal had to be finished by the abdominal route. Even when this was necessary he had found that the additional vaginal opening was no disadvantage, being often exceedingly useful for drainage. The chief difficulty of the vaginal operation was undoubtedly the comfortable securing of the pedicle; but (as a previous speaker had already stated) the surgeon could leave a pair of forceps on the stump, if necessary, with perfect safety. In addition, the open method of treating the vaginal wound (with an iodoform gauze drain) precluded the possibility of any serious hæmorrhage occurring without the immediate knowledge of those in attendance. As Dr. Spencer was describing his case, requiring a large abdominal incision, eventration of the pregnant uterus, and delivery of the child while the uterus was still astride of the abdomen, he could not help unfavourably contrasting the operation as described with the simple, direct, and comparatively easy method employed in his own case. Moreover in his own case the patient recovered with no abdominal wound or cicatrix. In the other operation a large wound was made, and if this was closed hurriedly (a proceeding almost unavoidable under bad surroundings) a hernia of the cicatrix was extremely likely to develop later on. Mr. Taylor said he would in no case use simple puncture or aspiration by the vagina. The danger of fouling the peritoneum by oozing from a pus sac or dermoid cyst contraindicated this practice, and in every case that recovered an

operation had to be done later. The method described to-night, Mr. Taylor believed, formed a legitimate and very useful extension of operative practice, which in suitable cases satisfied the requirements of good surgery much better than the more usual method of operation by abdominal incision.

OCTOBER 8TH, 1902.

PETER HORROCKS, M.D., President, in the Chair.

Present—40 Fellows and 3 visitors.

Books were presented by Drs. Cullingworth, Bland-Sutton and Giles, Minot and Bar, the St. Thomas's Hospital Staff, the Middlesex Hospital Staff, the City of New York Presbyterian Hospital Staff, and the Medical Society of Copenhagen.

Mary Thorne, M.D., Clement White, M.B., and Alfred J. Rice Oxley, M.D., were admitted Fellows of the Society.

Richard Henry Whitelocke, M.B.(Oxford) and Jessie Eleanore George, L.R.C.P.(Dublin), were declared admitted.

The following candidates were proposed for election :— Alfred Walter Sikes, M.D., B.Sc.Lond. ; John Abernethy Willett, M.B.Oxon. ; Temulfi Bhicafi Nariman, Licentiate of Medicine and Fellow of Bombay Univ. ; Kathleen Bonnar, L.R.C.P. and S.E. (Calcutta) ; Janet Campbell, M.B., B.S.Lond. ; Alfred Austin Lendon, M.D.Lond. (Adelaide) ; John Inglis, M.D. (Hastings) ; Edith Boardman, M.D.Brux. (Hyderabad) ; H. V. McMahon-Dillon, Capt. R.A.M.C., L.R.C.S.I. ; Theodore Henry Ionides, M.B., B.S.Lond. (Brighton).

UTERUS SHOWING RAPIDLY GROWING EPITHELIOMA OF THE CERVIX; DEATH FROM RECURRENCE FIVE MONTHS AFTER REMOVAL.

By Cuthbert Lockyer, M.D.

E. H—, aged 35, was sent to the Samaritan Hospital on the 28th October, 1901, by Dr. Atkinson on account of uterine hæmorrhage which had persisted for six weeks in spite of treatment. The patient had been married twenty years, and had borne three children; the last confinement took place fifteen years ago. There had been three abortions; the last occurred twelve years before the patient came to the hospital. The confinements were easy, and no trouble resulted from the abortions.

The patient had never been ill until September, 1901, when sudden hæmorrhage started one week after the cessation of a period of five days' duration. This hæmorrhage was accompanied by pain in the left side, but the patient did not lie up at the onset; she had, however, to take to her bed a month later, as the bleeding was nearly constant; seven or eight towels were used daily, and large clots were passed. A yellow discharge was seen after the onset of the hæmorrhage, but this was never noticed before.

When first seen at the hospital on October 28th, 1901, the patient appeared to be well nourished, but was very anæmic and weak. The cervix was bulky, the os irregular, patulous, and bled readily upon examination by the finger. The entire uterus was enlarged; the body was anteverted. There was no distinct proof of the existence of new growth, but the case was at once entered for admission and for further investigation. The

patient went home to bed, and was given large doses of ergot; but the hæmorrhage persisted, the loss being excessive on November 24th and 25th.

On examination in hospital on November 28th, just a calendar month after the first visit, I was startled to find that a large growth, proceeding from the cervix, projected into the vagina. The cervix and growth together equalled the size of a hen's egg, the posterior lip was deeply ulcerated, and had nearly disappeared; the bulk of the new tissue occupied the anterior lip. The uterus as a whole was bulky, but movable; no distinct infiltration of the cervical collar of connective tissue or of the broad ligaments was made out, but the growth showed a tendency to spread on to the posterior vaginal wall. After consultation with Drs. McCann and Hamilton Bell it was decided to remove the entire uterus together with that portion of the vaginal wall towards which the growth was spreading.

The operation was performed on December 4th, 1901. Douglas's pouch was reached with difficulty; many loose adhesions required to be broken down, and these bled freely; the bladder separated very readily; the fundus uteri was drawn through the opening in the utero-vesical pouch, and the broad ligaments tied from above; the outer portion of the left tube was dilated, but it was not removed. There was some infiltration around the left uterine artery, so that this vessel, with the base of the left broad ligament, was ligatured as far out as possible, and the suspected tissue removed. Two square inches of posterior vaginal wall was removed with the uterus. The vaginal vault was not closed; the silk ligatures used for tying off the broad ligaments were left long within the vagina. The opening in the pelvic floor was packed with iodoform gauze.

The patient made a good recovery. On January 2nd, 1902, the vaginal vault had closed, but there was much induration around the scar. She left hospital on January 3rd. One month later she was seen in the ward, when it

was found that recurrence had taken place along the *lower edge of the vaginal incision*, and the growth was now proceeding deeply into the recto-vaginal septum; it was very hæmorrhagic, and the patient complained of losing blood in small quantities daily. She died on May 13th, 1902, five months after operation. There is no record of her condition between the time of the last visit to hospital in February and the date of her death.

The specimen shows the entire uterus, together with the two square inches of posterior vaginal wall removed with it. The uterus measures 10 cm. in the vertical, and 7 cm. in width between the attachments of the two Fallopian tubes. The posterior lip of the cervix is in part quite ulcerated away, and the growth can be seen to extend on to the vaginal mucous membrane. The anterior lip, together with the body of the uterus, has been opened up from the front; this section shows that the growth extends as far as the internal os, but does not invade the body of the uterus. The spread-out anterior lip measures 15 cm. from side to side. No microscopical proof of the existence or non-existence of invasion of the broad ligament is offered.

The sections under the microscope show that the growth is a squamous-celled epithelioma, the most striking feature of which is the presence of large vessels in a state of thrombosis, and much free hæmorrhage, such as is only seen in the most rapidly growing neoplasms.

The object of bringing this case before the notice of the Obstetrical Society is to raise the question as to the most satisfactory method of dealing with cancer of the cervix. The advocates of amputation of the cervix have found that this method of dealing even with early growths gives disappointing results, as recurrence has afterwards occurred in the body of the uterus, so some form of total extirpation is the only method to be thought of.

Three distinct procedures in technique are employed in London at the present time:

(1) The method of securing hæmostasis by forci-

pressure, and leaving the vaginal vault open for drainage (Dr. Horrocks).

(2) The use of the long ligature, and leaving in the peritoneal cavity a drain of iodoform gauze, to be removed in the course of two or at most three days (Samaritan).

(3) The employment of the electro-cautery instead of scalpel, scissors, and ligature (Dr. Herbert Spencer).

From the situation of the recurrence upon the lower edge of the vaginal incision, two inches beyond the spreading growth, it is inferred that implantation had taken place, and that the fresh growth was due to the actual grafting of malignant epithelial cells upon incised healthy tissue in the process of removal. Such implantation in other regions—for example, along the skin incision for amputation of the breast—has been observed even when the growth had not apparently been incised. In the case before us the growth was so large that the risk of implantation whilst using a sharp instrument was obviously great. If such a danger is accepted as real we are prompted to regard the removal by the cautery as the only way in which to safeguard the patient from its occurrence.

The method of performing vaginal total extirpation largely used on the Continent is to restore the pelvic floor after cutting the ligature short; but the statistics of large clinics as to "absolute cures," reckoned on the five years' basis established by Winter, are most discouraging, and show that the ligation method is the most unfortunate of all.

In the 'Centralblatt,' No. 4, 1902, Winter gives the number of "absolute cures" obtained in four clinics as follows:

Berlin . . .	9·5 per cent.
Leopold's . .	10·8 ,,
Kaltenbach's . .	10·0 ,,
Schauta's . .	4·3 ,,

At the Obstetrical Society of Leipzig, in January last,

Glockner published the results he obtained by hysterectomy for cancer of the uterus during a period extending from April 1st, 1887, to July 1st, 1901; 974 cases are included. Of these 260, or 26·7 per cent., were considered operable. Vaginal hysterectomy was performed in 86·5 of the cases submitted to operation. The ligation method was employed in 42·7 per cent., forcipressure in 48·1 per cent., combined ligature and clamp in 8·8 per cent. of the operations. The peritoneum was closed in 45·25 per cent. of the cases; the adnexa on both sides were removed in 60 per cent. of the cases. Vaginal hysterectomy yielded a primary mortality of 5·48 per cent. The mortality considered from the point of view of dealing with the vessels gave the following results:

1. Ligation . . . 11·7 per cent.
2. Clamping . . . 4·8 „
3. Combined ligature and forceps 4·3 „

Glockner states that in estimating his final results he has obeyed Winter's statistical rules; all cases admitted of being followed up with the exception of six. He thus puts his results as 9·7 per cent. absolute cures for operations performed up to July, 1901. An obvious criticism to such a statement is that whilst professedly based on the five years' system it is too premature, as some of the cases cannot as yet have enjoyed a freedom from recurrence for one year even, so that 9·7 per cent. is too liberal an estimate.

With regard to the cases of recurrence 71·7 per cent. occurred in the first year, and the average duration of life from the time of the operation was nineteen months.

It will be noticed that the cautery was never employed.

Such statistics only tend to show the very unsatisfactory position which vaginal hysterectomy for cancer of the cervix holds at the present day. As is well known, other routes have been extensively adopted on the Continent and in America, but as yet without promising better results. If vaginal hysterectomy for cancer of the cervix is to hold its own without bringing discredit to surgery it

will probably rest upon a judicious selection of cases, confining the operation to cases where it can be conclusively proved that the growth has not trespassed beyond the cervix, not only in the direction of the connective-tissue areas but also towards the vaginal surface.

Dr. Herbert Spencer thought Dr. Lockyer's remarks upon his interesting case were very valuable. The statement which he understood him to make, that recurrence after high amputation of the cervix occurred in the body, was opposed to Sir John Williams's experience and to his (Dr. Spencer's). He believed that in nearly all cases of early operation in which recurrence took place it occurred in the cellular tissue. With regard to the use of the cautery, he has used it for several years past, both in the high amputation and in vaginal hysterectomy. He called attention again to the remarkable success achieved by Dr. John Byrne in high amputation with the galvano-cautery, a success which had far surpassed that of any other operator. He (Dr. Spencer) thought that success was mainly due to the prevention of cancer infiltration by cauterising the cut surfaces. His own results of high amputation had been very favourable. Three cases of causes complicating labour treated in this way were now well, six, six, and nine years after the amputation. He contrasted the results obtained by Dr. Byrne, Dr. Lewers, and himself after the high amputations with the results obtained by Dr. Jacobs and Dr. Halliday-Croom, in every one of whose cases recurrence rapidly occurred after vaginal hysterectomy. He believed the cautery would be used more and more in vaginal hysterectomy for cancer of the cervix. His own practice in those cases in which for various reasons he removed the whole uterus was to take away the cervix first and then to remove the body. But in nearly all cases of early epithelioma of the portio the high amputation was sufficient, and gave very good results. The slight dysmenorrhœa which often ensued was amenable to medical treatment, and might probably be prevented altogether by steaming the uterus at the time of the amputation, as suggested by Dr. Pincus and Dr. Blacker. He (Dr. Spencer) had steamed the uterus in a number of cases during the last three years with satisfactory results, and had in one case completely destroyed the endometrium by its means.

Dr. W. A. Duncan regretted to hear Dr. Spencer advocate supra-vaginal amputation of the cervix in cases of cancer, as in his (Dr. Duncan's) opinion removal of a portion only of a cancerous organ was bad surgery. Dr. Lewers, who formerly was in favour of supra-vaginal amputation, now removed the whole organ, and Dr. Duncan hoped that Dr. Spencer would follow Dr. Lewers' good example.

Dr. Heywood Smith said that, with regard to those severe cases of cancer that Dr. Lewers had referred to, the interesting question arose as to whether, with the view of their so frequent recurrence, any gain in the patient's life is effected by its removal, or whether the patient might not live as long in the ordinary progress of the disease.

UTERUS REMOVED BY ABDOMINAL PAN-HYSTERECTOMY FOR PRIMARY CARCINOMA OF THE BODY.

Shown by Dr. Lewers.

The patient, from whom the specimen was removed, was a single woman fifty-five years of age. Dr. Lewers saw her for the first time on the 19th of August, 1902, with Dr. Shoppee, of Tufnell Park. She said she had had a watery discharge, at times blood-stained, for six months. There had been one flooding at the beginning of August. The menopause had occurred at the age of fifty, and she had "seen nothing" since till six months ago. She had lost flesh somewhat, and had had a little pain about the lower abdomen occasionally. Pain, however, had evidently not been a marked symptom in the case.

On examination the uterus was found to be considerably enlarged, about to the size of the pregnant uterus at the end of the third month. The vagina was very narrow. The vaginal portion of the cervix was healthy. The sound passed about three and a half inches, and caused some fresh bleeding.

The patient was admitted into the London Hospital, and the uterus was removed by abdominal pan-hysterectomy on September 15th, 1902. As in a case of the same kind which Dr. Lewers reported to the Society in January last, he had occluded the external os by passing a stout ligature with a needle in a handle through the tissues of the

DESCRIPTION OF PLATE VII,

Illustrating Dr. Lewers' specimen of "Uterus Removed by Abdominal Pan-hysterectomy for Carcinoma of the Body."

An interstitial fibroid is seen at the upper part of the body near the fundus. The growth occupies the lower half of the endometrium. The cervical canal is healthy.

Illustrating Dr. LEWERS's Specimen of Uterus removed by Abdominal Pan-Hysterectomy for Carcinoma of the body.

Bale and Danielsson, Ltd.

vaginal portion on each side of the os, and tying the ligature as tightly as possible before commencing the abdominal section. The patient made a good recovery after the operation.

Note on the specimen.—The extreme length of the uterus is five inches and a quarter. The uterus has been laid open by a vertical incision through the anterior wall. There is an interstitial fibroid the size of a hen's egg in the upper part of the anterior wall. The upper half of the endometrium appears healthy to the naked eye, but the lower half of it is occupied by a papillary malignant growth which completely lines the cavity of the body of the uterus in its lower half. The growth is raised a quarter of an inch above the general surface of the adjacent healthy endometrium. The lower limit of the growth is just above the internal os. On the cut surfaces of the uterine wall corresponding to the position of the growth portions of it can be seen deeply infiltrating the tissues.

The growth (a section of which was shown under the microscope) is a columnar-celled carcinoma.

Report of the Pathological Committee upon Dr. Lewers' Specimen.

We, the undersigned, are of opinion that the specimen exhibited by Dr. Lewers on October 8th is a glandular carcinoma of the body of the uterus, and that there is no evidence of any connection with a fibro-myoma in the uterine wall.

G. Blacker.
T. W. Eden.
J. S. Fairbairn.
Herbert Spencer.
C. Hubert Roberts.
G. Bellingham Smith.
J. H. Targett.
A. H. N. Lewers.
Alban Doran, *Chairman.*

UTERUS AND VAGINA WITH THE CHILD *IN SITU* IN THE SECOND STAGE OF LABOUR.

By W. F. Victor Bonney, M.S., M.D.Lond., F.R.C.S., M.R.C.P.

The specimen was removed from a woman who died suddenly just as the second stage of labour was beginning, the cause of death being an extensive pericardial effusion and pericarditis. The woman had had no medical assistance.

The specimen consisted of the parts before named bisected down the middle line, and showed the child to be lying with its head in the upper part of the vagina and in the third vertex position. The uterine wall was closely wrapped around the child, and bore on its inner surface a series of elevations and depressions corresponding to the contour of the child. The most noticeable of these was a deep ridge corresponding to the groove between the head and shoulders of the child. The membranes were separated along a line about an inch above this, but there was no indication of any projection corresponding to Bandl's ring.

The most noticeable feature, however, was the entire blending of the cervical and vaginal canals, which was so complete that it was impossible to distinguish the line of separation between them.

The speaker referred to Drs. Barbour and Webster's case, in which a similar state of things also existed, and he cited this in support of Dührssen's statement that the vaginal cervix is formed as a reduplication of the wall of the genital canal, a reduplication which is obliterated during labour by a process of unfolding.

There was no line or ridge to point the situation of the internal os, this again bearing out Bayer's assertion that

in these cases neither microscopically nor macroscopically can the internal os be distinguished from the lower uterine segment above it.

The head of the child showed a well-marked caput over the anterior angle of the left parietal bone. The cord was wound round its neck. The placenta showed no indication of beginning separation.

The disposition of the peritoneum gave no clue as to the limits of the lower segment, as it extended firmly adherent onto the vagina behind, but in front the extent of firm adhesion was very much less, reaching to somewhere in the neighbourhood of the obliterated internal os.

The speaker hoped at a future time to place sections of the entire length of the uterus before the Society, when the anatomy of the specimen could be more accurately determined.

In conclusion he stated that, judging from his experience in this case, all the more minute measurements derived from frozen sections should be looked askance upon unless the patient had been frozen in the exact position in which death had taken place. The laxity of the parts after death was such that considerable displacement would occur on mere change of position. In this point he agreed with Stratz.

Dr. C. Hubert Roberts thought, in view of the difficulty of determining the exact relationship of the different parts of the uterus here shown, that the peritoneal attachment of that organ would help to determine the upper from the lower uterine segments, seeing that during pregnancy the adherence of the peritoneum to the upper segment was dense and well marked, while over the lower segment the peritoneum was freely movable, and separated from it by a loose layer of areolar tissue. It would be interesting to know if this had been clearly made out in Dr. Bonney's case.

A CASE OF "DECIDUOMA MALIGNUM" AFTER THE MENOPAUSE.

By Frederick J. McCann, M.D.Edin., F.R.C.S.Eng., M.R.C.P.Lond.

A sallow-complexioned woman aged fifty-three years was sent to me by Dr. Batson, of Dorking. She was admitted into the Samaritan Hospital on March 21st, 1902. She had had ten children. Her last pregnancy, nine years previously, terminated at the third month.

Eighteen months before her admission into the hospital her menstrual periods ceased, and no blood loss was noticed until October, 1901, when a sudden gush of blood came from the vagina, followed by continuance of the flow for one day. This free hæmorrhage recurred every four or five days until three weeks before admission, when only a brown discharge was noticed. The severity of the hæmorrhage necessitated her confinement to bed during its progress. She had no pelvic pain, but had been losing flesh.

Bimanual examination.—The uterus was found to be enlarged to about the size of a three months' pregnancy. The enlargement was uniform and soft in consistence. The uterus was freely movable.

A small fleshy polyp was growing from the external os uteri. Slight uterine hæmorrhage followed the examination.

The uterine cavity was explored under anæsthesia on March 24th, 1902.

When I passed a uterine sound into the cavity blood literally poured out of the uterus. An iodoform gauze plug was employed to arrest the bleeding, and as I had not obtained the consent of the patient for hysterectomy she was returned to bed.

Illustrating Dr. McCann's Specimen of Deciduoma Malignum.

Hale and Dawkins, Ltd.

DESCRIPTION OF PLATE VIII,

Illustrating Dr. McCann's specimen of "Deciduoma Malignum."

The anterior wall of the uterus was divided in the middle line, and after the two halves had retracted a vertical mesial section was made through the fundus, blood-clot, and posterior uterine wall. One half of the section is here reproduced.

The central darker portion is composed entirely of blood-clot. Sections made from different parts of this clot failed to show any new growth.

The irregular outline of the clot is well shown in its anterior portion.

The new growth exists between the blood-clot and the uterine wall, and it will be seen that the latter is considerably thinned posteriorly where the disease has invaded its substance.

The cervical canal was free from disease.

I have never seen the non-gravid uterus bleed so freely as it did in this patient. She had informed me that at home the hæmorrhage was most alarming, and very difficult to control.

Two days later, with her consent, I performed vaginal hysterectomy. The uterus was plentifully supplied with blood-vessels, and on removal its peritoneal aspect was bright red in colour. On cutting into the uterus the appearance was most remarkable. The whole cavity was filled with blood-clot, and the uterine wall intensely vascular. The clots were both recent and of old standing, the latter, dark in colour, being more numerous. The growth, as shown by microscopic examination, exists between the blood-clot and the uterine wall (see Plate VIII).

The patient rallied well after the operation, but her subsequent progress was unsatisfactory, and she died on the sixth day from suppression of urine. The urine contained two thirds albumen. She had lost flesh considerably before the operation, and the continued hæmorrhage rendered her condition unfavourable for such a severe trial.

Microscopic examination of the tissue existing between the blood-clot and the uterine wall shows that it is permeated with strands of cells, some of which go into the uterine muscle; the remainder of the tissue is fibrin and clot.

The cells nearest the uterine muscle are rounded, with a distinct granular nucleus, at places vacuolated. These cells are all lightly stained. This layer of rounded cells is more or less covered with elongated protoplasmic masses containing many nuclei rich in chromatin. They are all deeply stained. Some of the protoplasmic masses extend across the field as in Plate IX, fig. 1. There is no structure corresponding to a villus.

Post-mortem examination.

The following is a synopsis of the report of the post-mortem examination made by Dr. Bosanquet.

Pelvis.—Some purulent fluid in the pelvis and dependent parts; no adhesions over pelvic wound; coils of gut quite loose; no enlarged glands in the pelvis; stumps satisfactory.

Abdomen.—Liver 3 lbs., fatty; *no secondary growths.*

Spleen.—Three ounces, soft.

Kidneys.—*Right*, 3½ oz.; *left*, 4 oz., small, cortex very thin. Capsule tears the substance of the organ on removal. Early granular kidneys. Other abdominal contents normal.

Thorax.—Some old adhesions in left pleural cavity.

Lungs.—Œdematous; no pneumonia or bronchitis; some emphysema of anterior margins; *no secondary growths.*

Heart.—Eight ounces; small, flabby; no valvular disease.

Brain and *spinal cord* not examined.

I was present at the autopsy, and noted the total absence of any attempt at closure of the pelvic wound, although six days had elapsed since the operation. The ovaries and tubes were free from disease.

Report of Pathological Committee upon Dr. McCann's Specimen.

We, the undersigned, are of opinion that the specimen exhibited by Dr. F. McCann on October 8th is a "deciduoma malignum." Typical syncytium and discrete cells are present.

G. Blacker.
T. W. Eden.
J. S. Fairbairn.
Herbert Spencer.
C. Hubert Roberts.
G. Bellingham Smith.
J. H. Targett.
F. J. McCann.
Alban Doran, *Chairman.*

DESCRIPTION OF PLATE IX,

Illustrating Dr. McCann's specimen of "Deciduoma Malignum."

Fig. 1 shows a multinucleated cell-mass in the centre of the field, together with cells possessing large nuclei.

Fig. 2 shows elongated multinucleated cell-masses exhibiting many vacuoles so as to give a retiform appearance.

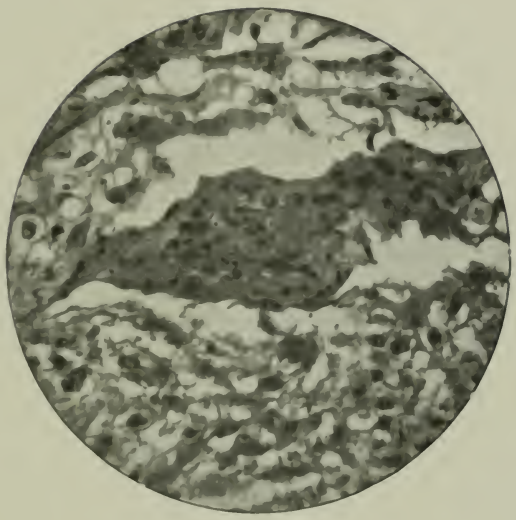

Fig. 1.

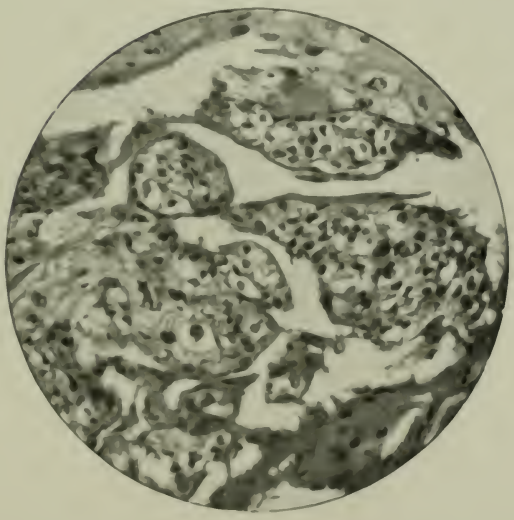

Fig. 2.

Illustrating Dr. McCann's Specimen of Deciduoma Malignum

THREE MONTHS' GRAVID UTERUS REMOVED BY VAGINAL HYSTERECTOMY FOR SQUAMOUS EPITHELIOMA OF CERVIX.

By Dr. William Duncan.

The specimen shown was from a woman aged 34. Married fifteen years, seven children; no miscarriages. She was quite well a year ago. Six months later the periods began to appear every fortnight in normal quantity. Three months afterwards the periods ceased, but there was a yellowish continuous discharge, at times reddish; no emaciation; no cachexia. *Per vaginam* the cervix was lacerated and had a friable growth on it, which broke down easily. The uterus was freely movable and about the size of a three months' gestation.

Vaginal hysterectomy was performed in the usual way, and the patient made an uninterrupted recovery.

Dr. Heywood Smith asked whether, notwithstanding the extensive disease of the cervix, inasmuch as occasionally cancer was partly held in abeyance during pregnancy, it might not have been advisable to allow the pregnancy to go on with the view of preserving the life of the child.

A SMALL OVARIAN TUMOUR REMOVED BY POSTERIOR VAGINAL SECTION FROM A PATIENT WHO WAS ABOUT TWO MONTHS PREGNANT.

By Prof. J. W. Taylor.

The cyst was removed in the usual way after transfixion of the pedicle and ligature. The peritoneal incision was closed by a continuous silk suture.

Mr. Taylor chose vaginal in preference to abdominal ovariotomy, having already diagnosed that the cyst was movable and non-adherent, and in order to avoid an abdominal cicatrix, the stretching of which by the growing pregnancy (if pregnancy continues) is very likely to be followed by hernia and distress.

The patient made a good recovery, but aborted on the fifth day, an occurrence rather common at this stage of pregnancy when any operation is undertaken in the neighbourhood of the pregnancy.

Mr. Taylor remarked that in his experience ovarian tumours complicating a normal (intra-uterine) pregnancy are rarely adherent, and that accordingly they may often be advantageously removed by the vaginal operation. The history of this case appears to show that vaginal ovariotomy, while it has marked advantage over the abdominal operation in the avoidance of any external wound, does not afford any immunity from the occurrence of abortion when operation is performed in the earlier months.

THE PORRO MEDAL, AND REPORT ON PORRO-CÆSAREAN SECTION.

By Dr. Herbert Spencer.

Dr. Herbert Spencer exhibited the medal struck in honour of the late Edoardo Porro, and presented to the Society the report on all the Porro-Cæsarean sections performed up to May, 1901.

COMPLETE INVERSION OF UTERUS OF SEVEN MONTHS' DURATION; FAILURE OF ELASTIC PRESSURE WITH REPOSITORS; OPERATION OF ANTERIOR VAGINAL CŒLIOTOMY, ANTERIOR HYSTEROTOMY, AND REPLACEMENT; RECOVERY.

By John W. Taylor, F.R.C.S.,

PROFESSOR OF GYNÆCOLOGY, BIRMINGHAM UNIVERSITY; SURGEON TO THE BIRMINGHAM AND MIDLAND HOSPITAL FOR WOMEN.

(Received April 21st, 1902.)

(*Abstract.*)

The author describes a case of complete inversion of the uterus causing dangerous hæmorrhage and obstinate vomiting, the treatment adopted for the alleviation of the symptoms, and the operation finally carried out for the reduction of the inversion. He remarks on the rarity of complete inversion, on its clinical character, and on the operative difficulties that may be met with during treatment.

Mrs. E. G—, aged 33, living at Burnley, who had been married for two years, was delivered of her first child on February 9th, 1899.

She was in labour for two days before delivery, and had very great hæmorrhage at the time of the confinement. No instruments were used. The urine had to be withdrawn by the catheter for the first three days, but no vaginal examination appears to have been made during this period. The infant was not suckled.

The first menstruation after delivery began about the middle of March. The patient "flooded" for ten days, and was very weak afterwards. From this time she was never quite free from hæmorrhage, and five weeks later had another severe flooding. These attacks of severe hæmorrhage occurred with increasing frequency, and in August the patient was sent to Blackpool to see "what change of air would do for her." During all this time no examination appears to have been made as to her local condition.

While staying at Blackpool dangerous hæmorrhage again came on, and Dr. Buxton, of South Shore, was sent for. Dr. Buxton discovered a large tumour in the vagina, and recognising that this was the cause of the hæmorrhage, and that the patient's condition was becoming very critical, advised her friends to bring her to Birmingham and place her under my care.

On the 15th of September the patient was brought on an ambulance, Dr. Buxton telegraphing to me to send a nurse to meet her at the station.

On arrival the patient was found to be in the last stage of anæmia, blanched, pallid, almost pulseless, and vomiting everything.

She was carried to her bed, and so serious was her state on admission, that her relatives were requested to stop during the night in case she did not live until the morning.

Nutrient enemata (with brandy) were given every four hours, and on the following morning an examination was made. The patient was found to be bleeding profusely, and to have a pear-shaped tumour hanging from the vaginal roof. No cervical canal could be discovered, nor could any collar or the slightest rim of cervix be found around the tumour.

Bimanually it was impossible to make out any fundus uteri apart from the tumour, and the condition was diagnosed as one of complete inversion of the uterus involving the whole of the organ.

After a few days of complete rest and of rectal feeding only, but without any amelioration of the vomiting and retching, I added chloral (grs. xv) and bromides (3j) to each alternate injection. This soon allayed the vomiting, and I was able to give some milk and water by the mouth. The pulse at this time varied from 120 to 130, and the temperature was slightly raised every evening (to about 100° F.).

I then tried elastic pressure by means of the cup-shaped repositors of the late Mr. Lawson Tait—a method which I have used with success in other (less serious) cases,—but found that with complete inversion the upper part or neck of the tumour was so loose and unstable that no instrument could be kept in proper position for any length of time. Operation was evidently the only way of dealing with the difficulty.

On September 30th, 1899, the patient was anæsthetised and placed in the lithotomy position before a good light. The vulva, vagina, and inverted uterus were well cleaned, and the previous diagnosis confirmed by bimanual, rectal, and recto-vesical examination.

A search was made for the openings of the Fallopian tubes, but these could not be identified.

By pushing the tumour of the inverted fundus well back, and tracing the uterine tissue upwards, the probable site of the limit or edge of the cervix was alone to be made out. The anterior vaginal wall immediately beyond this was seized with a volsellum, as close to the inversion as possible, and a transverse incision made with scissors in the usual way.

This incision almost immediately disclosed the cup of the inversion, for the uterus appeared to have largely detached itself from its usual union with the bladder.

The peritoneum was pushed up, and the anterior margin of the cervix seized on each side of the middle line by volsella, while the uterus was cut up between them with long straight scissors. In doing this the peritoneum was necessarily soon opened, and the inverted

uterus could then be well seen from its peritoneal aspect, with the appendages almost entirely buried within the cup of the inversion. One ovary was resting on the margin of the cup.

Soon after the peritoneum had been opened and the median division of the anterior wall of the uterus carried beyond the cervix into the body of the uterus an attempt was made to replace the inversion, but this was found to be impossible. The appendages had already contracted some adhesions, and it was not until the division had been carried right up to the fundus that these could be separated and the inversion thoroughly reduced.

When this had been effected a rather curious difficulty presented itself. The inversion had existed so long that the peritoneal surface of the uterus (forming the inner surface of the cup) had become considerably smaller than the mucous surface, and when re-inverted or replaced the mucous surface and thickness of the muscle wall (being larger) bulged through the incision, preventing the apposition of the peritoneal edges.

Here I think it would have been better to cut away a wedge of uterine wall on either side of the incision, but wishing to terminate the operation as soon, and to lose as little blood as possible, I tried to bring the sides of the incision together (without this) by a close fine suture of sterilised silk, and succeeded in doing so, but with considerable gaping in the middle part of the wound. Because the peritoneal surface of the uterus was thus imperfectly united, I left a small iodoform gauze drain resting between the uterus and the bladder. The vaginal incision was united by separate sutures on either side of this.

The patient, considering her ghastly appearance and condition, bore the operation fairly well, but for many weeks afterwards I had considerable trouble and anxiety. After a week the wound suppurated, the patient had high fluctuations of temperature, and I thought at one time I must attempt to remove the uterus as a final resort.

Instead of this, however, I found I could remove the suture (which had been a continuous one), and with its removal and the utmost care as to nursing and nutrition, the patient slowly recovered.

She left on November 16th, about six weeks after operation, and convalescence continued uninterruptedly after her return to her home.

In December, 1899, she was able to go out of doors a little every day, and in January, 1900, to take short walks, while normal (very scanty) menstruation had been thoroughly established.

On September 27th, 1900, Mrs. E. G— called upon me. She was perfectly well, of good colour, and no trace of her former trouble could be found on most careful examination.

Again, quite recently (on February 13th, 1902) I heard from the patient that she was able to do all her housework, but that the periods were slightly irregular, the intervals lasting a little longer than formerly.

Remarks.—This is the only case of absolutely complete inversion that I have ever seen or known of. I have looked through the cases of inversion reported to this Society, and cannot find any example of the extreme inversion I have described. The condition has occasionally been theoretically described and figured, the figures usually representing a plain bulging or ridge at the site of the cervix, and therefore indicating that the cervix is easily differentiable from the vagina in complete inversion. It is worthy of note that in the living case before us there was no ridge or dividing line, and on simple vaginal examination the vaginal wall appeared to be directly continuous with the inverted mucous surface of the tumour.

The operation adopted is one which we owe mainly to the suggestion of Dührssen in his manual of gynæcology. The division of the anterior wall of the uterus enables one to deal directly with the inversion, and this with the least additional disturbance of the patient. The only point requiring criticism I have already referred to, viz.

the suture of the uterine incision after reduction has been effected. If there be much tension, and the uterine wall bulges beyond the peritoneal lining, it will be better, I think, to remove the excess of tissue before suture, so as to avoid all undue tension and secure exact coaptation and union. By this means it is quite possible that such suppuration and tedious convalescence as I have had to record might be altogether avoided.

Mr. Butler-Smythe congratulated Mr. Taylor on the success attending his operation. He wished, however, to ask why Aveling's repositor had not been tried in this case as well as Tait's instrument. So far as his (Mr. Butler-Smythe's) knowledge went, Aveling's repositor was almost always successful, and a well-known author even went so far as to say "he had never known it to fail." Mr. Butler-Smythe asked his question because he looked upon Aveling's repositor as a simpler and more reliable instrument than that introduced by Tait. The former, being without any spring, was less liable to slip during the attempts at replacement.

Dr. Victor Bonney was much interested to learn that in Mr. Taylor's case complete obliteration of the junction between cervix and vagina had occurred. This entirely bore out the deductions he had made on the specimen he had just exhibited, and he thought there could be no doubt but that the mechanism by which this was brought about was the same in the two cases.

Dr. Heywood Smith considered that in cases of chronic inversion of the uterus sufficient consideration had not been given to direct manipulation of the uterine body. His experience went to prove that intermittent squeezing of the inverted fundus throughout might prove a tedious process, yet in many cases was very effectual, pressure tending to empty the blood-vessels and causing the muscular tissue to relax; then, if pressure be made with the thumb at the orifice of one of the oviducts where the uterine tissue is thinner, it would be comparatively easy to reduce the inversion.

Dr. Handfield-Jones regretted that he could not agree with the line of treatment adopted in this case. He had had a similar case under his care in which the inversion was so acute that no line of definition between vagina and end of cervix could be made out. The uterus hung as a pear-shaped mass from the vaginal roof, and the finger passed from the vaginal mucous membrane on to the cervical mucous membrane without the possibility of distinction. The same difficulty had arisen as in Mr. Taylor's case, viz. that the womb was so movable that it was extremely difficult to keep the cup of the Aveling's repositor on the uterine

body. However, by packing swabs round the womb in the upper vagina and patient watching, reposition had been effectually secured. He could not help thinking that a similar good result might have been obtained in the present instance. There were two other points worthy of notice. In the first place, the result of the operation in Mr. Taylor's case was to leave a long weak scar in the anterior uterine wall, and this might be a source of danger if the patient became gravid again. In the second place, if a patient was so collapsed and in such a critical state as had been described by Mr. Taylor, would not removal of the womb *per vaginam* be an operation shorter, simpler, and attended by less shock?

Dr. Herbert Spencer thought we were much indebted to Mr. Taylor for pointing out the peculiar absence of any groove between the cervix and body. He alluded to the great value of Aveling's repositor in these cases, an instrument which, as Dr. Cullingworth said, appeared to be almost unknown on the Continent, and was even, he believed, spoken of somewhat contemptuously by a foreign gynæcologist. His own opinion was that there was no method of reducing an inverted uterus to be compared with reposition with Aveling's instrument, and that the cases must be very rare in which the instrument would fail. The difficulty of slipping of the cup off the fundus was present in many cases. In one case of the kind he had held the instrument in place, and had then rapidly reduced an inversion which was previously very obstinate. He was interested in the case of manual reposition mentioned by Dr. Heywood Smith because it seemed to support an opinion he had always held, that with patience continuous pressure (with Aveling's instrument) would overcome the resistance of the uterine muscle, and restore the organ in nearly every case. He would like to know if Mr. Taylor had persevered with the taxis, and had ascertained that the cup had not slipped off the fundus.

Dr. Duncan agreed with Dr. Cullingworth that the Society was indebted to Mr. Taylor for bringing forward another method of reducing a completely inverted uterus. At the same time he (Dr. Duncan) could not help feeling that if Aveling's repositor had been applied to the inversion and kept there by packing the vagina carefully all round, the inversion would have been reduced. Dr. Duncan mentioned a case which he reported many years ago in the 'Lancet,' in which by this method he reduced a complete inversion which had existed for nine years.

Dr. Blacker asked why Mr. Taylor had incised the uterus anteriorly instead of first opening Douglas's pouch and attempting reduction after separation of the adhesions as recommended by Küstner ('Centralb. f. Gynäk.,' 1893, No. 41). He thought the objection raised by Dr. Handfield-Jones one of great importance. In a recent case of his own, where he had reduced a

chronic inversion of some four months' standing by Aveling's repositor, the patient became pregnant, and had recently been delivered of a full-term child. As these cases usually occurred in young women who might subsequently become pregnant, the danger of rupture of the uterus was considerable, more especially when it was necessary, as in Mr. Taylor's case, to carry the incision from the fundus uteri to the external os.

The PRESIDENT did not agree that every case of complete and chronic inversion of the uterus could be restored by means of elastic pressure. No doubt the great majority could, and it was necessary to see that the pressure was directed in the proper axis, for which object packing the vagina round the inverted uterus was sometimes necessary. But he related details of a case which he had seen with Dr. MacDermott, of Petworth, near Pulborough, where elastic pressure by means of an Aveling's repositor entirely failed. It was tried at the patient's home for upwards of twenty-four hours, and then the patient was brought to the private ward at Guy's, and a thorough trial was given to this method, the only result being great pain, for which morphia had to be given. Finally the uterus was removed, and it was obvious that the failure to restore it was due to adhesions. And probably this was the reason of failure in Mr. Taylor's case, though, as it had only been inverted seven months, he should hardly have expected adhesions so early. In his own case it had been inverted a much longer time. In regard to the obliteration of the cervix, this only took place after an interval, for if the rim of the os uteri were felt when the uterus was nearly but not quite completely inverted, and if then the inversion became complete whilst examining, it was quite easy to feel the margin of the cervix; but if the inversion remained complete this margin gradually disappeared, no doubt by a process of stretching. He mentioned the curious fact that when a uterus became inverted during labour it involuted just as soon and just as completely as if it were in its normal position.

Mr. TAYLOR said (in his reply) that no one had been or could still be more appeciative of the value of the treatment of inversion by repositors and elastic traction (after the method of Aveling or Tait) than himself. He had used it successfully, had written on its use, and had always taught that it should invariably be given a good trial before other means were adopted. In this case the method was thoroughly carried out, and he had personally attended to it. But this case had taught him that there were occasional instances in which this treatment was not only inadequate, but might be dangerous; cases in which the congestion of the uterus, the pyrexia, the completeness of the inversion, the excessive hæmorrhage, the production of adhesions between the inverted uterus and its accompanying appendages, and the excessive gravity of the patient's condition demanded

either operative replacement or hysterectomy. He had chosen anterior instead of posterior vaginal cœliotomy because the whole of the uterus was much more under control when this was done, and the central division could be carried out to any extent without difficulty. He had chosen silk as the means of suture, having more reliance on this than on catgut. The resulting wound after the operation was very analogous to that after Cæsarean section, and there was no cause (he thought) to anticipate any special danger in a future pregnancy.

NOVEMBER 5TH, 1902.

PETER HORROCKS, M.D., President, in the Chair.

Present—37 Fellows.

Books were presented by Drs. Garrigues and Lewers.

Mary Ann Dacomb Scharlieb, M.D.Lond., M.S., was admitted a Fellow.

Arthur R. S. Freeland, L.R.C.P. (Leatherhead), and Salvatore Grech, M.D. (Malta), were declared admitted.

The following candidates were elected Fellows of the Society:—Alfred Walter Sikes, M.D., B.Sc.Lond.; John Abernethy Willett, M.B.Oxon.; Kathleen Bonnar, L.R.C.P. and S.E. (Calcutta); Janet Campbell, M.B., B.S.Lond.; Alfred Austin Lendon, M.D.Lond. (Adelaide); John Inglis, M.D. (Hastings); Edith Boardman, M.D.Brux. (Hyderabad); H. V. McMahon-Dillon, Capt. R.A.M.C., L.R.C.S.I.; Theodore Henry Ionides, M.B., B.S.Lond. (Brighton).

Report of the Pathological Committee on Mr. Alban Doran's Specimen of Retro-peritoneal Lipoma (*page* 265).

We, the undersigned, are of opinion that the specimen exhibited by Mr. Alban Doran on July 2nd is a simple lipoma.

G. F. Blacker.
C. Hubert Roberts.
Herbert Spencer.
G. Bellingham Smith.
J. H. Targett.
Alban Doran, *Chairman.*

Report of the Pathological Committee on Sections from the Liver in Dr. Hamilton Bell's Case of Puerperal Eclampsia (*page* 253).

We, the undersigned, are of opinion that the sections from the liver exhibited by Dr. R. Hamilton Bell on July 2nd do not show any evidence of the presence of acute yellow atrophy. There are numerous areas of hæmorrhages, some hyaline and fatty degeneration of the liver cells, and also some portions which exhibit well-marked coagulative necrosis.

G. F. Blacker.
T. W. Eden.
J. S. Fairbairn.
C. Hubert Roberts.
G. Bellingham Smith.
J. H. Targett.
R. H. Bell.
Alban Doran, *Chairman.*

ON A CASE OF PRIMARY CANCER OF THE FALLOPIAN TUBE.

By J. Bland-Sutton, F.R.C.S.

Primary cancer of the Fallopian tube cannot be described as a common disease: extension of cancer to the uterine segment of the Fallopian tubes is not an infrequent event in the later stages of cancer arising in what is termed, in our loose clinical phraseology, "the body of the uterus." On more than one occasion I have carefully investigated uteri removed by operation for suspected "cancer of the body of the uterus," but have been absolutely unable to satisfy myself whether the cancer arose primarily in the uterine segment of the Fallopian tube and extended into the uterus, or *vice versâ*. Certainly the microscope failed to assist, and in this communication I propose to detail the facts of a case bearing on this question.

A childless married woman aged 57 had her menopause at forty-nine; for many years it was known that she had an abdominal tumour of some kind, but its nature had never been made out on account of her obesity, and it seems to have caused her very little inconvenience, certainly no anxiety. In the early part of 1892, to her astonishment she began to have an irregular but rather frequent flux of blood from the vagina, which led her to seek advice: eventually the doctor asked me to see her.

An ordinary examination revealed little: the abdomen, fat and rigid, defied our fingers; the vagina was long and narrow, and nothing but a small button-like cervix sunk in a recess could be made out; the only positive evidence obtained was a free stream of venous blood. When the patient was etherised a fibroid of moderate size could be detected in the hypogastrium intimately associated with the uterus; and during the examination venous blood

flowed freely from the uterus. It was clear that some intercurrent affection, *e. g.* cancer of the endometrium, was complicating matters.

The condition was carefully explained to the patient and her relatives, one of whom is a doctor, and hysterectomy was advised and accepted by the patient. I removed the uterus with its fibroid, both ovaries, and Fallopian tubes (pan-hysterectomy). The fibroid occupied the posterior wall of the uterus, and had a diameter of 12 cm.; the left Fallopian tube ran over the crown of the tumour, and was elongated to 22 cm. (twice its normal length). The ampulla of this tube was dilated, and a process of soft growth protruded from its ostium. This dilated ampulla rested in a peritoneal recess near the brim of the pelvis and by the side of the rectum: unfortunately the soft material projecting through the cœlomic ostium of the tube had infected the adjacent peritoneum, and a ring of soft growth surrounded the terminal part of the tube. In addition to this, here and there along the serous covering of the rectum other nodules of the same kind of growth were detected, but not elsewhere.

I made a very careful examination of the parts removed, and on opening the ampulla of the tube found it filled with extremely soft growth, and the whole length of tube from ampulla to uterus, measuring 15 cm., contained venous blood.

Microscopically this growth exhibits the structure of uterine cancer in its typic form, and if a section had been placed before me I should have been unable to decide whether it came from a cancerous cervical or corporeal endometrium.

A purer form of cancer of the Fallopian tube I have never seen; it arose in the tubal ampulla near its ostium, and remained, so far as the uterine tissues are concerned, confined to the cœlomic segment of the tube. There is an unusually long unimplicated stretch of tube between it and the uterine cavity; the endometrium is quite

healthy. The restriction of cancer to one tube is quite in keeping with the known facts of malignant disease as met with in adults, namely, when it attacks paired organs it is in the immense majority of instances unilateral, whereas in childhood malignant disease is very prone to be bilateral, *e. g.* in the case of the retina, kidney, ovary, adrenals, etc.

The clinical features of this case illustrate a point of some importance: the leading sign in the case was irregular vaginal losses of blood, yet, had there been no fibroid, and had not the uterine cavity been explored for diagnostic purposes, the real source of the bleeding would, in all probability, have remained unsuspected. There has also been a point in dispute in regard to vaginal losses of blood associated with tubal moles. Some maintain that it is difficult to believe that blood shed in the tubal ampulla should be discharged into the uterus. On several occasions I have satisfied myself that blood under such conditions does flow or is forced into the uterine cavity; and in the case under consideration, notwithstanding the attenuated and very obvious elongation of the isthmial (uterine) half of the Fallopian tube, blood in considerable quantities was effused into the tube, and this excessively narrowed tube served as a conduit to conduct it into the uterus, and at the examination of the parts after operation the tubal lumen throughout contained free blood.

This uterus will serve also as an additional and incontrovertible piece of evidence to enable some of us to dispel the superstition that fibroids disappear after the menopause.

Report on Mr. Bland-Sutton's Specimen of Carcinoma of Fallopian Tube and Fibro-myoma of Uterus.

We, the undersigned, have examined this specimen, and are of opinion that there is an interstitial fibroid in the uterus, that the left tube is extremely elongated, and its

outer end the seat of a new growth springing from its inner wall, and quite distinct from any part of the uterus. We have examined the microscopic sections of the uterine growth, and find it is a fibro-myoma; also the growth in the outer part of the tube, which has the distinctive characteristics of a spheroidal-celled carcinoma with very little stroma. From the clinical and anatomical evidence we conclude that it is a case of primary carcinoma of the Fallopian tube. From the fact that the lumen of the tube is dilated and filled with blood, and that the endometrium is thin, smooth, and atrophic, we are of opinion that the growth in the tube is the source of the hæmorrhage.

Herbert R. Spencer.
G. F. Blacker.
J. Bland-Sutton.
J. S. Fairbairn.
J. H. Targett.
Alban Doran, *Chairman*.

Dr. Fairbairn doubted whether the Pathological Committee could throw any further light on the source of the hæmorrhage in this case. It could only report on the nature of the growth and on the state of the endometrium, but could not throw any light on the possibility of the blood having come from the Fallopian tube. That was largely a physical problem, and no investigation of a spirit-hardened specimen could decide this.

Mr. Stanley Boyd asked if the microscopic sections of the uterus showed any endometritis, so often associated with fibroids, which might account for the hæmorrhage.

Dr. Heywood Smith said that as in cases of hydrosalpinx we occasionally observed intermittent discharges of fluid *per vaginam*, so, looking at the dilated and thinned oviduct in this specimen, he considered it highly probable that Mr. Bland-Sutton's explanation was the correct one, that blood came down the tube, and when a sufficient quantity had accumulated, that it was expelled in gushes as he had described.

Dr. Handfield-Jones could not agree with Mr. Bland-Sutton as regards the source of the blood which escaped through the cervix. It seemed to him unnecessary and unduly ingenious to suggest that the blood had been poured out into the tube and then made its way down into the uterus. He had seen cases where gushes of venous blood had been found coming away from the uterus, and in which exploration had shown that the endo-

metrium was perfectly smooth and free from growth, but that some irritating condition in or round the uterine substance had kept up a venous congestion, which relieved itself by bleeding from the uterine mucous membrane.

The PRESIDENT thought the specimen ought to be referred to the Pathological Committee, for it seemed to him that the growth in the uterus looked more like a sarcoma, inasmuch as its cut raw surface was flat like a cut raw potato, and not convex like the surface of a cut fibroid. He had always considered it a fact, and not merely an opinion, that the blood that came away *per vaginam* in cases of extra-uterine gestation was sometimes from the Fallopian tube whether this tube was blocked at its fimbriated end or not; and sometimes from the uterine cavity, either with or without portions of decidua; and sometimes from both these sources. But in this case of primary growth in the Fallopian tube and a large fibroid in the uterus he thought it must be a matter of opinion as to the source of the blood. For supposing a patient had a loss of blood from the uterus such as had been described, and subsequently this uterine tumour had been found, would it not have been considered quite sufficient to explain the bleeding? With regard to the disappearance of fibroids after the climacteric, it was difficult to bring adequate proof. But he had seen in his own practice large fibroids diminish so far that it was impossible to feel them any longer bimanually, so that certainly, for all practical purposes, they sometimes atrophied completely, or if not completely, at all events so far as to be no longer palpable. Finally, he asked whether the malignant nodules on the peritoneum had been removed or left *in situ*, and if the patient was going on favourably.

Mr. BLAND-SUTTON, in reply, thought it idle to deny that the soft vascular mass of cancer in the ampulla of the left Fallopian tube was the source of the bleeding which had been such a conspicuous sign in the patient's illness. The fibroid had existed at least fifteen years without causing trouble, and the patient had ceased menstruating eight years. The endometrium was atrophied and showed no signs of disease, and the fibroid exhibited no evidence of secondary change. If, as some of the speakers suggested, the blood came from the endometrium, they would have to exercise their ingenuity to explain how the blood gained an entrance into the thin and attenuated Fallopian tube, and why it should prefer the narrow canal of the left instead of the natural-sized canal of the right tube. Quite apart from the complication of a fibroid, it is well known that "bleeding" is as conspicuous a feature of primary cancer of the Fallopian tube as of cancer of the endometrium.

ON TWO CASES OF EXTRA-UTERINE GESTATION WHICH WENT TO TERM.

By J. Bland-Sutton, F.R.C.S.

Case 1.—*Pregnancy in the rudimentary horn of a unicorn uterus; fœtus of the full term. It was removed by cœliotomy about six months after its death, with the gestation sac entire.*

Early in October, 1902, Dr. Marsh (Yeovil) placed under my care the patient with the following explicit history and diagnosis:—Mrs. P—, aged 29 years, mother of two children, the youngest being eighteen months old, consulted him for the first time on October 3rd, 1902. In July, 1901, she ceased to menstruate, and in due course she went through the normal phases of pregnancy.

Three months after the last menstruation she had violent abdominal pains and remained in bed a week; these pains recurred at irregular intervals. In April, 1902, she had a vaginal loss of blood, and for three months she had more or less pain almost daily, accompanied by loss of blood. After July the irregular loss of blood ceased, and she began to menstrate regularly; her belly, which previously had been of the size corresponding to a normal pregnancy, now began to shrink, and all pain disappeared.

When the patient came under my care she had a tumour in the belly occupying the middle line, and reaching to the level of the navel; it was hard to touch, free from any contraction, and dumb to auscultation. It felt like a large, hard, subserous fibroid; the uterus was of normal size, and appeared to be unconnected with the tumour. Both breasts contained milk.

Dr. Marsh in his letter, stated "that in his opinion the patient was the victim of extra-uterine gestation, or

possibly conception in the rudimentary horn of a (so-called) unicorn uterus."

With such a clear history, and confirmed in every way by my own interrogations of a singularly intelligent woman, there could be little doubt concerning the nature of the "lump."

On October 13th I carried out cœliotomy, and a sequestered fœtus in its amnion was enucleated with singularly little difficulty from the left side of the pelvis; its chief attachment was near the left cornu of the uterus, but it had carried the sigmoid flexure high out of the pelvis, and the cephalic end of the fœtal tumour had become closely adherent to the mesosigmoid, and the separation of the parts led to some rather free bleeding, necessitating the use of a thin gauze drain. The patient recovered quietly and satisfactorily, and returned to her home twenty-eight days after the operation.

The fœtus is completely enclosed in a more or less globular sac with fairly thick muscular walls, but there is nothing connected with this sac to afford in any way a positive clue as to its character. I endeavoured in the course of the operation to determine its relation to the uterus, and quite satisfied myself, and those who were concerned with the operation, that the sac was not constituted by the broad ligament (mesometrium), but it was continuous with the upper border of this structure and connected with the left side of the uterus by a somewhat broad band of strong vascular tissue. The corresponding ovary and tube were not detected, though carefully sought.

The fœtus (a male), though of full time, is compressed into a very small compass by the contraction of the sac, and the limbs, umbilical cord, and scrotum are so contorted, compressed, and distorted as to resemble the convoluted surface of the cerebrum. The placenta has shared in the general compression, and its circulation had probably ceased many weeks anterior to the operation.

It was, on the whole, fortunate for the patient that the

circulation in the placenta had become quiet, and that the fœtus was contained in a muscular sac, for it made the operation fairly safe and satisfactory, especially in the fact that it enabled me to remove, without any undue risk, the sac as well as the fœtus, whereby the patient escaped the tedious drainage, the risks of a fæcal fistula, which so often complicate these cases, and prolonged convalescence, which drainage of the sac of an extra-uterine pregnancy nearly always entails.

Case 2.—*Probable gestation in the right Fallopian tube. Fœtus removed by cœliotomy two months after term.*

Mrs. B—, aged 35, mother of a boy aged seven years, fell in the "family way" in November, 1901. During the early months of pregnancy she felt more than usual pain, and Mr. Thurston thought he felt a tumour on the uterus. In March, 1902, I saw the patient, and the apparent irregularity of the uterus raised in my mind a suspicion that there was a sessile fibroid on the left side of the uterus incarcerated in the pelvis. I suggested careful watching and a re-examination in a few weeks. In May I satisfied myself that what I regarded as a fibroid might possibly have been a retroverted gravid uterus which had righted itself, for the suspected tumour could no longer be felt in the pelvis, and the case now appeared as a natural uterine pregnancy, the placental hum and the fœtal heart being particularly audible: milk had made its appearance in the breasts, and the patient was free from pain or even discomfort, and joyfully looked forward to the time when she should be delivered. In this, however, she was doomed to be deceived, for though in the month of August she had for a day great pains, as of labour, they were "unavailing," and in September she was still more astonished by the appearance of a regular menstrual period, which was repeated in October: at this time she realised that her belly, which had been unusually large, was now markedly diminishing. These facts were com-

municated to me, and I examined the patient and found the fœtus lying transversely in the abdomen, but quiet and immovable: the breasts still contained milk, and the uterus could be felt of normal size. As I had watched the case in its early periods I at once perceived that the fœtus was free in the belly, and at once made dispositions for its extraction.

On October 27th, 1902, cœliotomy was performed at the Chelsea Hospital for Women, and the fœtus, tightly girt about with its thin delicate amnion, was extracted. The placenta, of the size and shape of a cricket ball, occupied the right half of the pelvis: glued to the amniotic surface of the placenta was a double loop of ileum. The placenta I carefully enucleated and extracted, then detached with a knife the amnion and underlying piece of placenta connected with the ileum; it was then easy to clip the section of amnion quite small and remove the placental villi, and after thoroughly washing the parts with perchloride of mercury solution (1 in 8000) the coil of ileum was returned within the abdomen. I made a careful examination of the placental site, and secured the stump of the left Fallopian tube and the adjacent segment of the mesosalpinx with a silk ligature to control the bleeding. The uterus, rectum, and the uterine appendages were matted together in such a fashion as to prevent any positive recognition of the various structures. The placental site oozed somewhat freely, even after it had been packed with a very hot gauze dab: this made it desirable to drain with a gauze wick, and the wound was closed in the usual manner.

The fœtus was a female of full time, and closely invested with its thin delicate amnion, but no other demonstrable investment.

The placenta seemed to be lodged in a spoon-shaped expansion of the ampullary portion of the Fallopian tube, and I regard it as an instance of that somewhat rare condition in which the amnion "erodes" the tube and

slowly intrudes itself into the peritoneal cavity ('Trans. Obstet. Soc.,' vol. xxxix, p. 178, and vol. xl, p. 308).

The cases are perhaps of some interest in that they afford some data for estimating the probable period at which placental circulation ceases after the death of the fœtus. This, however, is not very important, for there is now a consensus of opinion that, when it is clearly recognised that a woman is the victim of extra-uterine gestation, the sooner it is dealt with by operation the better for the patient, whether the fœtus be quick or dead.

A CASE OF SPONTANEOUS EXPULSION.

Shown by Comyns Berkeley, M.B.

Dr. Comyns Berkeley showed a fœtus born by spontaneous expulsion. The mother, aged 29, was attended by Dr. Miles, of Stantonbury. Her first confinement, in 1895, was complicated by placenta prævia centralis, the child being stillborn. In 1896 she had a miscarriage, and in 1897 she was delivered of a full-term, healthy child. During this last pregnancy she suffered severely from abdominal pain, and the fœtal movements were very feeble. On October 7th she last felt fœtal movements. On October 8th the membranes ruptured. On the afternoon of October 11th labour pains came on, and at 8 p.m. Dr. Miles was called. He found the mother's condition very satisfactory, pulse being normal, and the pains strong, regular, and intermittent. The presentation was diagnosed as a left dorso-anterior. Dr. Miles was unable to reach the neck or the feet, and so endeavoured to deliver the child with forceps applied to the body; but these slipped. The child was born dead at 11 p.m. by spontaneous expulsion, and the mother made an uninter-

rupted recovery. The mother stated she had gone to full term, but the size of the child, seventeen inches long and 4½ lbs. in weight, corresponds to the eighth month.

Dr. Berkeley pointed out the extreme rarity of the condition. In 23,811 confinements at Guy's Hospital not one case was noted.

CASE OF RUPTURED TUBAL GESTATION.

Shown by J. H. Dauber, M.B.

Dr. Dauber showed a case of encysted hæmatocele which he had removed on October 30th at the Hospital for Women, Soho, together with the right Fallopian tube, which was distended with blood-clot, from a patient aged 30, who had come to the hospital a few days previously with the following history.

The last catamenial period was in June. Ten weeks ago she considered she had had a miscarriage, passing a substance "the size of the palm of her hand" (this was probably the decidua). Since then she had had slight continuous vaginal hæmorrhage, with great pain on defæcation. She complained of no other symptoms than these.

Bimanual examination revealed a tense, globular, smooth, elastic swelling filling Douglas's pouch. The uterus was pushed somewhat forwards. The cervix was slightly enlarged and soft.

At the operation the right tube and ovary were found lying in Douglas's pouch, the former distended to the size of a Cambridge sausage, together with a tumour as large as an orange attached to the fimbriated end. The entire mass was readily separated from its bed and ligatured off. There was neither free blood nor clot in the pelvis. The cyst was opened subsequently and found to contain blood-clot. It broke away from the fimbriated

extremity of the tube very readily. The Fallopian tube was not incised, and he now showed it undisturbed.

Report on Dr. Dauber's Specimen of Ruptured Tubal Gestation.

We, the undersigned, have examined this specimen, and are of opinion that it consists of the Fallopian tube and ovary. The ovary contains a hæmorrhagic cyst. The tube is distended by a firm blood-clot, which has burst through the superior wall of the ampullar portion of the tube, through an opening 2½ cm. in diameter; the fimbriæ of the tube can be recognised at the extremity adherent to the ovary. Microscopic examination shows it to contain chorionic villi.

G. F. Blacker.
J. S. Fairbairn.
J. H. Targett.
Herbert R. Spencer.
Alban Doran, *Chairman.*

"PARATUBAL" HÆMATOCELE.

By R. H. Bell, M.B.

The specimen is shown as illustrating the subject of to-night's paper. The patient was in St. Thomas's Hospital in May last under the care of Dr. Tate.

The parts shown are the left tube and ovary with the adherent "paratubal" hæmatocele. The fimbriated extremity of the tube was open, and a probe was passed along it, the tube then being opened up from the front. An oval rupture is seen in the posterior wall, three quarters of an inch from the fimbriated end of the tube.

Lying in the tube can be seen a small transparent sac surrounded by chorionic villi, evidently the amniotic sac. No fœtus can be made out. This sac was teased out from a portion of blood-clot lying in the tube and adherent at the margin of the rent.

Firmly attached to the outer surface of the tube is seen the small hæmatocele, not much larger than a walnut. It is conical in shape, and enclosed in a firm yellow capsule. The blunted apex of the cone was free of capsule, and the blood-clot here was softened, and looked as if it had been torn from some adhesion.

The ovary can be seen closely matted to the tube by stringy adhesions. In it were several cysts containing clear fluid (one the size of a pigeon's egg) and one blood-cyst.

The woman, K. V—, aged 33, was admitted May 7th, 1902. She had had five children; no miscarriages; the last confinement thirteen months ago. Normal menstruation had not returned when in January bleeding commenced, and lasted continuously for one month. During this time there was no pain, and no clots were passed. At the end of the month she had severe pain and began to pass clots. There was also vomiting and difficulty in micturition, necessitating the use of a catheter. The pain lasted for a week. A few days later she was again up and about. In another week the pain recurred with its former severity, and she was driven back to bed. Loss *per vaginam* continued all this time, sometimes with clots, sometimes without.

For three weeks before admission she was not actually in bed, but mainly on the couch, and the discharge was very slight. In hospital there was none at all. Nothing abnormal could be made out on abdominal examination, but *per vaginam* there could be felt on the left side a small swelling extending from the uterus to the side wall of the pelvis. It was firmer in front, and more elastic behind; tender on examination. Douglas's pouch was free.

The abdomen was opened by Dr. Tate on May 15th, and the specimen shown was removed. Apart from it there was not a trace of blood or of old blood-clot present in the peritoneal cavity.

The woman made an uninterrupted recovery.

The specimen is now in the museum of St. Thomas's Hospital.

ON PARATUBAL HÆMATOCELE.

By W. Sampson Handley, M.S.,

SURGEON TO OUT-PATIENTS, SAMARITAN FREE HOSPITAL.

(Received May 27th, 1902.)

(*Abstract.*)

Encysted hæmatocele, with a fibrous sac clasping the ostium, and independent of, though perhaps partially adherent to, the viscera (peritubal hæmatocele), was first described by Sänger and Taylor. It is more frequent than is commonly believed, since the sac has often been mistaken for a portion of the tube. Its capsule consists of fibrous tissue, not of fibrin.

All encysted hæmatoceles arising from tubal bleeding are described by Sänger and Taylor as peritubal, and therefore, necessarily, as the result of hæmorrhage from the ostium. The object of this paper is to show that tubal rupture may produce an encysted hæmatocele adherent to the tube, and enclosing the rupture in its wall. Such a hæmatocele is not peritubal, but rather paratubal. Its sac may be mistaken for a part of the tube.

These statements are chiefly based on a re-examination of specimen 2480 in St. Thomas's Hospital Museum, removed by Dr. Cullingworth, and described in the catalogue as a sacculated hæmatosalpinx.

Clinically the symptoms of the case were eleven weeks' amenorrhœa, followed by vaginal hæmorrhage and recurrent

bearing-down pains during the three months which elapsed before operation. There was a soft elastic swelling in Douglas's pouch; the right appendages were absent from their normal situation; right tubal mole was diagnosed, and recovery followed operation.

The specimen was reported on by a committee of this Society, but no definite opinion was expressed as to its nature.

Re-examination shows a healed rupture in the wall of the tube where the blood-sac is adherent to it. Muscle is absent from the wall of the blood-sac, which exactly resembles the wall of a peritubal hæmatocele,—that is, it consists of fibrous tissue organised from peritoneal lymph, not of fibrin. This and other evidence negatives the supposition that the wall of the tube took any share in the formation of the wall of the blood-sac.

A search through the literature has supplied one example of paratubal hæmatocele in a modified form (part of the mole lay in the sac of the hæmatocele, part in the tube. Fig. 4), and two connecting links or intermediate forms (Figs. 2 and 3) between peritubal hæmatocele (Fig. 1) and the typical paratubal hæmatocele now described (Fig. 5).

It seems probable that the slow bleeding which forms an encysted hæmatocele does not, as is generally held, precede, but goes on *pari passu* with the formation of the sac. Moreover aneurysmoid distension of the developing sac, by continuously altering its relations to the surrounding peritoneal surfaces from which it is derived, separates it from them, and accounts for the otherwise inexplicable tumour-like individuality of the hæmatocele. The original lymph thrown out round the rupture, instead of being stretched out in the form of bridles or membranes, is evenly distended into a complete spherical sac surrounding the blood. The author suggests the word dynamocele as appropriate to such a product of fluid pressure.

In 1893 Sänger * described under the name "solitary hæmatocele" the encysted tumour-like hæmatocele possessing a fibrous wall *independent of the surrounding viscera*, which is now usually known under the name of peritubal hæmatocele.

* Sänger, 'Verh. d. deutschen Ges. für Gyn.,' 1893, p. 282.

In 1894 Taylor, of Birmingham,* independently described the same variety of hæmatocele, in which "a complete cyst wall is formed from the clot, quite independent of the tube or ovary or any other pelvic organ. The complete cyst wall forms a kind of bag or jug, and within the neck of this globose pitcher, so to speak, is the fimbriated end of the Fallopian tube, and the latter may be lightly drawn out of its enclosing sheath, showing its fimbriated end uninjured."

Since peritubal hæmatocele was first described, many cases of it have been recorded. Its frequency is shown by the fact that of fifty cases of incomplete tubal abortion described by Mandl and Schmit,† twenty-eight were accompanied by peritubal hæmatocele. No doubt in the past many cases have been overlooked because the sac of the hæmatocele was mistaken for a distended portion of the tube. Owing to the smooth, almost polished appearance of the outer surface of the fibrous sac, and its comparative freedom in some cases from adhesions, it may very easily be taken for a structure covered by peritoneum.

Sänger found the capsule of a peritubal hæmatocele to consist entirely of fibrin infiltrated by leucocytes. He states that in the outer layers the leucocytes are spindle-shaped, while in the inner layers they are round. The drawing which he gives to illustrate the structure of the capsule is sufficient, I venture to think, to disprove his theory that the capsule consists of fibrin. It shows every stage in the organisation of fibrous tissue from a round-celled infiltration of the outer layer of the blood-clot. The spindle-shaped cells in the outer layers are entirely unlike leucocytes; they are undoubtedly fibroblasts.

Mandl and Schmit,‡ after an exhaustive examination

* Taylor, 'Med. Press and Circular,' July, 1894.

† 'Archiv für Gyn.,' 1898.

‡ Loc. cit.

of their cases by all available chemical, optical, and tinctorial tests, came to the conclusion that the capsule consists not of fibrin, but of fibrous tissue; and the point may be regarded as settled, though doubtless the innermost layers of the capsule consist partly of fibrin.

Sänger has stated * that all intra-peritoneal hæmatoceles connected with the Fallopian tube are peritubal. To quote his own words in translation, "in the first place every hæmatocele arising from tubal bleeding is peritubal; the open tube, itself filled with blood, runs into, and in its abdominal portion is enveloped by the hæmatocele."

This statement has not, so far as I know, been contradicted. Taylor recognises that rupture of the tube may occasionally give rise to a local intra-peritoneal hæmatocele as distinct from a diffuse intra-peritoneal hæmorrhage, but he appears to regard all *encapsulated* (tumour-like) hæmatoceles as products of bleeding from the open abdominal ostium,—at any rate, he does not describe any case of encapsulated hæmatocele resulting from tubal rupture. Thus, after giving a general description of a local intra-peritoneal effusion of blood, and its enclosure by adherent viscera as the result of local peritonitis, he says: †

"The outer layer of the blood-clot consolidates into a more or less perfect sac, and in addition to the adhesions the blood becomes encapsulated by a limiting layer or outer coat derived from its own substance or tissue. Sometimes the hæmorrhage within the capsule ceases altogether; in process of time the adherent viscera become detached, and we may find a perfect sac remaining, closely fitted round the abdominal mouth of the Fallopian tube, blood being found within it. This, which I have described elsewhere, is known as encapsulated hæmatocele."

* Loc. cit.

† Taylor, 'Extra-uterine Pregnancy,' Lewis, 1899, p. 55.

The object of my paper is to show that tubal rupture may occasionally produce an encapsulated tumour-like hæmatocele, clasping the rupture in the tube as peritubal hæmatocele clasps the abdominal ostium. Such a hæmatocele does not surround the tube, and therefore cannot be called "peritubal." I have ventured to call it a "paratubal" hæmatocele. The sac surrounding such a hæmatocele may be so definite as to be mistaken for a portion of the tube.

In the first place I must own that the paper is based on the very careful examination of a single specimen. I have since found one other undoubted case in the literature, and two others which show transitional forms between peri- and paratubal hæmatocele.

The specimen for whose detailed description I ask the indulgence of the Society to-night is No. 2480 in St. Thomas's Hospital Museum. The case was operated upon by Dr. Cullingworth, and to his courtesy and Mr. Shattock's I owe the opportunity of re-examining the specimen.

In the Museum catalogue it is described as a sacculated hæmatosalpinx. Illustrations of the specimen will be found in Dr. Cullingworth's 'Clinical Illustrations of the Diseases of the Fallopian Tubes,' pl. xi, fig. 1, and on a larger scale in Dr. Hubert Roberts's 'Outlines of Gynæcological Pathology,' fig. 43, opp. p. 156.

The following is an abstract of the clinical account of the case:*

A. K—, aged 34, admitted May 14th, 1892.

Three children by the first husband, the youngest born in 1883. After six years' widowhood she married a second time in 1890, and was regular after her marriage until January, 1891, when she fell and hurt her elbow. Menstruation since irregular, at intervals of five to eight

* Cullingworth, "Hæmatosalpinx," 'St. Thomas's Hospital Reports,' vol. xxi, p. 43.

weeks, the flow scanty, and often only lasting one day. Her last period ceased November 15th, 1891.

FIG. 1A.—PARATUBAL HÆMATOCELE. SPECIMEN 2480, ST. THOMAS'S MUSEUM.

1. Uterine end of tube. 2. Lumen of tube, exposed by the section. 3. A bristle passing through the tube to emerge at the ostium. 4. Cavity of hæmatocele. (Compare Fig. 5.)

(Reproduced by kind permission of the Author, and of Messrs. J. & A. Churchill, from Dr. Hubert Roberts' 'Outlines of Gynæcological Pathology,' 1901.)

On February 3rd, 1892, after feeling unwell for three or four days she had a sharp and sudden attack of hæmorrhage, which lasted more or less from that time up to her admission,—that is for three months. The blood has sometimes been red, sometimes dark brown. For about eight weeks she remained entirely in bed, then after a fortnight's semi-invalidism she again took to her bed, and remained there until admission.

Pains like those of labour came on at irregular intervals, followed by an increased discharge of blood and subsequent relief. Between these attacks she was free from pain. No decidua was passed.

On admission her temperature was 99°. Nothing abnormal was felt *per abdomen*. Under anæsthesia the uterus was found of normal length and somewhat retroverted. In Douglas's pouch, adherent to and moving with the cervix, was a swelling of the breadth of two fingers, lying obliquely with the upper and outer extremity directed to the right. The swelling was soft, even and elastic, and bulged the upper part of the posterior vaginal wall forwards. An impulse was conveyed from the fundus uteri to the cervix, but not to the swelling behind it. The right uterine appendages could not be felt in their normal situation. The left could be distinctly mapped out, and were normal.

The swelling was diagnosed as the right tube distended with blood and adherent in Douglas's pouch, and the case was thought to be one of tubal gestation with apoplectic ovum.

The abdomen was opened on May 26th. A smooth, oblong, soft swelling, surrounded by recent adhesions, and about equal in size to a pigeon's egg, was found in Douglas's pouch. On being separated and brought to the surface it proved to be a distended portion of the right Fallopian tube, close to, but not actually involving the fimbriated extremity, which was sufficiently patulous to admit a probe. The swelling was of a dirty yellowish-brown colour, and evidently contained altered blood-clot.

The isthmus of the tube was of normal calibre, and on section was seen to contain a small quantity of brown material (altered blood) in its lumen. The tube was divided and removed. The ovary being normal was separated from its adhesions, but not removed. There was no free blood in the pelvic cavity. Recovery uninterrupted; discharged well on June 25th.

The specimen was shown at the meeting of this Society held in June, 1892.* A committee appointed to consider it returned what amounts to an open verdict. Their report is as follows:

"The specimen consists of the greater part of the right Fallopian tube, 7 cm. in length. Immediately above the abdominal end is an oval swelling the size of a pigeon's egg, which projects freely outwards. The ostium is patulous, and surrounded by fimbriæ, which are somewhat œdematous. The canal of the tube is not only pervious but dilated, so as to measure 5 cm. at its widest part. On section the oval swelling is found to be a cyst filled with apparently homogeneous clot. On clearing out this clot, which is partly adherent, the wall of the cyst appears simple, without any evidence of former loculi. No communication with the canal of the tube could be detected. There is a ragged hole immediately above the fimbriæ, apparently artificial.

"On microscopic examination of the clot no chorionic villi could be detected. The clot was intimately adherent to the wall of the cyst, and the epithelial investment of the mucous membrane did not exist."

After quoting this report Dr. Cullingworth, in his book, adds:

"This was in many respects a remarkable and obscure case. . . .

"The pouch-like dilatation in which the effused blood was found had, in a manner that at present seems quite inexplicable, apparently become shut off from the rest of the tube."

* 'Trans. Obstet. Soc.,' vol. xxxiv, p. 182.

Since Dr. Cullingworth evidently regards his explanation of the specimen as provisional only, I have the less hesitation in advancing the view that it is an encysted hæmatocele lying by the side of the tube.

A naked-eye examination of the specimen as now preserved shows the following additional details:

1. Half the original specimen cut in the plane of the broad ligament is now mounted in the museum. The half of the blood sac preserved is an almost perfect hemisphere. If the original sac was spherical, a strong argument is provided for believing that its shape is the result of internal fluid pressure.

2. There are no remains of adhesions present on the sac, so that those found at the operation must have been very soft and recent.

3. The surface of the sac, though quite smooth, lacks the polished appearance of the peritoneum-covered tube.

4. The tube, where adherent to the sac, is stretched out over its surface. If a piece of thin rubber tubing were stuck upon the surface of a half-distended rubber balloon, and if the balloon were now fully distended, the rubber tubing would be stretched in a similar fashion to the Fallopian tube in the specimen.

5. The tube is pervious in its whole extent, and no communication exists between its interior and that of the blood sac. But a closer examination shows the presence of an obviously weak spot in the dividing wall between the cavity of the blood sac and the lumen of the tube. This is not the ragged artificial tear mentioned in the Committee's report. Microscopical examination proves this weak spot to be a healed rupture in the wall of the tube, filled in by young fibrous tissue containing small masses of altered blood.*

6. The blood-clot within the sac is oldest and firmest in the centre. It has a concentric, coarsely laminated

* A microscopical drawing of the rupture will be found in the Journal of Obstetrics and Gynæcology of the British Empire,' December, 1902, p. 615.

arrangement, almost like that of a healed aneurism. The centre of the clot is formed by a uniform blood mass, pear-shaped in section, and with its narrow end directed towards the rupture in the tube. Its dimensions are ·8 by 1·5 cm. in section.

7. The wall of the blood-cyst is about 2 mm. thick; its diameter is about 3 cm. It is attached to the Fallopian tube along the free border of the tube away from the broad ligament, and quite close to the ostium.

Microscopical sections have been made across the largest diameter of the blood-cyst, including the part of the Fallopian tube adherent to it and passing through the ostium. In order to preserve the naked-eye anatomical relations the greater part of this piece was cut in one block about one and a quarter inches in diameter, and special precautions were taken to ensure uniplanar sections by embedding the slice on a curved surface corresponding to the curve described by the rocking arm of the microtome used. Although nearly the whole circumference of the blood sac was examined, neither epithelial lining nor endothelial covering was found. No trace of ovarian tissue was seen.

The wall of the blood sac is made up entirely of fibrous tissue; no muscle could be detected in it anywhere even with the assistance of van Giesson's special stain. Mr. Shattock, after carefully examining my specimens, agrees that muscle is entirely absent from the sac wall. The peripheral fifth of its thickness is made up of rather loose fibrous tissue, infiltrated with round-cells, but also containing between its bundles fair numbers of spindle-shaped fibroblasts. This layer also contains numerous small dark granules of altered blood. A close examination suggests that many of these are lying within the phagocytic cells.

The middle two fifths of the thickness of the cyst wall is its oldest portion, and shows hyaline scantily-nucleated fibrous tissue, with a few round-cells in it and an occasional fibroblast.

The inner two fifths of the wall is the most recent layer, and shows most externally young fibrous tissue with round-celled infiltration, most internally a layer of old blood-clot with round-celled infiltration of the clot. There are many large round cells filled with altered blood granules throughout this layer.

These appearances point to a centripetal organisation of fibrous tissue at the expense of the blood-clot, while at the same time the deposition of lymph upon the sac by the surrounding peritoneum is slowly increasing its thickness from without.

German authorities state that the outermost layer of the wall of encysted hæmatoceles is the oldest. In this case, as in one I examined last year, the old layer of the wall is covered externally by a thin layer of comparatively young tissue, and this I believe to be the general rule. In my opinion the organisation of the sac of an encysted hæmatocele does not proceed entirely from without inward, as is generally stated. Though it is true in the main that the organisation of the wall is a centripetal process extending into the mass of blood-clot, yet at the same time a slower centrifugal process of organisation is adding externally to the thickness of the fibrous sac.

Opposite the place of rupture of the tube the wall of the blood sac is much thinner than elsewhere, and consists entirely of young fibrous tissue containing microscopical masses of altered blood. This is evidently *the most recent portion* of the wall of the blood sac.

The rent in the tube wall as it appears in the microscopical sections is 5 mm. wide. Its edges are clearly visible to the naked eye.

With the microscope it is seen that the epithelium of the tube has disappeared on either side of the rupture for some little distance. Further away from the rupture the epithelial layer is quite normal.

The edges of the rupture are thickly infiltrated with round-cells. In some of the sections the edges have become slightly separated from the young tissue filling up

the rent; in others they are continuous with it. The appearances clearly show that the rupture was not an accidental one made during the operation.

The wall of the tube near the rupture is very vascular, and some of the arteries have decidedly thickened walls. In the immediate neighbourhood of the rupture the wall of the tube is decidedly thinned, and the muscular layers of the tube cannot be clearly demonstrated; either they have undergone fibrous degeneration, or, as is more probable, they have been partially absorbed by chorionic villi which have subsequently disappeared. Distinct remnants of the muscle of the tube close to the rupture can, however, be demonstrated by van Giesson's stain as yellowish areas contrasting with the surrounding red-stained fibrous tissue. On the side of the tube away from the rupture the two layers of tubal muscle can be clearly seen.

Turning now to the question what was the original cause of the hæmorrhage, no fœtal structures could be demonstrated either in the tube, the blood sac, or the clot. Dr. Cullingworth was, however, strongly of the opinion that the case was one of tubal gestation. The co-existence of a rupture in the tube with a patulous ostium and a patent lumen cannot be explained, so far as I am aware, by any known condition except tubal pregnancy.

The growing ovum no doubt ruptured the tube and produced the hæmatocele by slow bleeding. The lumen, previously too narrow at the point of rupture to allow the ovum to pass towards the ostium, now offered no obstacle, and tubal abortion occurred. The ovum escaped into the peritoneal cavity and was doubtless absorbed. It is, of course, just possible that the ovum escaped through the rupture in the tube into the cavity of the hæmatocele; but the small size of the rupture, and the absence of fœtal products in the blood-clot of the hæmatocele, make this improbable. Besides, such a supposition fails to explain the dilated ostium.

The co-existence of tubal rupture with complete tubal

abortion is a well-recognised occurrence. Mr. Bland-Sutton appears to have been the first to describe this combination of events. In 1892 he reported to the Medical Society of London a case in which a mole was found lying among the fimbriæ of the tube. There was a small rent in the tube wall. The position of the ovum and, as in the present case, the small size of the rupture quite negatived the suggestion that the ovum had escaped through the rent in the tube.

It appears to me, then, that the evidence of tubal pregnancy rupture and complete tubal abortion in Dr. Cullingworth's case is as strong as it can be without being conclusive. Complete tubal abortion satisfactorily explains the entire absence of fœtal products from the specimen, the patulous ostium, and the dilated tube.

The question now arises whether the wall of the blood sac represents either in whole or in part the wall of the tube. That it is not simply an altered and distended portion of the tube which has become shut off from the rest of the tube is certain, for the mucous membrane and muscle of the tube, only interrupted by the rupture, can be traced right along the dividing wall between the blood sac and the tubal lumen. The edges of the rupture are sharply defined from, and do not pass into the structure of the wall of the hæmatocele, and the tube is patent through its whole extent without any spur or structure to indicate a kink. No trace of muscular layers, nor even the smallest isolated bit of muscular tissue, can be found in the wall of the hæmatocele.

Does, however, any part of the tubal wall—say, for instance, only the peritoneal layer—cover the blood sac? In other words, was the first hæmorrhage an intra-mural one within the thickness of the tubal wall, and has it simply distended its original intra-mural cavity until it burst into the lumen of the tube? Dr. Cullingworth, in his paper on hæmatocele already quoted, has described a case of intra-mural hæmorrhage from a ruptured vein in the wall of the Fallopian tube.

In the present case, however, the peritoneum can be traced as a continuous layer from the tube wall for only about 2 mm. on the wall of the blood sac. It then definitely leaves off, and is replaced by a microscopically rough surface of fibrous tissue. The hæmatocele, then, is an intra-peritoneal structure lying naked in the peritoneal cavity without any endothelial covering. No layer of the Fallopian tube can be traced into the wall of the hæmatocele in the angle where the two structures join. It follows of necessity from these facts that the wall of the tube can have taken no share whatever in the formation of the wall of the hæmatocele.

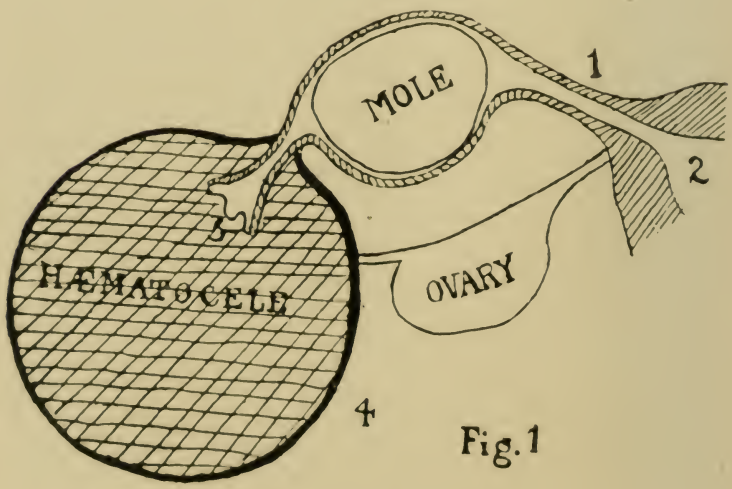

Fig. 1.—Diagram of a Typical Peritubal Hæmatocele.

1. Fallopian tube. 2. Cavity of uterus. 3. Abdominal ostium. 4. Sac of hæmatocele. (Figs. 1 and 5 show the typical varieties; Figs. 2, 3, 4, the intermediate forms.)

This conclusion is borne out by the exact similarity of structure between the wall of the hæmatocele in this case and the wall of the ordinary peritubal hæmatocele. In the latter form of hæmatocele the wall of the tube can by no possibility take any share in forming the hæmatocele

wall, since the hæmatocele can be pulled apart from the tube, leaving the latter intact.

Turning now to the cases reported in medical literature, series of links can be traced, connecting typical peritubal hæmatocele with the typical paratubal hæmatocele just described.

In peritubal hæmatocele the tube generally contains a mole, and the sac of the hæmatocele clasps the open ostium whence the bleeding proceeded (see Fig. 1).

Mandl and Schmit describe a case in which the mole-containing tube had ruptured, and an encysted hæmatocele enclosed within its cavity both the patent ostium and

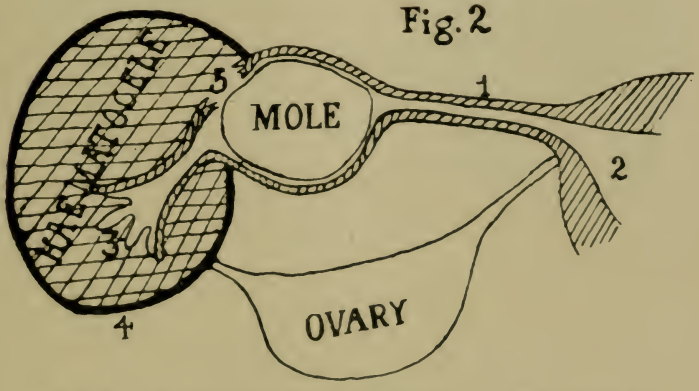

Fig. 2.—An Unusual Form of Peritubal Hæmatocele.

Rupture of the tube has occurred, and the sac includes within itself both the rupture and the patent ostium. 1. Fallopian tube. 2. Cavity of uterus. 3. Abdominal ostium. 4. Sac of hæmatocele. 5. Rupture in wall of tube.

the rupture (Fig. 2). In this case, as they suggest, the blood in all probability came partly from the ostium, partly from the rupture. These two streams of blood united to form a single hæmatocele.

This is, then, a peritubal hæmatocele of an unusual variety, representing in its mode of origin a combination of para- and peritubal hæmatocele.

The next case to which I would direct your attention

is on the border-line between para- and peritubal hæmatocele. It is also described by Mandl and Schmit. The mole-containing tube had ruptured, and round the rupture an encysted hæmatocele had formed. The portion of tube intervening between the mole and the occluded ostium was enclosed within the thickness of the sac wall of the hæmatocele. The case may evidently be classified either as peritubal or paratubal (Fig. 3).

The third case described by Mandl and Schmit is a

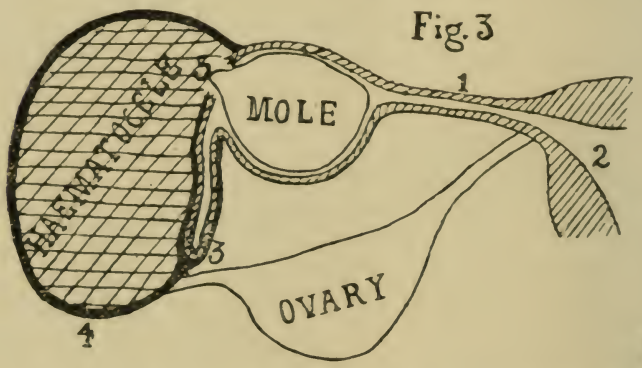

FIG. 3.—HÆMATOCELE WHICH MAY BE CLASSED EITHER AS PERI- OR PARATUBAL.

The bleeding has occurred from a rupture in the tube wall. The portion of tube intervening between the rupture and the closed ostium is included in the thickness of the sac wall of the hæmatocele. 1. Fallopian tube. 2. Cavity of uterus. 3. Closed ostium. 4. Sac of hæmatocele. 5. Rupture in wall of tube.

true paratubal hæmatocele, the only one so far as I can find which has been hitherto described, though no doubt the collective experience of this Society will be able to furnish further examples of the condition.

In this case a mole-containing tube with occluded ostium had ruptured on its posterior surface. Round the rupture an encysted hæmatocele had formed, into whose cavity a portion of the mole projected. The Fallopian tube could be seen adherent to the anterior wall of the hæmatocele, which bore on its surface the closed ostium

(Fig. 4). Here the hæmatocele did not surround any portion of the tube. To describe it as a peritubal hæmatocele would therefore be entirely misleading; it is para- and not peritubal.

Last in the series comes Dr. Cullingworth's case which I have described to-night. In it the mole has escaped through the open ostium, and the hæmatocele is seen

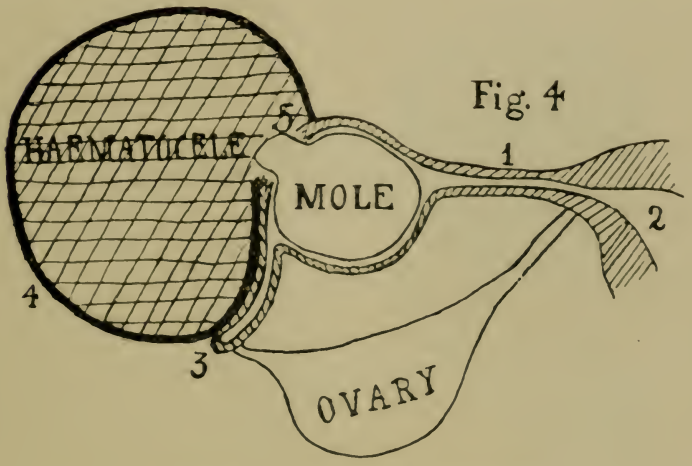

FIG. 4.—PARATUBAL HÆMATOCELE.

The sac does not surround any portion of the tube. Bleeding has occurred from a rupture. The portion of tube intervening between the rupture and the closed ostium lies *on the surface* of the sac of the hæmatocele. 1. Fallopian tube. 2. Cavity of uterus. 3. Closed ostium. 4. Sac of hæmatocele. 5. Rupture in wall of tube.

lying alongside the tube and adherent to it (Fig. 5), but not surrounding it.

This specimen is of particular interest because it shows that the rupture of the gravid tube, with the formation of a paratubal hæmatocele round the rupture, and with tubal abortion, is not necessarily inconsistent with the future functional activity of the tube. In peritubal hæmatocele, on the contrary, the tube is probably per-

manently occluded by a fibrous cap over the ostium even after the contained blood has been absorbed.

Although the natural course of events in the case under consideration was as favourable as it could possibly be, yet the symptoms of colicky pain and uterine hæmorrhage were none the less persistent, and laparotomy became necessary. The inference appears to be that all cases of tubal gestation in which these symptoms persist

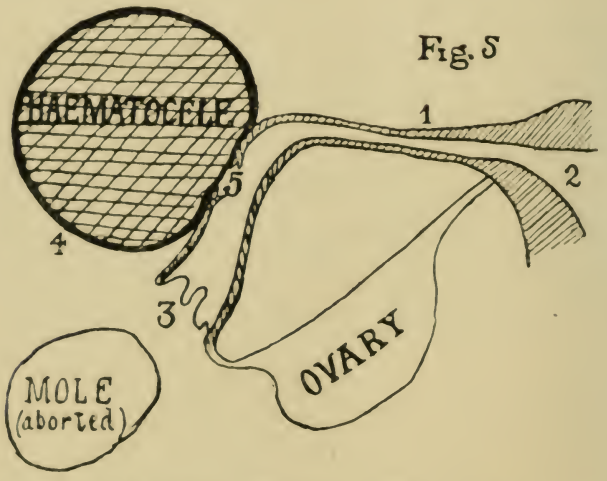

FIG. 5.—TYPICAL PARATUBAL HÆMATOCELE.

The sac does not surround any portion of the tube. Bleeding has occurred from a rupture. The ostium being patent, the mole has aborted, leaving the lumen of the tube free. The rupture has subsequently healed. 1. Fallopian tube. 2. Cavity of uterus. 3. Ostium. 4. Sac of hæmatocele. 5. Rupture in tube-wall (healed).

for more than a few days should be treated by surgical means, especially bearing in mind the risk of rupture of the hæmatocele.

Had it been desirable for any reason to preserve the tube in this case with a view to future pregnancies, it would have been as easy as in peritubal hæmatocele to dissect the hæmatocele from the tube, leaving the latter *in situ*.

Into the dynamics, as opposed to the anatomy of encysted hæmatoceles with independent sacs, I do not propose to enter in detail. The prevailing opinion is that the bleeding is entirely antecedent to the formation of the sac wall. The laminated structure of the clot in this case tends to show rather that the two processes were in the present case concurrent. The first escaping central portion of the clot apparently became encysted by the peritoneum and then shrank away from its cyst wall, allowing a peripheral zone of fresh hæmorrhage to occur between it and the cyst wall. This fresh hæmorrhage distended and enlarged the newly formed cyst wall. The recently escaped blood in its turn clotted and contracted, allowing still further bleeding to occur into the peripheral part of the sac, which distended the latter still more.

It seems to me that only by repetitions of this process is it possible to account for the lamination of the clot, and the fact that its centre is the hardest and oldest portion. The small central pear-shaped portion of clot in all probability represents the primary hæmorrhage which preceded encystment.

The occurrence of aneurysmoid distension by blood-pressure of the sac of encysted hæmatoceles is conclusively shown by the not uncommon event of their rupture. In some cases no doubt the primary bleeding is a large one, the blood-clot within the hæmatocele is soft and non-laminated, and adjacent structures, *e. g.* the ovary, may be included within the cavity of the hæmatocele instead of being pushed aside by its gradual distension as usually happens. But however small or large the original bleeding in cases of peri- and paratubal hæmatoceles, it appears to me that in all such cases more or less aneurysmal distension takes place subsequent to the first encystment, for otherwise it is impossible to explain the separation of the soft layer of plastic lymph round the mass of blood from the peritoneal surfaces which throw it out in response to the irritative contact of the effused

blood. As the layer of soft lymph or young fibrous tissue is stretched by the blood within it, some amount of separation must necessarily be brought about between the lymph and the adjoining visceral surfaces from which it was originally thrown out. Further distension is continually changing the relation of each point on the surface of the blood sac to the surrounding viscera, and this constant change of relation is the determining factor in breaking down adhesions, in preventing the formation of fresh ones, and in smoothing and polishing the surface of the hæmatocele. It is, in fact, this which gives the hæmatocele its "tumour-like" individuality. Where, on the contrary, the hæmorrhage is rapid at first, ceasing before a coherent layer of lymph has been thrown out around it, there is no force, except the feeble one of the intestinal movements, tending to separate the lymph from the peritoneal surfaces by which it has been thrown out, and the blood will simply be walled in by adherent viscera, and will possess no fibrous sac of its own. Such hæmatoceles are by definition excluded from peri- and paratubal hæmatoceles, whose chief character is the possession of a non-visceral fibrous sac.

I have used the hybrid word "paratubal" in the heading of my paper so as to follow the existing nomenclature as closely as possible.

Since, however, the most essential feature of both peri- and paratubal hæmatoceles, namely, the possession of a proper sac apart from the viscera, is a direct consequence of the hæmodynamic pressure within them, it would be better and simpler to include both varieties under the name of "hæmodynamocele."* The sacs containing pus or watery fluid occasionally found in similar relation to the Fallopian tube might be called pyo- and hydrodynamoceles. Where the context indicated the nature of the contents the short word "dynamocele" would be sufficiently descriptive.

I cannot conclude without expressing my thanks to

* Handley, 'Trans. Obstet. Soc.,' 1901, p. 258.

Mr. Shattock for his advice and assistance in the histological examination of the specimen, to Dr. Cullingworth for the kind interest he has taken in my work, and to my friend Mr. J. S. Eland for help with the illustrations.

I may add that Dr. Cullingworth has, in the main, accepted my conclusions, and has in the forthcoming edition of his work revised his description of the specimen in accordance with them.

Abstract of Quoted Cases.

Mandl and Schmit, 'Archiv für Gyn.,' vol. lvi, p. 456 (see Fig. 2).

Primipara, aged 32, complains for six weeks of somewhat severe, almost continuous bleeding, associated with strong colicky pains which have somewhat subsided lately. A year previously supposed inflammation of the womb. No period of amenorrhœa.

There was right incomplete tubal abortion with rupture and hæmatocele round the tear. The left annexa swollen and intimately adherent to the back of the uterus. Recovery after operation.

In the specimen obtained, the right tube, after a course of 5 cm., suddenly expands to a swelling the size of an apple, covered on its surface with coagulated black-brown blood. On its hinder wall the ovary is strongly adherent near the uterine part of the tube. The tumour consists, as a section shows, in its median part of a tubal gestation sac about the size of an egg which contains a firmly adherent blood mole. The rest of the tumour is formed by a hæmatocele sac which joins the outer side of the gestation sac, and communicates with it so as to make a single cavity. The hæmatocele, which is filled with old coagulated blood, surrounds the tube completely in its further course, so that the fimbriated end comes to lie within the cavity of the hæmatocele. In the median part

of the cavity (the part lined by tubal mucosa, which is bounded from the remaining part, that formed from the hæmatocele, by an irregular but definite line) one finds close to the rupture a round opening—the lumen of the tube,—which, narrowing again after forming the tubal gestation sac, runs inwards and backwards within the sac of the hæmatocele to the ostium.

Mandl and Schmit, 'Archiv für Gyn.,' vol. lvi, p. 466 (see Fig. 3).

Patient aged 35, admitted October 28th, 1893. Since the end of September, at the time of the expected period, bleeding of moderate amount, continuing to the present time. It was accompanied by pains in the left lower abdomen, with smarting during micturition. Since the beginning of the illness frequent vomiting and fever; leucorrhœa. Three children, the youngest eleven years old. Last period end of August. There was left incomplete tubal abortion with a hæmatocele round the place of rupture. The hæmatocele lay in front of the uterus. The right appendages were thickened and matted. Operation October 31st. Recovery.

Description of specimen.—A bluish tumour the size of two fists lying in the utero-vesical fossa with its front touching the bladder, its base touching the anterior surface and fundus of the uterus, while its upper part projects free into the general peritoneal cavity. The tumour consists of a sac about the size of an apple with rather firm walls. It encloses most of the Fallopian tube, so that the latter is only visible for the first 4 cm. of its course from the uterus. At this point it widens out into a cavity the size of a nut, which contains old coagulated blood and a portion of a hæmorrhagic ovum the size of a walnut. The greater part of the ovum projects through an opening on the anterior wall of the tubal sac, of irregular shape, and about the size of a kreutzer, into the sac of the hæmatocele, which also

contains much old coagulated blood. No embryo was found. The further portion of the tube runs outwards in the wall of the hæmatocele, and then turns suddenly round so that the completely closed ostium comes to lie on the ovary, to which it is bound by soft adhesions.

MANDL AND SCHMIT, 'Archiv für Gyn.,' vol. lvi, p. 480 (see Fig. 4).

A. G—, aged 29, three children, abortion two years ago, admitted October 7th, 1896.

Severe spasmodic pains ushered in bleeding, which has lasted two months. The pains continue. Subjective symptoms of pregnancy. Last period six months ago.

There was left incomplete tubal abortion, an old rupture of the tube, and a hæmatocele round the rupture. Right appendages normal. Operation October 9th. Recovery.

Description of specimen.—The tube, normal in size for 5 cm. from its uterine end, then suddenly enlarges to the size of a hen's egg, and is found to contain a mole with amniotic cavity. The tube again narrows, and runs with a diameter of 2 cm. to the closed ostium. To the posterior surface of this tubal tumour a firm-walled blood sac the size of a fist is firmly adherent. The hæmatocele thus bears on its surface the closed fimbriated end. After opening of the sac, which contained much fluid and coagulated blood, it is found that about the middle of the tube is an opening about 1 cm. long, with irregular, torn, and blood-infiltrated edges. Through it parts of the mole project into the hæmatocele. Ovary of normal size, somewhat flattened by pressure, closely connected with the lower wall of the hæmatocele, but completely separable from it by dissection.

Dr. EDEN said that on reading Mr. Sampson Handley's paper a few days ago he had been reminded by it of a specimen which had been in his possession for nearly a year, and which bore some resemblance to the condition described as paratubal hæma-

tocele. He now showed the specimen to the Society, but regretted that he was unable to give any clinical notes of the case at the present time; on a future occasion he would furnish a full report to the Society. The specimen consisted of a Fallopian tube with a large oval mass of blood-clot firmly attached to the upper surface at about its middle. The abdominal ostium was occluded; a rather large cystic ovary was adherent to the outer part of the tube. The mass of blood-clot had the general characters of a tubal mole, and this view of it he was prepared to maintain, although he had failed to find chorionic villi in it. The part of the tube wall to which the clot was adherent was thinned, and on section appeared to be infiltrated with blood. The view he had originally taken of the specimen was that it was an instance of tubal rupture, that the tubal mole had been extruded through the rupture, and had remained attached to the tube, while the rupture had afterwards healed beneath it, thus restoring the wall of the tube and cutting off the mole from its lumen. On first reading Mr. Sampson Handley's paper it had occurred to him that possibly his (Dr. Eden's) specimen was not a tubal mole but a paratubal hæmatocele. After listening to the demonstration of his case which the author had laid before the Society that evening, he was, however, disposed to retain his earlier view of his own specimen. He thought that Dr. Sampson Handley had clearly shown that a hæmatocele may be formed around the site of a tubal rupture in the same way as we have long known that it may be formed around the patent abdominal ostium. This was the real lesson of his paper. Dr. Eden was inclined to think that the specimen which Dr. Bell had shown to the Society was perhaps a better example of a paratubal hæmatocele than that described by Mr. Sampson Handley. He was not sure that the reasons advanced by the author for regarding the case as primarily one of tubal abortion were conclusive, but even if the ovum had really been extruded through the rupture, and not through the abdominal ostium, this did not invalidate the general purpose of the paper. In conclusion he desired to congratulate Mr. Sampson Handley on having brought forward a very careful and thorough piece of scientific work.

Dr. Cullingworth said that Mr. Handley had produced a valuable and thoroughly scientific paper, a paper of a kind that the Society ought always to welcome. As Mr. Handley had told them, he (the speaker) had all along regarded the specimen upon which the paper was based as a difficult one to understand and explain. The committee that investigated and reported upon it at the time consisted of Mr. Bland-Sutton, Dr. W. Duncan, Mr. A. Doran, and himself, and had the advantage of the advice and help of Mr. Shattock. The committee spent much time in the inquiry, and ended by simply describing what they saw without expressing any opinion as to its origin and development.

As Mr. Handley had told them, he (the speaker) had adopted Mr. Handley's explanation in the new edition of his little book. He was glad to find that Mr. Handley himself was dissatisfied with such hybrid words as peri- and paratubal. He felt personally indebted to Mr. Handley for having taken so much pains in the investigation of a case of his, and one in which he had always felt a special interest. He concluded by once more congratulating Mr. Handley on having made an important contribution to our knowledge.

Mr. Bland-Sutton was instructed and greatly interested in the paper, because these encysted collections of blood in relation to tubal pregnancy had been the subject of careful study with him since Sänger and Taylor had published their observations. The main object of the paper was to demonstrate that "encystment" of the blood slowly effused after rupture of the tube could take place as well as in cases of "incomplete tubal abortion." The fact that in some of the cases the reporters had failed to find the "mole" was capable of explanation, because the mole in some specimens was very small; he had exhibited to the Society a "tubal mole" which did not exceed the dimensions of a green pea. In some of the specimens it was easy to realise that such a body could easily escape detection in the course of an operation, or might even be buried in the clot of the "encysted hæmatocele." It was also important to bear in mind that the extraordinary capsules which surrounded the effused blood in cases of "incomplete tubal abortion" did not require blood for their formation; similar capsules formed around the products effused from the cœlomic ostium of the tube in acute salpingitis. The most typical example of this which had come under his own notice occurred in connection with acute salpingitis probably of gonorrhœal origin. The specimen is described and figured in the 'British Medical Journal,' 1896, vol. ii, p. 1310, as a cyst of unusual characters surrounding the ostium of the Fallopian tube, but he had come to appreciate its nature after a further study of the capsules surrounding blood effused in cases of incomplete tubal abortion. The research conducted by the reader of the paper not only shed much valuable light on the remarkable specimen obtained by Dr. Cullingworth, and which had been such a puzzle to the committee appointed to examine and report upon it, but it would alter the complexion of many similar specimens when they came to be interpreted in the newer light furnished by this excellent investigation.

Dr. Griffith agreed with the general opinion expressed as to the value of Mr. Handley's paper, but he thought that it was undesirable to adopt different names for the two varieties of the hæmatocele described, as they appeared to be essentially identical, though one was produced by leakage from the open tubal orifice, the other from a rupture in the wall of the tube. It seemed,

therefore, necessary to devise a name for this class of hæmatocele to distinguish it from the common larger hæmatocele which is enclosed by adhesions of the various organs displaced by the effusions of blood. The terms peri- and para-, if they were to have any definite significance, should be confined to their original uses, peri- signifying intra-peritoneal, para- extra-peritoneal effusions of blood-serum or pus.

The PRESIDENT said the terms "peritubal" and "paratubal" hæmatocele did not convey to one's mind the kind of hæmatocele meant by the coiners of these words. He agreed with Dr. Griffith that paratubal gave one the idea of something in the cellular tissue of the broad ligament near to the tube, which was not what the author meant. Nevertheless apart from this question of nomenclature there could be no doubt as to the meaning Mr. Handley wished to convey, and so far as this particular kind of hæmatocele went he had practically proved his point. One of the most interesting problems raised was the dynamics of its production, and he could not help feeling that in all probability the hæmorrhage through the ruptured tube was, in these cases of so-called paratubal hæmatocele, not only small in amount and slow in speed, but also that the reason the blood did not flow freely into the peritoneal cavity was because the peritoneum was the last to rupture, and that before doing so the blood effused beneath it had time to clot and to form a fibrinous capsule. In the peritubal variety there was probably some lymph round about the abdominal ostium of the tube, which took the place of, and acted like, the peritoneum in the paratubal hæmatocele.

Mr. HANDLEY, after thanking the Society for the kind reception given to his paper, said that the opinions expressed on Dr. Cullingworth's specimen were formed during a visit to the St. Thomas's Museum in the autumn of 1901. His re-examination of the specimen was complete by the end of the year, and the sections were shown to Mr. Shattock on January 17th, 1902, and to others about the same time. He mentioned these facts because in the 'British Gynæcological Journal' for February, 1902, Mr. J. W. Taylor independently made an identical though tentative suggestion as to the nature of the specimen. He wished to point out that before Mr. Taylor's suggestion was published the same idea had occurred to him, and had been proved, as he thought, correct. He owed his knowledge of Mr. Taylor's reference to the specimen to a letter he had received from Mr. Taylor only that morning (November 5th), and in which he was much interested. His thanks were due to Dr. Bell, Dr. Eden, and Dr. Dauber for showing specimens apparently similar to the one described. He thought Dr. Eden's criticism had been sufficiently met by Dr. Cullingworth. He was much gratified by Mr. Bland-Sutton's acceptance of his explanation of the specimen, and very interested in his case where a

sac containing clear fluid was found round the end of the Fallopian tube. He had tried to find such a case in the English literature, but hitherto without success. Mr. Bland-Sutton suggested that similar sacs might be formed in other situations. The same idea had occurred to him, and he hoped some day to describe a case of a "dynamocele" containing pus, surrounding a leak in the appendix vermiformis. It appeared to him that cases described as floating appendical abscess might be of this nature. He quite shared Dr. Cullingworth's and Dr. Griffith's objection to the terms peri- and paratubal, and it seemed to him that questions of nomenclature should be dealt with and settled officially by the Society. If a single name could be found to cover both varieties he agreed with Dr. Griffith that it would be better. As regards the President's suggestion that the hæmorrhage might be at first subperitoneal, he quite saw the possibility of this. It could not, however, take place in the peritubal variety of hæmatocele, so that he could not think it a *necessary* event in producing paratubal hæmatocele. In conclusion he would like to suggest that some of the cases described as fibroids of the Fallopian tube might be found to be old and fibroid paratubal hæmatoceles.

DECEMBER 3RD, 1902.

PETER HORROCKS, M.D., President, in the Chair.

Present—53 Fellows and 1 visitor.

Books were presented by the Clinical Society, Dr. Nagel, Dr. Heywood-Smith, and the Section on Gynæcology of the College of Physicians of Philadelphia.

Edward Marten Payne, M.B., C.M.; H. V. McMahon-Dillon, R.A.M.C.; and Alfred Walter Sikes, M.D., B.Sc.Lond., were admitted Fellows of the Society.

John Inglis, M.D. (Hastings); Theodore H. Ionides, M.B., B.S. (Brighton); and William H. Breffit Brook, M.D. (Lincoln) were declared admitted.

The following candidates were proposed for election:—Alexander Duke, F.R.C.P.I., L.R.C.S.I.; Frederick Edge, M.D.Lond., F.R.C.S.Eng.; G. F. Vincent, F.R.C.S.Edin.; Arthur Lionel Hall Smith, L.R.C.P., M.R.C.S.; William Ernest Heilbron, M.B., B.Ch.Cantab.; John Harold Philbrick, M.B., B.Ch.Cantab.; Louisa Brandreth Aldrich-Blake, M.D., M.S.Lond.

The following candidate was elected a Fellow:—Temulfi Bhicafi Nariman, L.M. and F. Bombay Univ. (Bombay).

A DERMOID CYST CONTAINING A LARGE NUMBER OF EPITHELIAL BALLS.

By W. F. Victor Bonney, M.S., M.D.Lond., F.R.C.S.

This specimen I removed by abdominal section from a woman aged 49, a patient in the Chelsea Hospital for Women. She had noticed a swelling of the abdomen for one year, and had had two attacks of acute pain with vomiting, one six months and the other six weeks before the operation.

On opening the abdomen I found a large cyst taking the place of the left ovary. It was universally adherent but separated easily, and I then found that the pedicle was twisted through a circle. I removed it whole, and the patient made a good recovery.

When I opened it after the operation about two quarts of a brownish grumous fluid gushed out, containing a great quantity of balls. I was only able, unfortunately, to preserve the few which I now exhibit, but the actual number in the cyst when I opened it I estimated at over 4000. They consisted of an extremely friable material, which, once broken up, it was impossible to re-form into the spherical masses here shown. Mixed with them, and in many cases incorporated with them, were brownish hairs, and besides these there were large flakes of desquamated epithelium. On section they appear to have a concentric structure, and to be made up of cells similar to those found in sebaceous glands, and in so advanced a state of fatty change that it is only here and there that the cellular origin of the mass can be made out. All those that I cut contained hairs. The cyst wall was bald, and the epithelium was macerated and desquamating. It contained a quantity of yellow pigment.

A section of the cyst wall showed a well-marked epithelial layer consisting of closely packed squamous cells, and the rete mucosum is well defined. Beneath this the structure is fibrous with many vessels, and in places there are cells which simulate ill-formed unstriped muscle.

The fluid in which the balls floated was serous, and about the same specific gravity as the balls themselves.

Dermoids containing these epithelial balls are very rare. I have been able to collect only seven recorded cases besides my own. The recorded cases are by Walters, Alexander, Rolleston, Astley Cooper, Butler-Smythe, Rokitansky, and Routh.

Of these the first four are referred to in Mr. Bland-Sutton's book on 'Tumours,' and the last two I am indebted for reference to Mr. Alban Doran.*

I have endeavoured to investigate these cases with the following results.

1. *Dr. Rolleston's case.*†—This was a lingual dermoid. The patient had noticed a swelling for one year.

Dr. Rolleston very kindly supplied me with portions of the cyst wall and some of the balls.

The cyst wall shows an extremely well-marked epithelial layer with a prominent rete mucosum. The cyst wall, though chiefly destitute of hairs, contains a few follicles and sebaceous glands. Muscle tissue is plentiful in the wall.

The balls are identical in structure with my own specimen.

2. *Sir Astley Cooper's case.*‡—This was a dermoid of the scalp. It is figured and described in Mr. Bland-Sutton's book.

Mr. Shattock was good enough to open the specimen,

* 'Clinical and Pathological Observations on Tumours of the Ovary, etc.,' 1884, p. 80.

† "Round Pellets of Sebaceous Material from a Dermoid Cyst," 'Trans. Path. Soc.,' vol. xlix, 1898, p. 292.

‡ "Encysted Tumours," 'Surgical Essays,' vol. ii, 213, 1818.

which is in St. Thomas's Hospital Museum, and give me pieces of the cyst wall and some of the balls.

The cyst wall is bald, and shows on section a thin epithelial layer with an ill-marked rete mucosum. No glands or hair-follicles are seen.

The balls, which are firmer and more obviously fatty than those of my specimen, are, however, also composed of fatty epithelial cells and fatty cell débris. I did not find hairs in the one I examined, but it is possible that I overlooked them if they existed.

3. *Mr. Butler-Smythe's case.**—For sections of this specimen I am still further indebted to Mr. Shattock, who opened it at my request, it being in the museum of the College of Surgeons.

This cyst was also bald, and was ovarian in origin. The cyst wall shows a poorly marked epithelial layer devoid of glands or hair-follicles. In the deeper layers are cells resembling unstriped muscle.

The balls are identical in section with those of my own specimen.

Mr. Butler-Smythe tells me that the cyst was large, and had its pedicle twisted in two distinct places and in opposite directions. This was made possible by an intestinal adhesion which had "fixed" the lower twist.

The cyst was extremely tense, and contained a great number of balls floating in a grumous brown-coloured fluid. There was hair in every ball examined.

4. *Dr. Alexander's case.*†—This was an ovarian dermoid, and is figured in Dr. Alexander's book on 'Practical Gynæcology.'

In answer to a letter of mine Dr. Alexander, whilst regretting that the specimen was too injured to obtain sections from, was good enough to describe it in the following words:—

"The cyst wall was bald; the fluid was dark brown

* "Dermoid Cyst containing Pill-like Bodies," 'Trans. Obstet. Soc.,' vol. xxxvii, 1895, p. 15; "Consecutive Ovariotomies," vol. xlvii, 1897, 104.

† 'Practical Gynæcology,' 1899, p. 103.

in colour, and the round bodies looked very like peas. There were no sebaceous glands found in the cyst wall, but it contained some muscular tissue. The balls were fatty. They were not examined for hairs."

5. *Dr. Walter's case.**—This was an ovarian dermoid. There is a picture of it in Mr. Bland-Sutton's book on 'Tumours.' I have been unable up to now to obtain specimens of this cyst, but Dr. Walter has kindly promised to let me have them shortly. Mr. Bland-Sutton, who originally investigated it, tells me that it was similar to my own specimen.

6. *Rokitansky's case.*†—This, an ovarian dermoid described by him in his 'Lehrbuch der Pathologie' in the early part of the last century, was also described by Sir Spencer Wells in his book on 'Ovarian Tumours' in the following words:—"The cyst was the size of a large bead, and was twice rotated on its pedicle; it was also adherent. It contained a quantity of brownish viscid fluid, and a large number of balls varying in size from walnuts to peas, and made up of fat in concentric layers.

7. *Dr. C. H. F. Routh's case.*‡—This, which is also quoted by Sir Spencer Wells, was apparently a similar tumour. The balls were concentric masses of amorphous fat around nuclei of cholesterin. There was loose hair in the cyst.

Comparing, then, these cases with my own, I am struck with the great similarity which is manifest between them. Thus one sees that the balls appear to have been identical structures in them all. In a large proportion the same grumous, non-sebaceous fluid is described in which they floated.

In the cases of which I have obtained sections of the cyst wall there is the same paucity of hair-follicles, hair,

* Bland-Sutton, 'Tumours, Innocent and Malignant,' 1901, p. 424; Rokitansky, 'Lehrbuch der Pathologie,' vol. iii, 1842.

† Spencer Wells, 'Ovarian and Uterine Tumours,' 1882, p. 39.

‡ Ibid.

and sebaceous glands, and the same remark applies to Dr. Alexander's case. Muscle tissue was present in the walls of many of them also.

In seeking an explanation for the formation of these balls several points have been suggested. Thus Rokitansky attributed them to the churning movement of axial rotation. Olshausen thought that they were due to blood effusion into the sebaceous contents. Mr. Alban Doran suggested that there might be some chemical peculiarity in the fat of which they are composed. Mr. Bland-Sutton pointed out the presence of hair in them, and believed that this acted as a nucleus, around which the sebaceous material cohered.

I think, however, that, as Olshausen appears to have in part suggested, the essential for their formation is the presence within the cyst of a serous fluid, in which the sebaceous material is insoluble. I would further suggest that the fact of an equal specific gravity of balls and fluid would, by allowing of their freer movement, aid their formation. In all probability at some period in the life history of these cysts there has been, owing to axial rotation or inflammation, a sudden effusion of serous fluid into the sebaceous mass. The continual movements of the body have then effected the breaking up of this mass into a number of spherical pieces.

I would further point out that the degenerative atrophy which has apparently overtaken the epithelial portion of the cyst wall, leading to the disappearance of the sebaceous glands and the falling of the hair, would possibly render more easy a serous effusion from the wall, whereas it is less likely that serous fluid would effuse from a surface covered by an epithelial lining approximating to normal skin.

I may add that experimentally I agitated soft wax in several non-solvent media, such as alcohol, gum, and water, and found that I could produce similar balls by these means. But I found that when the specific gravity of the fluid and the balls was about equal, one was able

to produce them by very gentle agitation, whereas when the wax floated in thick gum it required violent shaking to produce the same result.

The suggestion that in these cases the agitation of the cyst contents is produced by axial rotation appears to me to be untenable. Such movement must be far too slight and brief to do this. Much more reasonable is it to suppose that the continual daily shaking to which the cyst is subjected is the operative agent. I have no doubt that the presence of hairs, loose in the cyst contents, materially aids the process.

Dr. Heywood Smith, when mountaineering in the high Alps, had observed when he carried warm tea in a padded bottle where milk had been added, that, owing to the churning to which it had been subjected all day, the cream had separated into small balls about the size of pills when the tea was poured out.

Mr. Butler-Smythe congratulated Dr. Bonney on having made such an extensive investigation of the spherical masses which had been taken from his specimen. His theory of the fluid pressure was very ingenious, but could hardly be accepted without further evidence. He (Mr. Butler-Smythe) was inclined to favour the theory of axial rotation, and it was a curious fact that in most of the cases cited there was twisting of the pedicle. In the case which he had brought before the Society in 1895 there existed two distinct rotations, separated by an intestinal adhesion, which showed that the whole length of the pedicle had twisted, and then the portion above the adhesion had unwound itself, and later on rotated in the opposite direction. In that particular instance there was evidence of much axial rotation.

Dr. Herbert Spencer suggested that possibly the fluid in the cyst was plasma, and that the presence of blood caused it to coagulate, and so favoured the agglutination of the epithelial cells. He asked if all the tumours were as large as the one shown. He had seen only one case with balls similar in appearance to those in Dr. Bonney's specimen out of a large number of dermoids. Unfortunately a microscopic examination was not made.

Dr. Bonney, replying, said that he was interested to hear from Dr. Spencer that Sir John Williams had operated on such a case. Most of the cysts had been of good size. He thought Mr. Malcolm's experience with his box of boric acid supported his theory in some part. Replying to Mr. Butler-Smythe, he said that axial rotation could not be the cause of the churning of the

sebaceous mass, since two of the recorded cases were dermoids of the tongue and scalp respectively. He himself considered that the daily movements of the body were the operative factor.

A SPECIMEN OF FIBROMA OF THE OVARY.

By Arthur E. Giles, M.D., B.Sc., F.R.C.S.

This specimen was removed from a woman aged 30, who had been married six months. For five months she had noticed an abdominal swelling, and had suffered from hæmorrhage, pelvic pain, frequency of micturition, and obstinate constipation. On examination the uterus was found involved in a mass of multiple myomatous growths, which filled the pelvis and rose into the abdomen. At the operation the right ovary was found to be the seat of a solid tumour the size of a small egg, and it was therefore removed with the uterus. The left ovary was healthy, and was not removed.

The specimen presents several points of interest. In the first place, it is associated with uterine fibro-myomata. This association, though not unknown, is uncommon, and was not present in any of the cases reported by Dr. Fairbairn in his paper on "Fibroma of the Ovary," read before this Society in May this year.

In the second place, the tumour is small enough to illustrate in a satisfactory manner the mode of growth of ovarian fibromata, as demonstrated by Dr. Fairbairn. A complete capsule of ovarian tissue is found surrounding the growth, and from the preponderance of ovarian tissue at the outer extremity it appears that the fibroma arose at the inner pole of the ovary close to the ovarian ligament. In the recent state a cyst the size of a large grape was present on the outer portion of the ovary; it

contained a sero-sanguineous fluid. Microscopically the growth shows the structure of a fibro-myoma.

There is no evidence in this case that the fibroma was developed in association with a corpus luteum, although the probability of such an origin has been demonstrated in some of the specimens that have been recorded. Here it appears to have arisen in connection with the ovarian stroma.

The patient made a satisfactory recovery.

The PRESIDENT said it would be well to refer the specimen to the Pathological Committee, because at present there did not appear to be any definite information which would enable one to say whether a tumour such as this was a simple fibroma or a sarcoma. He had shown one at the Society years ago, and some pronounced it a typical sarcoma and others a typical fibroma. He was told to watch the case, and if she died, then it must have been a sarcoma; and if she did not, then it was a fibroma. But if possible it was desirable to distinguish between the two microscopically.

Dr. BRIGGS said that in his paper on "Ovarian Fibroma," published in 1897, he described the association of uterine fibroids with pure fibroma of the ovary met with over ten years before. The contrast in structure was convincing, and he figured the ovarian growths, a nest of three small tumours with the ovary, as supporting Rokitansky's belief that they originated in the cicatrix of a corpus luteum.

Report on Dr. Giles' Specimen of Fibroma of Ovary.

The specimen consists of the body of the uterus enlarged to the size of a fœtal head by multiple fibromyomata in its walls. On the right side the tube, mesosalpinx, ovarian and round ligaments are normal. The ovary has been laid open, and is smaller than it was in the fresh state owing to the rupture of cysts; it measures now 2 × 1½ × 1 inches. In it has developed a very firm, rounded, new growth, measuring 1½ inches in diameter, with a sharp outline and distinctly encapsuled. The growth can be readily enucleated. It approaches the free surface at one point, but is everywhere covered

by ovarian tissue. On microscopic examination the growth proves to be a fibro-myoma.

Corrie Keep.
Arthur E. Giles.
Herbert R. Spencer.
John S. Fairbairn.
G. Bellingham Smith.
Cuthbert Lockyer.
Alban Doran, *Chairman.*

PYOSALPINX WITH TWISTED PEDICLE.

Shown by Arthur H. N. Lewers, M.D.

As regards the pyosalpinx with twisted pedicle, the patient from whom it was removed was a single woman, aged thirty-seven. Dr. Lewers saw her for the first time on October 1st, 1902. She said that in December, 1901, she had taken a "chill," and was laid up for a fortnight with severe pain in the lower abdomen, especially severe on the right side, and vomiting. She then got better, but had had a similar attack in May, 1902, when she was ill for a week. She was, however, away from her work nine weeks, and since that attack she had never been entirely free from pain in the lower abdomen. She had another attack of illness in September, 1902, similar to that from which she had suffered on the two previous occasion in December and May. Menstruation had always been normal.

The patient was undoubtedly a virgin. There were physical signs suggesting the presence of an ovarian tumour on each side; that on the right side, the larger, seemed about the size of a large orange. The diagnosis made was double ovarian tumour, and that probably, judging from the history, one had a twisted pedicle.

Dr. Lewers operated on October 9th, 1902, at the London Hospital. It was found that the tumour to the right was a large pyosalpinx, firmly adherent above to small intestine and omentum, and in front slightly adherent to the bladder. A very interesting feature was that the dilated part of the tube, when freed from its adhesions to the parts mentioned above, was found to be attached to the broad ligament by a pedicle twisted several times, which consisted of the undilated inner part of the Fallopian tube. The right ovary was not involved, and seemed quite healthy, and it was accordingly not removed. The tumour on the left side was also a pyosalpinx, not so large as that on the right side; it was slightly adherent, but its pedicle was not twisted. On the left side, also, it was possible to remove the pyosalpinx without taking the ovary, which appeared quite healthy. On both sides the tumours were removed without escape of the contents. Some of the pus and a portion of the wall of the pyosalpinx were sent to Dr. Bulloch for bacteriological examination. He could not find the tubercle bacillus. He found some bacilli in the pus, but was unable to say what they were.

Dr. Lewers brought the specimen before the Society as he had never seen an example of pyosalpinx with twisted pedicle, nor had he seen any case where, though there was double pyosalpinx, the ovaries were quite normal, and as entirely apart from the pyosalpinx on each side as it was possible to have them.

As to the cause of the pyosalpinx, he thought sepsis and gonorrhœa were fairly excluded by the fact that the patient was a virgin. Though no positive evidence of tubercle was found, he thought that most probably the salpingitis was tubercular. The patient made an uninterrupted recovery.

FIBROID OF THE BROAD LIGAMENT, WEIGHING FOUR AND A HALF POUNDS, WITH TWISTED PEDICLE.

Shown by Arthur H. N. Lewers, M.D.

The fibroid was removed in the London Hospital on February 23rd, 1900, from a patient fifty-one years old. The menopause had occurred four years previously. In September, 1899, she had had violent pains in the abdomen, with retching, vomiting, and severe diarrhœa. She was then ill for a fortnight. She had a similar illness in December, 1899. After that she was fairly well till she came under observation on February 19th, 1900. A large solid tumour was then felt occupying the greater part of the abdomen, and reaching on the right side to within a short distance of the ribs. It had some mobility from side to side. The sound passed the normal distance with a direction forwards. There was a hard, irregular, fixed mass felt in Douglas's pouch.

It seemed clinically to be probably a case of subperitoneal uterine fibroid, which for some reason (possibly degeneration of the tumour) had set up peritonitis, of which there was a very clear history.

At the operation, on exposing the tumour it was found to be adherent everywhere, and especially to intestine and omentum. The adhesions, however, were easily dealt with. The tumour had the yellowish leathery appearance so often seen in ovarian tumours when the pedicle has become twisted. When the adhesions had been separated, the pedicle, which consisted of the right broad ligament, was seen to be several times twisted, and to be about as thick as the wrist. The pedicle was tied in the usual way, and the tumour removed. During the operation it seemed most likely that the case was one of solid tumour of the right ovary with twisted pedicle.

Subsequently more careful examination of the pedicle led to the discovery of the right ovary, quite normal, in the part of the pedicle which was removed with the tumour. It then became evident that the tumour was a solid one, growing from the broad ligament, and not an ovarian. Microscopically the structure of the tumour was that of an ordinary fibro-myoma. The patient made a good recovery.

He might mention that he had removed a sarcoma of the ovary from a sister of this patient.

Dr. Lewers said he had referred to Mr. Doran's valuable paper* on cases of fibro-myoma of the broad ligament. In that paper thirty-nine cases of this condition were analysed. It was there stated that in eleven, or possibly twelve cases the tumour was pedunculated, but in only one case was the pedicle said to have been twisted. Large fibroids of the broad ligament were rare, and evidently twisting of the pedicle in such tumours was very rare. On that account Dr. Lewers had thought it desirable to exhibit his specimen. The tumour weighed four pounds and a half.

Mr. Alban Doran remarked that though fibroids of the broad ligament were usually sessile they were occasionally pedunculated. Since he read his communication on the subject before a meeting of the Society in 1899 he had inspected a valuable specimen in the museum of the Royal College of Surgeons showing a minute pedunculated fibroid springing from a short pedicle, attached to the mesosalpinx a little above the ovarian ligament. In the Harveian Lectures which he had recently delivered he turned attention to this specimen, comparing it with another in the same collection, where a minute fibro-myoma lay in the middle of the ovarian ligament independent of uterus, ovary, and broad ligament. The minuteness of the two tumours allowed their origin to be plainly demonstrable. When large the distinction might be difficult, and he suspected that Dr. Lewers' tumour might have arisen from the ovarian ligament. The fact of a pedicle being present in a case of broad ligament tumour suggested the possibility that amputation of the growth alone might be effected through the pedicle, so as to save the ovary and tube. In Dr. Lewers' tumour the pedicle was too short and

* 'Trans. Obstet. Soc. Lond.,' vol. xli, p. 174.

broad to allow of transfixion, but this might not always be the case. A similar surgical consideration applied to fibroids of the ovarian ligament. In Mr. Doran's own case, the first ever recorded, the tumour was of great size and the pedicle short and thick, so he thought it safer to sacrifice the appendages, but it should be remembered that Doléris succeeded in saving the ovary and tube when he removed a fairly large fibroid of the ovarian ligament.

SARCOMA OF THE BODY OF THE UTERUS WITH COMPLETE INVERSION.

By Walter C. Swayne, M.D.

F. B—, nullipara aged 17, was admitted into the Bristol Royal Infirmary on December 18th, 1895, complaining of a watery discharge from the vagina and some flooding.

Her first period occurred at the age of sixteen, and she was quite regular until June, 1895, when she noticed increased loss, followed by watery discharge, which became constant. Since that date she also complained a good deal of pain in the back.

On admission it was found that a fleshy mass, apparently resembling in consistence and colour the maternal surface of the placenta, was just visible at the vaginal outlet.

On December 19th, under anæsthesia, a fuller examination was made. It was found that the mass consisted of the inverted uterus, the surface of which was covered with a soft fleshy growth, while a large fistula opened into the bladder through the anterior wall of the vagina. The fistula was practically closed by the tumour.

The growth was removed with curette scissors and the vagina packed with iodoform gauze. The patient im-

proved a good deal after this, but on February 11th, 1896, the growth had recurred, and the tumour reached its original size. The removal by curette, etc., was repeated with temporary improvement, but the patient died, apparently of wasting, in March, 1896. (From notes by Mr. C. C. Pratt.)

This specimen consists of the vagina, bladder, inverted uterus, and part of the rectum. The uterus is seen to be completely inverted, its body being replaced by the growth. Into the neck of the inversion the Fallopian tube is seen to enter, while an ovary lies to one side of the orifice of the inversion. In the anterior vaginal wall is seen a large fistula opening into the bladder. There is apparently some thickening of the vaginal wall and floor of bladder above the fistula.

The growth was shown to be a mixed-cell sarcoma.

Dr. Herbert Spencer was not sure that the growth was not a fibroid. He had seen similar cases. The microscopical characters of fibroids often closely resembled those of sarcoma. It was curious, in view of the great malignancy of sarcoma of the uterus, that no secondary growths existed. He asked if an explanation could be given of the presence of the vesico-vaginal fistula.

Report on Dr. Swayne's Specimen of Sarcoma of the Body of the Uterus with Complete Inversion.

We, the undersigned, have examined this specimen, and are of opinion that it consists of the greater part of the bladder, portion of the rectum, and the inverted uterus and the vagina. The base of the bladder, from the level of the anterior vaginal fornix to just above the internal orifice of the urethra, has entirely disappeared, owing to pressure, there being no evidence of new growth in the bladder wall on microscopical examination.

Attached to the inverted fundus of the uterus, and in part replacing it, is a tumour measuring 8 × 10 cm.

The tumour is irregularly heart-shaped, with a lobulated surface, presenting the appearance of superficial necrosis. The cut surface of the tumour presents a somewhat fibrous appearance and evidence of hæmorrhage into its substance. The stalk of the tumour is seen to be formed by the body of the uterus, which passed imperceptibly into the substance of the growth.

The anterior lip of the cervix can be recognised below the level of the utero-vesical pouch of the peritoneum, and is present as far down as the vaginal fornix. The posterior lip of the cervix passes directly into the vaginal wall without any line of demarcation between the two.

The cavity containing the tumour appears to consist of two distinct portions, the upper of which presents a smooth, the lower a rugose sloughy appearance; we are of opinion that the upper smooth part represents the dilated cervical canal, and the lower rugose portion the vagina, and that the inversion is therefore incomplete.

The right ovary and tube are present, and apparently healthy. The ovarian ligament and uterine end of the Fallopian tube have been drawn down into the cup of the inversion, and have been cut across obliquely in dividing the specimen. The sections show a tissue composed in the main of large spindle-cells, with a number of round-cells of varying size. There are strands of muscle-fibre, which appear to be portions of uterine tissue involved by the growth. There are small areas of myxomatous change, and there is evidence of necrotic processes throughout the sections. We regard it as a fibro-sarcoma undergoing myxomatous change.

Herbert Spencer.
G. F. Blacker.
J. S. Fairbairn.
G. Bellingham Smith.
Cuthbert Lockyer.
Corrie Keep.
Walter C. Swayne.
Alban Doran, *Chairman*.

CYSTIC FIBROID OF UTERUS.

By Walter C. Swayne, M.D.

The specimen was from a multipara aged 53, and shows uterus with cervix complete. The uterine cavity is opened on its anterior aspect. One large cyst, which projected into the uterine cavity, is opened through the left wall of the uterus. In the outer wall of the cyst, which is thin and membranous, is seen an opening into a second cyst, from which about twenty-five ounces of straw-coloured fluid were evacuated. A much smaller cyst lies between this and the peritoneal surface from which it has been opened.

A microscopic section of a portion of the outer wall of the cyst nearest to the uterine cavity shows fibrous and muscular tissue. In places can be seen patches of commencing myxomatous degeneration.

(Specimen removed by pan-hysterectomy on November 15th.)

ICTERUS NEONATORUM.

By A. W. Sikes, M.D.

Microscopical slides were shown illustrating a case of jaundice in a child a few days old, which was found to be caused by a streptococcus.

The mother of the child had been admitted into Queen Charlotte's Hospital for her confinement, and was at the time suffering from a severe cold and sore throat. The child, a couple of days after birth, contracted the cold.

On the sixth day jaundice appeared, which terminated fatally two days later.

At the post-mortem, very shortly after death, cultivation taken from the liver, and incubated, showed pure growths of *Streptococcus pyogenes*.

Sections made from the liver and spleen showed marked deposit of an iron-containing compound, both in the cells and between them.

A CONTRIBUTION TO THE NATURAL HISTORY OF DYSMENORRHŒA.

By G. Ernest Herman, M.B.Lond., F.R.C.P., F.R.C.S.,

SENIOR OBSTETRIC PHYSICIAN TO THE LONDON HOSPITAL; PAST PRESIDENT OF THE SOCIETY;

AND

H. Russell Andrews, M.D., B.S., M.R.C.P.,

OBSTETRIC TUTOR, LATE OBSTETRIC REGISTRAR, TO THE LONDON HOSPITAL AND MEDICAL COLLEGE.

(Received June 9th, 1902.)

(*Abstract.*)

The authors compare a number of cases of dysmenorrhœa cured by dilatation of the cervix with a number of others in which dilatation of the cervix produced no benefit. They find no reason to think that dysmenorrhœa curable by dilatation is frequently associated with imperfect development of the uterus.

They find that dysmenorrhœa curable by dilatation begins with the establishment of menstruation in about two thirds of the cases, and is acquired later in about one third; that it almost always begins before the age of twenty-five, but may be acquired at any age.

They find that the result of treatment is not materially affected by the length of time the dysmenorrhœa has lasted, the age of the patient when treated, or the duration of her married life.

They find that in most cases cured by dilatation the time of commencement of pain is very near the time of commencement

of the flow, while in most of the cases not cured by dilatation the pain begins two days or more before the flow. In half of those cured by dilatation the pain is over in less than two days; in more than half of those not cured by dilatation the pain lasts more than four days. In four fifths of those cured by dilatation the pain is paroxysmal; in three fourths of those not cured by dilatation it is constant. In most of the cases cured by dilatation the pain is not relieved by lying down.

The authors give details showing the severity of the pain. They find that only a few patients were known to pass membranes, and that in only a few were there physical signs of disease. They find no evidence of such narrowing of the cervical canal as to mechanically hinder the flow of blood through it. They think it possible that some degree of smallness and rigidity of the canal may hinder the physiological dilatation of the canal which should take place during menstruation, and so provoke painful contractions of the uterine body; but they are unable to adduce evidence of this.

They give tables showing the known duration of cure in the cases on which the paper is based, and the number of cases in which pregnancy followed dilatation in married women who were previously sterile.

Some cases of menstrual pain are cured by dilatation of the cervix, others are not. It is plain that the former cases have at least one feature in common. The latter may be of the most diverse kind.

The present contribution differs from that of Sir J. Williams, with a somewhat similar title, published in vol. xxiv of the 'Obstetrical Society's Transactions,' in that he appears to have based his paper upon cases comprising menstrual pain of every kind; what we have to say applies chiefly to menstrual pain curable by dilatation of the cervix.

In the present paper we purpose to analyse some cases taken from the records of the London Hospital and from the private practice of one of the authors. We wish to express our thanks to Dr. Lewers for permission to use the notes of some of his cases. The only selection that

has been made is that only those cases have been taken of which the after history is known. In the large majority of these cases, if not in all, medicinal treatment had been tried first and had been unsuccessful.

The reports of cases on which this paper is based have not been made specially for it. They were made in the ordinary routine of practice, without any ulterior purpose. Hence they were not always so complete as we could wish, but they were made without any preconceived bias.

Although this disease is a common one, and the method of treatment is not novel, yet works have even recently appeared, by authors of high reputation, professing to give accounts of the diseases of women complete enough for the needs of the student and practitioner, but without any mention of this disease or its treatment. We may refer to the works of Baldy, Skene, Garrigues, Gebhardt, and Runge.

In the writings of authors who mention that dysmenorrhœa is sometimes cured by dilatation we find theoretical statements as to its causation; but we find no author who has analysed his experience to find out the frequency of such cases, the duration of the cure, or the characters in which such cases differ from cases of monthly pain not curable by dilatation.

One theoretical statement repeated by many writers, among whom we may mention Gusserow, Giles, More Madden, Schröder, Hart and Barbour, and Pozzi, is that dysmenorrhœa is due to anteflexion. A paper was published in 1881, in the 'Transactions' of this Society, by one of the authors of the present communication, in which it was shown that anteflexion was present with precisely the same frequency in women who menstruate without pain as in those who menstruate with pain; and that in women with anteflexion no greater proportion menstruate with pain than among those whose uteri are straight. In the same year Vedeler, of Christiania, published an investigation made independently, which led him to the same conclusion. No one since has brought

forward any evidence to controvert these statements, nor even attempted to do so.

Some who speak of anteflexion as a cause of dysmenorrhœa do so with the qualifying adjective of "pathological" anteflexion. Schultze has described how pelvic peritonitis or pelvic cellulitis may produce anteflexion. Without discussing how far the effects of pelvic peritonitis and cellulitis are modified by any change produced in the shape of the uterus, we may point out that among the class of patients who come to be treated for dysmenorrhœa, pelvic peritonitis and cellulitis are excessively rare. With the exception of Schultze we know of no writer who has shown in what way the "pathological anteflexion" which causes dysmenorrhœa differs from anteflexion which is not pathological.

One of the conclusions reached by Sir J. Williams is that the uterus is imperfectly developed; but he found that menstruation in his cases began at about the same age as in the average of women in London. We give the details of our cases which bear on this point.

Menstruation commenced at the following ages in seventy-one patients with dysmenorrhœa cured by dilatation.

The first column shows the number beginning at each age, the second column the calculated proportion per thousand, the third the numbers commencing at the different ages in 1000 women tabulated by Dr. Giles.

Age.	I.	II.	III.
11	2	28	37
12	4	56	85
13	14	197	188
14	19	267	211
15	13	183	173
16	10	140	151
17	5	70	76
18	1	14	28
19	2	28	18
20	1	14	6

In further considering our cases we shall compare those which were cured by dilatation with those in which dilatation was done, but the pain was not removed.

Sir J. Williams, in 873 cases, found only 11 of acquired menstrual pain. Our experience is different. Of 67 cases cured by dilatation, in 43 the pain dated from the beginning of menstruation, in 24 it was acquired later, *i. e.* roughly in about one third.

Of 36 where dilatation was done without benefit, in 18 it was primary, in 18 acquired.

It seems, therefore, that primary dysmenorrhœa is more likely to be cured by dilatation than that which is acquired.

Putting the figures in another way, we have—

Primary 61	Unsuccessful married	7	**18,** or 30 per cent.	
	„ single .	11		
	Successful married .	24	**43,** or 70 per cent.	
	„ single .	19		
Acquired 42	Unsuccessful married	11	**18,** or 43 per cent.	
	„ single .	7		
	Successful married .	11	**24,** or 57 per cent.	
	„ single .	13		

The following are the ages at which the menstrual pain began in the cases which were cured by dilatation:

Age 11 in 1 case.	Age 20 in 5 cases.
„ 12 „ 3 cases.	„ 21 „ 5 „
„ 13 „ 8 „	„ 22 „ 3 „
„ 14 „ 10 „	„ 23 „ 3 „
„ 15 „ 7 „	„ 24 „ 2 „
„ 16 „ 6 „	„ 26 „ 1 case.
„ 17 „ 6 „	„ 28 „ 2 cases.
„ 18 „ 4 „	„ 31 „ 1 case.
„ 19 „ 1 case.	„ 37 „ 1 „

It will be seen that all but 5 began to have pain before the age of twenty-five.

The interval between the first menstruation and the beginning of pain was—

2 years in	1 case.	8 years in	3 cases.
3 „	1 „	9 „	3 „
4 „	5 cases.	10 „	1 case.
5 „	2 „	12 „	1 „
6 „	5 „	13 „	3 cases.
7 „	2 „	18 „	1 case.

This shows that dysmenorrhœa may be acquired at almost any time in the first half of menstrual life.

Patients with dysmenorrhœa do not generally seek treatment very quickly, for they are of the class of patient in whom feelings of delicacy are most powerfully operative.

The following tables show that the result of treatment is not materially affected by the length of time the dysmenorrhœa has lasted, the age of the patient when treated, or the duration of married life.

Duration of dysmenorrhœa before treatment.

	Less than 1 year.	1—2 years.	2—3 years.	3—4 years.	4—5 years.	5—6 years.	More than 6 years.
Successful cases **72**	**1**, or 1 per cent.	**4**, or 6 per cent.	**2**, or 3 per cent.	**4**, or 6 per cent.	**4**, or 6 per cent.	**3**, or 4 per cent.	**54**, or 74 per cent.
Unsuccessful cases **37**	0	**2**, or 5 per cent.	**3**, or 8 per cent.	**2**, or 5 per cent.	**3**, or 8 per cent.	**4**, or 11 per cent.	**23**, or 62 per cent.

Age of patients when treated.

	18—20.	21—25.	26—30.	31—35.	36—40.	41—46.
Successful cases **77**	**6**, or 8 per cent.	**27**, or 35 per cent.	**27**, or 35 per cent.	**13**, or 17 per cent.	**4**, or 5 per cent.	0
Unsuccessful cases **41**	**5**, or 12 per cent.	**15**, or 37 per cent.	**13**, or 32 per cent.	**4**, or 10 per cent.	**3**, or 7 per cent.	**1**, or 2 per cent.

Duration of married life before treatment.

	Under 1 year.	1—2 years.	2—3 years.	3—4 years.	4—5 years.	Over 5 years.
Successful cases **42**	**5**, or 12 per cent.	**10**, or 24 per cent.	**6**, or 14 per cent.	**4**, or 9 per cent.	**3**, or 7 per cent.	**14**, or 34 per cent.
Unsuccessful cases **21**	**1**, or 5 per cent.	0	**5**, or 24 per cent.	**3**, or 14 per cent.	**3**, or 14 per cent.	**9**, or 43 per cent.

We think that the diagnosis of spasmodic dysmenorrhœa, *i. e.* of the kind of menstrual pain that is cured by dilatation, can only be made by the characters of the pain. We shall examine our cases from this point of view.

The pain felt with menstruation may be of two kinds: a general aching due to the congestion of the pelvic organs which precedes menstruation, which is relieved by the bleeding from the uterus, and the sharp spasms of uterine colic. The former is not affected by dilatation of the cervix, the latter is often cured by it.

The clinical difference between the aching of pelvic congestion and the spasm of uterine colic is that the former precedes menstruation, often by several days, while the spasmodic pain usually begins either with the flow, or within a very short time of its appearance.

Onset of pain.

	With flow, or a few hours before or after beginning of flow.	1 day before beginning of flow.	2 days before beginning of flow.	More than 2 days before beginning of flow.
Successful cases **73**	**42**, or 58 per cent.	**9**, or 12 per cent.	**11**, or 15 per cent.	**11**, or 15 per cent.
Unsuccessful cases **41**	**12**, or 30 per cent.	**5**, or 12 per cent.	**7**, or 17 per cent.	**17**, or 41 per cent.

The preceding table shows that in three fifths of the cases cured by dilatation the time at which the pain began

was very close to that at which the flow began. In most of those which were not affected by dilatation the pain began two days or more before the flow.

The pain of pelvic congestion not only begins earlier but lasts longer than the pain of uterine spasm. In the following table it will be seen that of those not cured by dilatation, in more than half the pain lasted more than four days, and in only a fifth was it limited to two days. Of those cured by dilatation, in just upon half the pain lasted less than two days.

Duration of pain.

	Less than 1 day.	1—2 days.	2—3 days.	3—4 days.	More than 4 days.
Successful cases 68	**15**, or 22 per cent.	**18**, or 27 per cent.	**10**, or 14 per cent.	**8**, or 12 per cent.	**17**, or 25 per cent.
Unsuccessful cases 38	**4**, or 10 per cent.	**4**, or 10 per cent.	**5**, or 13 per cent.	**5**, or 13 per cent.	**20**, or 54 per cent.

The pain of pelvic congestion is constant, that of uterine spasm intermittent.

The following table shows that in the cases cured by dilatation the pain was of the paroxysmal kind in four fifths, while amongst those not cured by dilatation it was constant in three fourths. In some cases both kinds of pain were present. In one fifth of the cases cured by dilatation the pain was said to be constant. Two explanations may be given of this. One is that the pain was due to tonic spasm of the uterus. The other is that the record was incorrect, either because the patient misunderstood what she was asked or misdescribed her pain, or because the reporter misunderstood the patient's answers to questions.

Character of pain.

Successful cases **67.**		Unsuccessful cases **35.**
41, or 61 per cent. .	Paroxysmal	. **9**, or 26 per cent.
15, or 22 per cent. .	Constant	. **18**, or 52 per cent.
	Constant with exacerbations	. **3**, or 8 per cent.
11, or 17 per cent.	Constant and paroxysmal	**5**, or 14 per cent.

Another difference between the pain which is relieved by dilatation and that which is not is in the effect of position. When the spasmodic pain is very bad the patients say that they cannot lie still; if they do lie down they roll about with the pain. The pain of pelvic congestion is relieved by quiet recumbency. But a patient with very severe pain may prefer to lie down even if her pain is not thereby lessened. Hence whether the patient finds herself better while lying down or not depends much upon her idiosyncrasy.

The following table shows that in most of the cases cured by dilatation lying down did not relieve the pain.

Effect of position.

Successful cases **53.**		Unsuccessful cases **24.**
43 per cent., or **23** .	Relieved by lying down	. **12**, or 50 per cent.
57 per cent., or **30** .	Not „	„ . „ „

The pain of spasmodic dysmenorrhœa is very severe. It is generally accompanied by nausea, and in about one fourth of the cases by vomiting. There may be other manifestations of suffering which are detailed in the table which follows. Some of these, such as headache, prostration, feeling of heat and cold, and faintness, are to be attributed to the general disturbance—raised vascular tension and lowered nervous tone—which precedes the full establishment of menstruation, rather than to pain. Symptoms directly due to increased afflux of blood—aching in the breasts and pain on micturition—in our collection of cases occurred only in the cases not cured by dilatation. In thirteen of the cases not cured by dilatation the pain was so bad as to produce vomiting,

and in one to "double up" the patient. These we take to be genuine but incurable cases of spasmodic dysmenorrhœa.

Effects of pain.

Successful cases.		Unsuccessful.
15	Vomiting	13
6	Nausea without vomiting	4
2	"Doubled up"	1
4	Sweating	1
2	Fainting	1
5	Faint feeling	2
10	Laid up	8
8	Rolling about	3
2	Diarrhœa	2
3	Headache	2
2	Prostration	—
1	Vertigo	—
1	"Comes over hot"	—
1	Feels cold	—
—	Pain in breasts	2
—	Painful and difficult micturition	1
—	Loses use of limbs	1

In many of the cases no special effect of the pain is noted.

Those who have searched carefully for membranes in cases of dysmenorrhœa have found them to be passed very frequently. In our cases special search was not made as a rule, for whether a patient who menstruates with pain passes membranes or not is only important theoretically; the treatment is the same, whether membranes are passed or not.

Passage of membrane is noted in seven cases:

1 successful, married.
1 unsuccessful, married.
3 successful, single.
2 unsuccessful, single.
(1 doubtful.)

In most cases of dysmenorrhœa there is no sign of organic disease of the uterus. Those who have tried to find a physical basis for dysmenorrhœa have been, as is

known, reduced to describing, as the cause of the dysmenorrhœa, peculiarities in the shape of the uterus or of the cervix which are found also in women who menstruate without pain.

We find physical signs noted in five cases only. In one, a single woman, treated with success, there was an erosion of the cervix; in two single women, unsuccessfully treated, there was in one an imperfectly developed uterus, and in the other a small fibroid; in two married women, treated with success, there was smallness of the vaginal orifice causing dyspareunia, and in one of them retroflexion.

The most obvious explanation of the cure of menstrual pain by dilatation of the cervical canal is that the pain is caused by narrowness of the canal. The cervical canal of a young nulliparous woman has never been seen narrow enough to mechanically hinder the passage of the few ounces of blood that are lost at each menstrual period. Such stenosis exists only in diagrams. But during menstruation the body of the uterus contracts and the cervix dilates. The former is believed to take place because it is observed in pregnancy, labour, and in uteri enlarged by fibroids to a degree which makes it possible to observe the fact of contraction. The latter has been shown to occur in a paper published in vol. xxxvi of our 'Transactions.'

But the cervix, if not narrow enough to mechanically hinder the outflow of blood, may yet be small and rigid, and not dilate as it should during menstruation; and it is possible that such deficient dilatation or dilatability may be the cause of the painful spasms.

We give some measurements, made in the way described in the paper referred to, of the size of the os internum and os externum of some nulliparæ, and of the os internum of some parous women who had pain with menstruation. To compare with these we give some measurements, made in the same way, of patients who menstruated without pain. They are few, because

	Painful.			Painless.		
	Nulliparous.		Parous.	Nulliparous.		Parous.
	External os.	Internal os.	Internal os.	External os.	Internal os.	Internal os.
Less than No. 3	—	4, or 12 per cent.	1, or 3 per cent.	1, or 17 per cent.	—	—
No. 3	1, or 3 per cent.	—	—	—	—	—
No. 4	1, or 3 per cent.	5, or 16 per cent.	2, or 5 per cent.	—	—	—
No. 5	3, or 8 per cent.	7, or 22 per cent.	5, or 13 per cent.	—	—	8, or 12 per cent.
No. 6	5, or 14 per cent.	5, or 16 per cent.	12, or 31 per cent.	—	3, or 50 per cent.	13, or 19 per cent.
No. 7	3, or 8 per cent.	6, or 19 per cent.	3, or 8 per cent.	—	1, or 17 per cent.	6, or 9 per cent.
No. 8	2, or 5 per cent.	2, or 6 per cent.	—	1, or 17 per cent.	2, or 33 per cent.	9, or 13 per cent.
No. 9	5, or 14 per cent.	1, or 3 per cent.	2, or 5 per cent.	—	—	4, or 6 per cent.
No. 10	3, or 8 per cent.	2, or 6 per cent.	6, or 15 per cent.	—	—	5, or 7 per cent.
No. 11	8, or 22 per cent.	—	3, or 8 per cent.	—	—	4, or 6 per cent.
No. 12	6, or 16 per cent.	—	5, or 15 per cent.	4, or 68 per cent.	—	18, or 27 per cent.
	37 cases	32 cases	39 cases	6 cases.	6 cases	67 cases.

nulliparæ who menstruate without pain, and are free from local disease, seldom present themselves for examination.

It will be seen that while there is no great difference in the size of the canal in the two sets of cases, yet cervical canals admitting only a small bougie are more frequent among the cases with painful menstruation. We have notes that the canal offered unusual resistance to dilatation in fourteen cases. Of these nine were married, and dilatation removed the dysmenorrhœa in five; five were single, and dilatation was successful in four.

Without claiming to have substantiated the statement, we are yet of opinion that undue smallness and rigidity of the cervical canal is sometimes a condition underlying, and perhaps causing, spasmodic dysmenorrhœa, acting not by causing mechanical obstruction, but by preventing physiological dilatation.

The treatment of these patients consisted in the dilatation of the cervical canal by bougies.

The following table (p. 384) shows the known duration of cure.

A second dilatation was done in 9 cases.

2 married, unsuccessful.
1 single, „
2 „ successful.
4 married, „

In one single woman a fourth dilatation proved most successful.

Duration of cure; single women.

Under 1 year.	1–2 years.	2–3 years.	3–4 years.	4–5 years.	5–6 years.
(6) 1 month +	(2) 1 year	(1) 2 years	(3) 3 years +	(1) 4 years +	(1) 5½ years +
(1) 2′ months	(1) 1 year +	(1) 2½ years	(1) 3½ years	—	(1) 5½′ years +
(1) 3 months +	(2) 16 months +	—	—	—	—
(1) 3′ months	(1) 20 months +	—	—	—	—
(2) 4 months +	(1) 22 months	—	—	—	—
(1) 5′ months	—	—	—	—	—
(1) 5 months	—	—	—	—	—
(2) 5 months +	—	—	—	—	—
(1) 6 months	—	—	—	—	—
(2) 6 months +	—	—	—	—	—
(1) 7 months +	—	—	—	—	—
(1) 9 months + (pain not entirely gone)	—	—	—	—	—
(2) 10 months +	—	—	—	—	—
(1) 11 months +	—	—	—	—	—

The 2′, 3′, and 5′ months and 5½′ years + all refer to the same case, *i.e.* this patient was dilated four times, relief following the last dilatation lasting 5½ years +.

\+ After a number means that the pain had not returned when the patient was last heard of.

None of the cases of "1 month +" were in hospital during the first menstrual period after dilatation.

Duration of cure; married women.

Under 1 year.	1—2 years.	2—3 years.	3—4 years.	4—5 years.
(1) 2 months +	(1) 1 year +	(3) 2 years +	(1) 3½ years +	(1) 4 years +
(1) 2 months (then partial return)	(1) 16 months +	—	(1) 3½ years + (pain not quite gone)	(1) 4½ years +
(2) 3 months +	(1) 17 months +	—	—	—
(1) 3 months	(1) 18 months +	—	—	—
(3) 4 months +	(1) 21 months +	—	—	—
(1) 4 months	(2) 22 months +	—	(1) 6 years +	—
(2) 5 months +	—	—	(1) 19 years + ("pain trifling")	—
(1) 6 months +	—	—	(1) 22 years +	—
(1) 7 months	—	—	(8) Pregnant when last heard of; no pain till then	—
(1) 8 months + (pain not quite gone)	—	—	—	—
(1) 9 months (then partial return)	—	—	—	—
(1) 10 months +	—	—	—	—
(1) 11 months +	—	—	—	—
(1) "Some months" (then returned)	—	—	—	—

Cases in which dilatation was repeated.

Name.	Age at first menstruation.	Age at which menstrual pain began.	Age at marriage.	Age at which treated.	Time of onset of pain.	Duration of pain.	Constant.	Paroxysmal.	Effect of position.	Vomiting.	Other effects of pain.	Effect of other treatment.	Period of sterile marriage.	—
F. A.	11	17	17	21	With flow	1—3 days	Yes	—	Not relieved by lying down	Yes	Cannot sleep; loses use of limbs	Somewhat relieved by leeches	4 years	Dilatation very difficult; no relief.
				21	...	...	...	...	...	...	...	...	...	No relief.
A. J.	13	26	25	32	With flow	3 days	Yes	Yes	Not relieved by lying down	Feels sick	—	No relief from castoreum, exalgin, phenacetin, antipyrin, or ichthyol	7 years	No relief.
				33	...	...	...	...	...	...	...	...	8 years	,,
L. S.	9	9	Single	22	Just before flow	3—24 hours	Yes	—	—	Yes	Laid up	Somewhat relieved by cannabis indica	Single	,,
				27	...	...	...	...	...	...	...	...	...	,,
F. B.	14	18	,,	23	With flow	24 hours	—	Yes	—	...	Laid up; vertigo	—	Single	Relief for 1 year.
				24	...	...	...	...	...	...	...	...	...	Relief for 1 yr. 8 mos. +

		until 31		36	...	...	...	...	...	...	...	...	Relief for 3 months.
				37	...	...	...	...	...	...	...	...	Relief for 2 months.
				37	...	...	...	...	...	...	...	...	Relief for 5¼ years +
XVI	14	Slight before 21	22	28	A week before flow	10—11 days	—	—	Relieved by lying down	—	—	—	6 years	No relief.
				28	...	...	...	...	...	...	...	...	„	Pregnancy followed in 14 months, during which time pain was relieved, though not cured.
M. L.	15	15	22	23	With flow	24 hours	?	?	Has to walk about	Yes	—	—	13 months	Relief for 22 months.
				26	...	...	...	Yes	...	...	...	...	...	Relief for 2 years +
P. L. R.	14	14	22	26	Just before flow	Short	—	Yes	Somewhat relieved by lying down	—	—	Slightly relieved by medicine	4 years	Relief for 4 months.
				29	„	„	...	„	...	...	...	...	7 years	Relief for 10 mos. +
R. L.	11	17	24	32	A week before flow	8 days	?	?	Not relieved by lying down	Nausea	—	—	8 years	Relief for 1 month.
				34	...	...	...	...	...	...	...	...	10 years	Relief for 6 years +

The last point to which we direct attention is the association of spasmodic dysmenorrhœa with sterility, and its cure by dilatation.

Fertility—62 married patients.

Before dilatation 2:

1 of the successful cases had had 2 miscarriages.

1 of the unsuccessful cases had had 9 children and 2 miscarriages.

After dilatation 16 patients became pregnant, all of them among the successful cases, *i. e.* 16 out of 41, or 39 per cent.

	Period of sterile marriage before dilatation.	Interval between dilatation and pregnancy.
(i)	1 month	1 month.
(ii)	2 months	?
(iii)	6 months	2 months.
(iv)	10 years to first husband; 6 months to second ...	2 months.
(v)	7 months	2 months.
(vi)	1 year	?
(vii)	1 year	10 months.
(viii)	13 months	1 month.
(ix)	14 months	1 month.
(x)	2 years	5 months.
(xi)	2 years	8 months.
(xii)	2 years	9 months.
(xiii)	3½ years	?
(xiv)	5 years	Under 1 year.
(xv)	6 years	14 months.
(xvi)	10 years	?

No. viii, who had been married thirteen months before treatment, had had vaginal fixation performed, and the vaginal orifice enlarged.

In none of the other cases which became pregnant after dilatation had the vaginal orifice been enlarged.

The pain began after marriage in—

4 out of 39 successful cases, or 10 per cent.

7 out of 19 unsuccessful cases, or 37 per cent.

The PRESIDENT agreed with the authors that, speaking generally and broadly, it was true that when the pain in dysmenorrhœa was paroxysmal, it was more likely to be of uterine than of ovarian origin. But like most other things in medicine, surgery, and obstetrics, it was impossible to deduce definite laws without having to admit numerous exceptions. Hence, for the purposes of treatment, it was of little use in the majority of cases making or trying to make a diagnosis. For even if a case presented features pointing to other than a uterine cause for the pain, it was impossible to say beforehand that dilatation would not lessen or cure the pain. He gave details of a case of undoubted ovarian dysmenorrhœa where there was a congenital absence of vagina, and where the uterus was represented by a mere band, and yet where the pain every month was so severe that the patient was in agony and was obliged to go to bed for several days. The ovaries, after every other means had been tried, were removed by abdominal section, and the patient had never been troubled since, the operation having been done in 1898. Again he asked for information as to the method of dilatation. The authors spoke of dilating the cervix. Did they dilate the cervix only, or did they dilate the uterine cavity as well? Did they use Hegar's dilators, and if so, to what number did they go? He believed that, whatever theory in regard to the production of the pain or of its relief by dilatation might be correct, it would be found that the alleviation or cure of the dysmenorrhœa was owing to laceration of the fibres. For this reason he had himself adopted a modification of Sims' operation. That is, in addition to slitting the cervix backwards from the os externum up to the posterior fornix, he made a counter-incision to the left or to the right of the cervix, which thus divided the cervix into two unequal parts, a quarter and three quarters respectively. His object in doing this was to cut through the circular fibres twice. For he had found from experience that Sims' operation, even though it relieved for a time, was apt to be followed by a recurrence of the dysmenorrhœa, owing to the cicatrisation of the parts. Whereas, by cutting through the circular fibres twice, each set—that is the set in the quarter segment and the set in the three-quarter segment—contracted, and even when the active contraction passed off remained shortened, having no longer power to approximate. Hence the increased space in the os externum and cervical canal remained more or less permanent. In this way he had treated many cases with conspicuous success, and certainly with much better results than by mere dilatation. For obviously, if dilatation were carried out to only a slight degree, the uterus was bound to contract again, and the condition would soon be as before, whilst if carried to a considerable extent the parts were more or less lacerated. His colleague, Dr. Galabin, was in the habit of dilating with Hegar's dilators

to a considerable degree, he thought to No. 19; and as a rule the parts were lacerated, as indicated by a dilator of a higher number passing more easily than the one immediately preceding it. Then, again, the authors spoke of cases of stenosis of the os uteri as existing only in pictures in text-books. He could not agree to that, for he had seen cases of pinhole os where it was impossible to pass an ordinary uterine sound, and where there was great dysmenorrhœa. Moreover such cases were very satisfactorily treated by a modified Sims' operation. Again, he disagreed with the remark that it was of no importance as to whether a patient passed membranes or not, inasmuch as the treatment was the same—namely, dilatation. His own experience was that dilatation or a modified Sims' operation was practically useless in membranous dysmenorrhœa. In all such cases he recommended careful and thorough curetting and the application of a strong caustic, such as iodised phenol or pure carbolic acid. The authors had suggested a new theory as to the cause of the pain in these cases of uterine dysmenorrhœa, namely, that it was due to the cervix not dilating when the fundus and body contracted. He did not think this was a correct expression, because the law was that when the fundus and body of the uterus contracted the cervix relaxed. Then, when in this physiologically relaxed condition, it could be easily dilated if there were anything to dilate it, such as the bag of waters, or if the amnion had ruptured, the child's head, etc. Certainly there were some longitudinal fibres in the cervix which could draw it open, even in the absence of these dilating forces, but they only came into operation at a late stage. Hence we did not find the os uteri patent in these cases of uterine dysmenorrhœa. Finally, he thought that whilst the menses when fluid found a free enough exit, they might, when clotted inside the uterus, require uterine contractions that amounted to miniature labour pains, and which were as painful sometimes as labour pains, to expel the clots.

Dr. Heywood Smith considered that the dysmenorrhœa characterised by forcing pain at the beginning of the flow was usually due to anteflexion. He agreed to what had fallen from the President, that the acting pre-menstrual pain was generally due to ovarian mischief, and probably also to chronic endometritis. As to the cause of the pain in cases of anteflexion, where the sound could be passed without any marked obstruction, he considered as a possible explanation that it was due to the overcoming effort to extrude the discharge through the inner os, which was temporarily obstructed by the hypertrophic engorgement of the mucous membrane of the body of the uterus producing a kind of bulging at the line of the inner os. He agreed also with the President that cases of membranous dysmenorrhœa demanded more than mere dilatation, and he had found that the

application of iodoised phenol was of great service in such cases. As to the treatment of dysmenorrhœa from stenosis of the inner os, he did not consider dilatation alone sufficient, and the authors had referred to cases that had required repeated dilatations. The cavity of the uterus, on being dilated, tended to contract again to its former condition. What was necessary was dilatation *plus* a slight incision bilaterally, then forcible dilatation until some fibres were felt to give way, and the insertion of a sterilised glass stem with a large button, which, resting on the posterior vaginal wall, would prevent it being extruded.

Dr. Boxall doubted whether, in such a case as that mentioned by the President, cessation of dysmenorrhœa after removal of the ovaries could be rightly regarded as affording conclusive evidence that the pain had been of ovarian and not of uterine origin. Many years ago he had the opportunity of observing a remarkable case of dysmenorrhœa under the care of Sir John Williams in University College Hospital. The patient, apparently a woman (at any rate she had been up till that time regarded as such), possessed a deep bass voice. She had a large clitoris and a rudimentary vagina and uterus. She was kept under observation for some months suffering from severe dysmenorrhœa, and eventually, other means having failed to give relief, the abdomen was opened. No trace of ovary could be found on either side, but on one side was found what appeared to be a rudimentary and undescended testis. Now the curious part of the case is that, though nothing whatever was removed, the dysmenorrhœa was forthwith relieved. In that case, at any rate, the pain could not have been ovarian in character. He also drew attention to one rather remarkable fact which he had observed in some cases of dysmenorrhœa associated with sterility, where the uterus was quite small, say no larger than the top of one's thumb. In spite of this ill-developed condition impregnation had rapidly followed dilatation, and the patient had carried to term and been delivered without unusual difficulty.

Dr. Alexander Duke quite agreed with the President that "there was a large percentage of cases of dysmenorrhœa not referable to the uterus at all." In cases of (so-called) "obstructive" he has had excellent results by incision and dilatation combined, followed directly by the insertion of his "spiral wire stem," which, if left long enough in cervix, was certain to maintain the permanent patency of that canal, the all-important result looked for. Dr. Heywood Smith had alluded to the wearing of a glass stem by patient after dilatation, but the difficulty was to keep such from falling out if patient were not confined to recumbent position. His own stem, being flexible and hinged on disc at base, kept its place, and allowed wearer to go about as usual quite unconscious of its presence, and some of his patients rode bicycles while wearing the stem without any injury or discom-

fort. The stem being open from end to end allowed free exit of the secretions (acting as drainage-tube), and often in this way cured the endometritis which co-existed in a number of such cases, and which he considers might sometimes be the primary cause of the complaint. Dr. Herman's paper mentioned some cases which had to be dilated more than once. If the first dilatation had been maintained by the wearing of a suitable stem, there should have been no necessity for re-dilatation. He leaves the stem *in utero* till it becomes loose, *i. e.* moving freely up and down, thus conquering the spasm, the main factor in the discomfort complained of in the greater number of these cases. His stem being flexible and hinged yields to every movement of the uterus, and if the patient be directed to use a syringe or douche *regularly* (period included) with hot water morning and night, Dr. Duke has seen no harm, but positive advantage and permanent cure, conception following in a fair number of cases.

Dr. Arthur Giles remarked that the paper served a useful and practical purpose in defining the type of dysmenorrhœa in which dilatation was likely to be successful. The authors had shown that this treatment was not suitable for cases of dysmenorrhœa in which the pain occurred chiefly before the onset of the flow; and this was easily understood, because such pain was congestive in origin, and they could not hope to cure congestion occurring before menstruation by dilatation. He agreed with the authors that "obstructive" dysmenorrhœa was a fallacy, and he did not hold the view which the authors appeared to attribute to him, that anteflexion could cause obstruction or was necessarily a cause of dysmenorrhœa. It was, of course, a fact that anteflexion was often associated with dysmenorrhœa, but if any causal relation existed it seemed to him that it was probably this, that the flexion led to painful contractions. The cause of painful uterine contractions was obscure, and before they could be explained it would be necessary to explain why uterine contractions during labour were painful, and why certain intestinal contractions were painful, causing colic. He was interested in Dr. Boxall's cases of under-developed uterus, and thought that Dr. Boxall's experience was unusual. In his experience the striking features of menstruation in cases of under-developed uterus were that the function started late and was painless, while the flow was scanty, and sterility was almost the rule.

Dr. Galabin said that he thought that the diagnosis by description of symptoms as to whether a dysmenorrhœa were due to painful uterine contractions was apt to be fallacious. If the pains were continuous, and began several days before the flow, it might doubtless be inferred that the cause of it was congestive or inflammatory; but many women described the pain as being intermittent, spasmodic, or paroxysmal. On cross-examination, however, it often appeared that the spasms of pain lasted for

half an hour or more, and all kinds of intermediate conditions were found. Such pains could hardly be due to uterine contractions, and were only spasmodic in the sense in which a toothache or any neuralgic pain might be spasmodic. His experience was that the proportion of cases of dysmenorrhœa which could be ascribed wholly and with certainty to painful uterine contractions was a very small one, and that much more frequently some inflammatory or congested condition of the endometrium was an element in the case. This was confirmed by the fact that uterine leucorrhœa was often associated with dysmenorrhœa in young unmarried women, and that not infrequently a patch of granular inflammation was found around the os, really an adenomatous hyperplasia of mucous membrane. Accordingly he thought that the addition of curetting to dilatation in the majority of cases increased the efficacy of the operation. He did not usually carry the dilatation beyond about No. 13 or 14 Hegar's dilator. This did not generally lacerate the external os, but might rupture some fibres around the internal os. Of late years he had used incisions of the vaginal portion only when the external os was manifestly minute. He then excised a V-shaped piece from the posterior lip, and generally united external and internal mucous membrane by sutures. The authors appeared to assume that if dilatation cured the dysmenorrhœa it was a proof that the pain was due to painful uterine contraction. He did not think that this held good universally, for dilatation might affect the uterus in other ways. If there were endometritis the freer drainage so produced might enable a catarrh to get well which would have remained chronic while sufficient mucus was retained to form a nidus for microbes.

Dr. Lewers said he had intended to make the same inquiry as had been made by the President as to the degree of dilatation of the cervix employed by the authors in their cases. Perhaps this information would be found in their tables. For his own part, he found the extent to which the cervix of a nullipara could be dilated varied considerably. In some cases it was impossible, without risk of lacerating the cervix, to go beyond No. 9 or No. 10 of Hegar's bougies. In other nulliparæ it was possible to go as far as No. 16 or 17 of the same series without much difficulty. His practice was to go on till some distinct difficulty in passing the dilator was met with. He usually found that the passing of the bougie when this occurred was followed by a little fresh bleeding, probably due to a very superficial laceration about the internal os. When this occurred he considered the safe degree of dilatation had been reached.

Dr. W. S. A. Griffith criticised the title of the paper, which would have been more explicit had it been "A Contribution to the Study of Certain Cases of Spasmodic Dysmenorrhœa treated by Dilatation." The necessity for a definite limit to the dis-

cussion of this subject was evident, for there was no common symptom of which our knowledge was more imperfect, and about which such various views were held, than dysmenorrhœa. The paper before them was a valuable contribution to the subject. How many men began the study of dysmenorrhœa who were very imperfectly acquainted with the anatomy and physiology of normal menstruation! From this arose some of the extraordinary assertions by writers on the subject, and no disease gave greater opportunities to faddists of all kinds to proclaim the virtues of their special mode of treatment by pessary or metrotome. The study of the rare cases of spasmodic dysmenorrhœa without menstrual flow, of which Dr. Griffith had had one typical case under his care, should help to remove some errors, and in his opinion the different degrees of pain suffered depended more on the nerve sensibility of the individual than on structural variations of the uterus and its appendages; and these excellent results were obtainable by the judicious treatment of points of general health in a very large number of cases, without either direct examination or treatment of the organs in which the pain arises. Dilatation was a valuable method in some of the more severe and persistent cases. He had frequently met with cases of "pinhole os" in which dysmenorrhœa was absent. The statement of the passage of clot or membrane was of little value unless an accurate examination of them was made.

Dr. Briggs alluded to the uncertainty of results, but agreed in the main with the authors of the paper in their conclusions as to the cases of dysmenorrhœa most likely to be benefited by dilatation or section of the cervix. He desired to speak on behalf of the Liverpool practice of a high degree of dilatation supplemented by a deep posterior section of the cervix throughout its entire length. The graduation of metal bougies over four sizes which he first adopted in 1889 had simplified dilatation by minimising laceration. Notwithstanding the complete character of the Liverpool practice, the results, he feared, were not more, but less encouraging than those of the authors of the paper. He had some hesitation in accepting spasm as more than a minor portion of the pathology in cases apparently spasmodic.

Dr. Herman said that the authors were aware of the difficulties and uncertainties referred to by the President and Dr. Galabin, and had alluded to them in their paper. The pain of pelvic congestion was, as they said, often described as coming and going; but on close inquiry it would be found that each attack was said to last an hour or two; it was not a sharp, short spasm like that of uterine colic. In the cases on which the paper was based the dilatation was of both the external and internal os, and was done with bougies, graduated in size according to the catheter scale. Successive sizes were passed

until considerable resistance was met with. Usually it was carried up to No. 12 or higher. After such dilatation the cervical canal remained larger than before for at least some months. This he had verified by measurement. When he commenced practice, the regular treatment for bad cases of dysmenorrhœa at most hospitals, certainly at the London, was division of the vaginal portion. He was led to abandon that by meeting with cases in which the vaginal portion had been divided without benefit, but which were cured by dilatation with bougies of the os internum. He would like to know what meaning the President attached to the word "permanent," when he spoke of "permanent cures" of dysmenorrhœa. He (Dr. Herman) thought the use of the word "permanent" was only justifiable if the patient's condition was known up to the time when menstruation ceased. It was so difficult in consulting practice to watch cases as long as this, that he thought cases known to be permanent cures must be few. He had himself records of one case in whom the cure of dysmenorrhœa lasted till the menopause. He would like to know how many cases of the "permanent" cure of membranous dysmenorrhœa the President had seen. He (Dr. Herman) had known curetting and caustic fail, not only in his own hands, but in those of others. He thought dilatation was the most effective treatment of membranous dysmenorrhœa. He would also like to know how membranous dysmenorrhœa was to be prevented. Like Dr. Griffith and others, he had seen cases in which the os externum was so small that it would not admit a probe, but the patients menstruated without pain. In such cases he thought it was good practice to divide the vaginal portion in order to prevent delay in the first stage of labour. When clots were passed from the vagina he knew no sure way of telling whether the blood had clotted in the uterus or in the vagina. Many small lumps described by patients as clots, if carefully examined, would be found to be rolled-up membranes. The President's distinction between "dilatation" and "relaxation" seemed to him verbal rather than real. He (Dr. Herman) had shown in a former communication to the Society that the cervical canal did enlarge during menstruation. He agreed with Dr. Heywood Smith and Dr. Giles that anteflexion was common with dysmenorrhœa. But his investigation and that of Vedeler showed that it was present with exactly the same frequency in women who menstruated without pain; and these facts had never been controverted. If Dr. Heywood Smith and Dr. Giles would study the frequency of anteflexion without dysmenorrhœa they would change their views. Seeing that most patients with dysmenorrhœa were young girls who, except for their monthly pain, were in perfect health, he did not think with Dr. Galabin they were frequently suffering from endometritis, nor that dilatation cured them because it favoured the cure of

endometritis. He agreed that it was difficult to distinguish the cases that could be cured by dilatation from those that could not; and it was the object of the paper to assist in this difficult task. He agreed with Dr. Griffith that the severity of menstrual pain depended much on the sensitiveness of the patient.

INDEX.

PAGE

Abortion, tubal (J. Bland-Sutton) . . . 44
Abscess, ovarian, rupture twelve hours after labour (C. Berkeley) 73
Address (*Annual*) *of the President*, Peter Horrocks, M.D., February 5th, 1902 53
Adeno-carcinoma of both ovaries (A. W. W. Lea) . . 225
Amputation, supra-vaginal, for cancer of the cervix, in which from four to fifteen years had elapsed without recurrence (A. H. N. Lewers) 221
Anatomy, pathological, of five specimens of fibroid tumour of the ovary (J. S. Fairbairn) 177
Andrews (H. Russell), congenital prolapse of the uterus associated with spina bifida 137
—— *Remarks* in reply 140
—— and G. Ernest Herman, contribution to the natural history of dysmenorrhœa 371
Annual General Meeting, February 5th, 1902 . . 38
Autopsy and remarks on puerperal eclampsia (R. H. Bell) . 253

Balls, epithelial, dermoid cyst containing a large number of (W. F. V. Bonney) 354
Bell (R. H.), "paratubal" hæmatocele . . . 322
—— puerperal eclampsia, with autopsy and remarks . 253
—— *Report* of Committee 310
Berkeley (Comyns), rupture of an ovarian abscess twelve hours after labour 73
—— spontaneous expulsion 320
—— *Report* of Committee 77

PAGE

BLACKER (G. F.), *Report* on Alban Doran's specimen of retro-peritoneal lipoma (p. 265) 310
—— —— on A. H. N. Lewers's specimen of uterus removed by abdominal pan-hysterectomy for primary carcinoma of the body 291
—— —— on C. Berkeley's specimen of ovarian abscess ruptured during labour 77
—— —— on F. J. McCann's specimen of "deciduoma malignum" after the menopause . . . 296
—— —— on Hugh S. Stannus's specimen of orbital tumour in a fœtus 91
—— —— on J. Bland-Sutton's case of primary cancer of the Fallopian tube 314
—— —— on J. H. Dauber's specimen of ruptured tubal gestation 322
—— —— on J. M. Munro Kerr's specimen of tumour of the uterus 131
—— —— on sections from the liver in R. Hamilton Bell's case of puerperal eclampsia (p. 253) . . . 310
—— —— on W. C. Swayne's specimen of sarcoma of the body of the uterus with complete inversion . . . 368
—— —— on W. F. V. Bonney's specimen of solid ovarian tumour with a cyst attached, with the tube open . 93
—— *Remarks* in discussion on J. W. Taylor's paper on complete inversion of uterus of seven months' duration, etc. 305

BLAND-SUTTON (J.), primary cancer of the Fallopian tube . 311
—— *Remarks* in reply 315
—— tubal pregnancy diagnosed before rupture, and a case of tubal abortion 44
—— *Remarks* in reply 46
—— two cases of extra-uterine gestation which went to term 316
—— *Report* of Committee 313
—— *Remarks* in discussion on J. S. Fairbairn's paper on five specimens of fibroid tumour of the ovary, with observations on their pathological anatomy . . . 209
—— —— in discussion on A. Doran's paper on pregnancy after removal of both ovaries for cystic tumour . 244
—— —— in discussion on W. Sampson Handley's paper on paratubal hæmatocele 349

BONNEY (W. F. Victor), dermoid cyst containing a large number of epithelial balls 354

PAGE
Bonney (W. F. Victor), *Remarks* in reply . . . 359
—— probable case of superfœtation . . . 163
—— solid tumour of the left ovary with an attached cyst communicating with the left Fallopian tube . . 92
—— uterus and vagina with the child *in situ* in the second stage of labour 292
—— *Report* of Committee 93
—— —— on C. Berkeley's specimen of ovarian abscess ruptured during labour 77
—— *Remarks* in discussion on J. W. Taylor's paper on complete inversion of uterus of seven months' duration, etc. . 304
Boxall (Robert), *Remarks* in discussion on R. G. McKerron's paper on suppression of urine after labour . . 118
—— —— in discussion on A. H. N. Lewers's specimens of cancer of the cervix from eight cases treated by the supravaginal amputation, in which from four to fifteen years had elapsed without recurrence . . . 224
—— —— in discussion on A. Doran's paper on pregnancy after removal of both ovaries for cystic tumour . . 248
—— —— in discussion on G. Ernest Herman and H. Russell Andrews's paper on the natural history of dysmenorrhœa 391
Boyd (Florence Nightingale), fibroma of ovary . . 176
Boyd (Stanley), *Remarks* in discussion on J. Bland-Sutton's case of primary cancer of the Fallopian tube . . 314
Breast: lymphangitis mammæ—an affection arising about the tenth day of the puerperium with well-marked clinical features (R. H. Vincent) 153
Briggs (Henry), *Remarks* in discussion on J. S. Fairbairn's paper on five specimens of fibroid tumour of the ovary, with observations on their pathological anatomy . 210
—— —— in discussion on A. E. Giles's specimen of fibroma of the ovary 361
—— —— in discussion on G. Ernest Herman and H. Russell Andrews's paper on the natural history of dysmenorrhœa 394
Butler-Smythe (A. C.), *Remarks* in discussion on A. Doran's paper on pregnancy after removal of both ovaries for cystic tumour 247
—— —— in discussion on J. W. Taylor's paper on complete inversion of uterus of seven months' duration, etc. . 304
—— —— in discussion on W. F. V. Bonney's specimen of a dermoid cyst containing a large number of epithelial balls 359

PAGE

Cancer of the body of uterus, abdominal pan-hysterectomy for (A. H. N. Lewers) 10
—— of the cervix from eight cases treated by the supra-vaginal amputation, in which from four to fifteen years had elapsed without recurrence (A. H. N. Lewers) . 221
—— primary, of the Fallopian tube (J. Bland-Sutton) . 311
—— —— tuberculosis of the cervix simulating, treated by vaginal hysterectomy (A. H. N. Lewers) . . 144
—— squamous, of the cervix uteri (F. J. McCann) . . 136
Carcinoma, primary, of the body, uterus removed by abdominal pan-hysterectomy for (A. H. N. Lewers) . . 290
—— squamous, of cervix uteri (F. J. McCann) . . 136
—— see *Cancer*.
Cervix uteri, squamous carcinoma of (F. J. McCann) . 136
—— tuberculosis of (E. O. Croft). . . . 142
—— three months' gravid uterus removed by vaginal hysterectomy for squamous epithelioma of (W. Duncan) . 297
—— uterus showing rapidly growing epithelioma of; death from recurrence five months after removal (C. Lockyer) . 284
Champneys (F. H.), *Remarks* in discussion on A. Routh's specimen of dermoid cyst of ovary removed by posterior colpotomy 40
—— —— in discussion on A. Routh's specimen of uterus removed at eight and a half months of gestation by abdominal hysterectomy for fibroid obstructing labour . 43
Chorio-epithelioma with pulmonary metastases (Cuthbert Lockyer) 24
Cœliotomy, anterior vaginal, anterior hysterectomy and replacement, with recovery after failure of elastic pressure with repositors in a case of complete inversion of uterus of seven months' duration (J. W. Taylor) . . 299
Colpotomy for removal of tubal mole (F. J. McCann) . 133
—— posterior, for removal of dermoid cyst of ovary (A. Routh) 38
Cord, see *Funis, Umbilical*.
Croft (E. O.), tuberculosis of cervix . . . 142
—— *Remarks* in reply 154
Cullingworth (C. J.), *Remarks* in discussion on R. H. Bell's case of puerperal eclampsia, with autopsy and remarks 264
—— —— in discussion on A. Doran's specimen of retro-peritoneal lipoma weighing thirteen pounds twelve ounces 273

PAGE

CULLINGWORTH (C. J.), *Remarks* in discussion on W. Sampson Handley's paper on paratubal hæmatocele . . 348
Cyst, dermoid, containing a large number of epithelial balls (W. F. Victor Bonney) 354
—— —— of ovary removed by posterior colpotomy (A. Routh) 38
—— (?) parasitic, of vulva (A. J. Sturmer) . . 2
—— unilocular ovarian, containing solid masses undergoing necrotic change (J. S. Fairbairn) . . . 126

DAUBER (J. H.), ruptured tubal gestation . . . 321
"Deciduoma malignum" after the menopause (F. J. McCann) 294
Dermoid cyst, see *Cyst*.
DONALD (Archibald), *Report* on W. E. Fothergill's specimen of decidual uterine cast of seven weeks' growth, together with an ovum of about five days' growth (shown June 5th, 1901) 252
DORAN (A.), fibroma of ovary one third of an inch in diameter 173
—— pregnancy after removal of both ovaries for cystic tumour 231
—— *Remarks* in reply 248
—— pure fibroma of the ovary 172
—— pure myoma of the ovary, with a microscopic section . 168
—— retro-peritoneal lipoma weighing thirteen pounds twelve ounces 265
—— *Remarks* in reply 273
—— *Report* of Committee 310
—— —— on A. E. Giles's specimen of fibroma of the ovary . 362
—— —— on A. H. N. Lewers's specimen of uterus removed by abdominal pan-hysterectomy for primary carcinoma of the body 291
—— —— on C. Berkeley's specimen of ovarian abscess ruptured during labour 77
—— —— on F. J. McCann's specimen of "deciduoma malignum" after the menopause . . . 296
—— —— on H. Williamson's specimen of a rudimentary horn of a uterus bicornis 228
—— —— on Hugh S. Stannus's specimen of orbital tumour in a fœtus 91
—— —— on J. Bland-Sutton's case of primary cancer of the Fallopian tube 314

PAGE

Doran (A.), *Report* on J. H. Dauber's specimen of ruptured tubal gestation 322
—— —— on J. M. Munro Kerr's specimen of tumour of the uterus 131
—— —— on P. Horrocks's specimen of ectopic gestation . 229
—— —— on sections from the liver in R. H. Bell's case of puerperal eclampsia (p. 253) 310
—— —— on W. C. Swayne's specimen of sarcoma of the body of the uterus with complete inversion . . . 368
—— —— on W. F. V. Bonney's specimen of solid ovarian tumour with a cyst attached, with the tube open . 93
—— —— on W. W. H. Tate's specimen of sarcoma of the uterus (shown May 7th, 1902) 252
—— *Remarks* in discussion on C. Lockyer's paper on a case of chorio-epithelioma with pulmonary metastases . 37
—— —— in discussion on J. S. Fairbairn's paper on five specimens of fibroid tumour of the ovary, with observations on their pathological anatomy . . . 208
—— —— in discussion on A. W. Mayo Robson's specimen of primary ovarian gestation 220
—— —— in discussion on A. H. N. Lewers's specimen of fibroid of the broad ligament, weighing four and a half pounds, with twisted pedicle 365
Duke (Alexander), *Remarks* in discussion on G. Ernest Herman and H. Russell Andrews's paper on the natural history of dysmenorrhœa 391
Duncan (William), three months' gravid uterus removed by vaginal hysterectomy for squamous epithelioma of cervix 297
—— *Remarks* in discussion on C. Lockyer's specimen of uterus showing rapidly growing epithelioma of the cervix; death from recurrence five months after removal . . 289
—— —— in discussion on J. W. Taylor's paper on complete inversion of uterus of seven months' duration, etc. . 305
Dysmenorrhœa, contribution to the natural history of (G. Ernest Herman and H. Russell Andrews) . . 371

Eclampsia, primary, pneumococcus meningitis simulating puerperal (T. Wilson) 5
—— puerperal, with autopsy and remarks (R. H. Bell) . 253
Eden (T. W.), *Report* on A. H. N. Lewers's specimen of uterus removed by abdominal pan-hysterectomy for primary carcinoma of the body 291

PAGE

EDEN (T. W.), *Report* on A. J. Sturmer's specimen of parasitic cyst of the vulva 5
—— —— on F. J. McCann's specimen of "deciduoma malignum" after the menopause 296
—— —— on sections from the liver in R. H. Bell's case of puerperal eclampsia (p. 253) 310
—— —— on W. E. Fothergill's specimen of decidual uterine cast of seven weeks' growth, together with an ovum of about five days' growth (shown June 5th, 1901) . 252
—— *Remarks* in discussion on C. Berkeley's specimen of ovarian abscess ruptured during labour . . 77
—— —— in discussion on R. H. Bell's case of puerperal eclampsia, with autopsy and remarks . . . 264
—— —— in discussion on W. Sampson Handley's paper on paratubal hæmatocele 347

Election of New Fellows . 1, 38, 73, 125, 157, 215, 251, 309, 353
Epithelioma of the cervix, uterus showing rapidly growing; death from recurrence five months after removal (C. Lockyer) 284
—— squamous, of cervix uteri, three months' gravid uterus removed by vaginal hysterectomy for (W. Duncan) . 297
Expulsion, spontaneous (C. Berkeley) . . . 320

FAIRBAIRN (J. S.), five specimens of fibroid tumour of the ovary, with observations on their pathological anatomy . 177
—— *Remarks* in reply 212
—— unilocular ovarian cyst containing solid masses undergoing necrotic change 126
—— *Report* on A. E. Giles's specimen of fibroma of the ovary 362
—— —— on A. H. N. Lewers's specimen of uterus removed by abdominal pan-hysterectomy for primary carcinoma of the body 291
—— —— on F. J. McCann's specimen of "deciduoma malignum" after the menopause . . . 296
—— —— on H. Williamson's specimen of pregnancy in rudimentary horn of a uterus bicornis . . 228
—— —— on J. Bland-Sutton's case of primary cancer of the Fallopian tube 314
—— —— on J. H. Dauber's specimen of ruptured tubal gestation 322

PAGE

FAIRBAIRN (J. S.). *Report* on J. M. Munro Kerr's specimen of tumour of the uterus 131
—— —— on P. Horrocks's specimen of ectopic gestation . 229
—— —— on sections from the liver in R. H. Bell's case of puerperal eclampsia (p. 253) 310
—— —— on W. C. Swayne's specimen of sarcoma of the body of the uterus with complete inversion . . . 368
—— —— on W. W. H. Tate's specimen of sarcoma of the uterus (shown May 7th, 1902) . . . 252
—— *Remarks* in discussion on J. Bland-Sutton's case of primary cancer of the Fallopian tube . . . 314
Fallopian tube, primary cancer of (J. Bland-Sutton) . 311
—— ruptured towards its fimbriated end in two places (Amand Routh) 131
—— solid tumour of the left ovary with an attached cyst communicating with the left (W. F. V. Bonney) . 92
Fellows, see *Lists, Elections.*
Fibroid, cystic, of uterus (W. C. Swayne) . . . 369
—— of the broad ligament, weighing four and a half pounds, with twisted pedicle (A. H. N. Lewers) . . 364
—— tumour of the ovary, five specimens, with observations on their pathological anatomy (J. S. Fairbairn) . . 177
—— see *Tumours*, fibroid.
Fibroma of ovary (F. N. Boyd) 176
—— of ovary one third of an inch in diameter (A. Doran) . 173
—— of the ovary (A. E. Giles) 360
—— pure, of ovary (A. Doran) 172
—— uteri, small, showing sarcomatous changes (J. M. Munro Kerr) 129
Fibro-myoma of the vagina (J. M. Munro Kerr) . . 130
Fœtation, see *Pregnancy.*
Fœtus, teratoma of head of (Hugh S. Stannus) . . 78
FOTHERGILL (W. E.), *Report* of Committee . . 252
Funis, abnormal umbilical (H. Williamson) . . 141

GALABIN (A. L.), *Remarks* in discussion on P. Horrocks's specimen of extra-uterine fœtation . . . 229
—— —— in discussion on A. Doran's paper on pregnancy after removal of both ovaries for cystic tumour . . 246
—— —— in discussion on J. W. Taylor's paper on ovarian tumour obstructing delivery; posterior vaginal section and ovariotomy during labour; operation and delivery at one sitting; recovery 278

PAGE

GALABIN (A. L.), *Remarks* in discussion on G. Ernest Herman and H. Russell Andrews's paper on the natural history of dysmenorrhœa 392
Gestation, see *Pregnancy*.
GILES (Arthur E.), fibroma of the ovary . . . 360
—— *Report* of Committee 361
—— *Remarks* in discussion on G. Ernest Herman and H. Russell Andrews's paper on the natural history of dysmenorrhœa 392
Glycosuria in a patient with gangrenous sarcoma of uterus removed by abdominal hysterectomy (W. W. H. Tate) . 165
Goddard, Eugene, M.D., obituary notice of . . 69
GRIFFITH (Walter Spencer A.), *Remarks* in discussion on C. Berkeley's specimen of ovarian abscess ruptured during labour 78
—— —— in discussion on R. G. McKerron's paper on suppression of urine after labour . . . 123
—— —— in discussion on J. S. Fairbairn's paper on five specimens of fibroid tumour of the ovary, with observations on their pathological anatomy . . . 210
—— —— in discussion on W. Sampson Handley's paper on paratubal hæmatocele 349
—— —— in discussion on G. Ernest Herman and H. Russell Andrews's paper on the natural history of dysmenorrhœa 393

Hæmatocele, "paratubal" (R. H. Bell) . . . 322
—— —— (W. S. Handley) 325
HANDFIELD-JONES (M.), *Remarks* in discussion on J. W. Taylor's paper on ovarian tumour obstructing delivery; posterior vaginal section and ovariotomy during labour; operation and delivery at one sitting; recovery . . 279
—— —— in discussion on J. W. Taylor's paper on complete inversion of uterus of seven months' duration, etc. . 304
—— —— in discussion on J. Bland-Sutton's case of primary cancer of the Fallopian tube 314
HANDLEY (W. Sampson), on paratubal hæmatocele . . 325
—— *Remarks* in reply 350
Harvey, Robert, C.B., D.S.O., of Simla, India, obituary notice of 71
HERMAN (G. Ernest), and H. RUSSELL ANDREWS, contribution to the natural history of dysmenorrhœa . . 371
—— *Remarks* in reply 394

PAGE

HERMAN (G. Ernest), *Remarks* in discussion on A. Routh's specimen of dermoid cyst of ovary removed by posterior colpotomy 40

—— —— in discussion on J. Bland-Sutton's specimen of a case of tubal pregnancy diagnosed before rupture and a case of tubal abortion 46

History, natural, of dysmenorrhœa (G. Ernest Herman and H. Russell Andrews) 371

HORROCKS (P.), Annual Address as President . . 53

—— extra-uterine fœtation 228

—— sarcoma of ovary 94

—— tubercle of the uterus 141

—— *Remarks* in discussion on T. Wilson's specimen of primary pneumococcus meningitis simulating puerperal eclampsia 5

—— —— in discussion on C. Lockyer's paper on a case of chorio-epithelioma with pulmonary metastases . . 36

—— —— in discussion on A. Routh's specimen of dermoid cyst of ovary removed by posterior colpotomy . . 38

—— —— in discussion on J. Bland-Sutton's specimen of a case of tubal pregnancy diagnosed before rupture, and a case of tubal abortion 44

—— —— in discussion on C. Berkeley's specimen of ovarian abscess ruptured during labour . . . 77

—— —— in discussion on A. H. N. Lewers's paper on primary tuberculosis of the cervix simulating cancer and treated by vaginal hysterectomy . . . 154

—— —— in discussion on W. W. H. Tate's specimen of gangrenous sarcoma of uterus removed by abdominal hysterectomy from a patient suffering from glycosuria 168

—— —— in discussion on J. S. Fairbairn's paper on five specimens of fibroid tumour of the ovary, with observations on their pathological anatomy . . . 211

—— —— in discussion on A. Doran's paper on pregnancy after removal of both ovaries for cystic tumour . . 247

—— —— in discussion on R. H. Bell's case of puerperal eclampsia, with autopsy and remarks . . . 265

—— —— in discussion on J. W. Taylor's paper on ovarian tumour obstructing delivery; posterior vaginal section and ovariotomy during labour; operation and delivery at one sitting; recovery 279

PAGE

Horrocks (P.), *Remarks* in discussion on J. W. Taylor's paper on complete inversion of uterus of seven months' duration, etc. 306
—— —— in discussion on J. Bland-Sutton's case of primary cancer of the Fallopian tube 315
—— —— in discussion on W. Sampson Handley's paper on paratubal hæmatocele 350
—— —— in discussion on A. E. Giles's specimen of fibroma of the ovary 361
—— —— in discussion on G. Ernest Herman and H. Russell Andrews's paper on the natural history of dysmenorrhœa 389
Hysterectomy, abdominal, for fibroid obstructing labour, uterus removed at eight and a half months of gestation by (A. Routh) 41
—— —— for removal of gangrenous sarcoma of uterus from a patient suffering from glycosuria (W. W. H. Tate) . 165
—— vaginal, for primary tuberculosis of the cervix simulating cancer (A. H. N. Lewers) 144
—— —— removal of three months' gravid uterus for squamous epithelioma of cervix by (W. Duncan) 297
Hysterotomy, anterior, and anterior vaginal cœliotomy and replacement with recovery for complete inversion of seven months' duration after failure of elastic pressure with repositors (J. W. Taylor) 299

Icterus neonatorum (A. W. Sikes) 369
Inversion, complete, of uterus of seven months' duration; failure of elastic pressure with repositors; operation of anterior vaginal cœliotomy, anterior hysterotomy, and replacement; recovery (J. W. Taylor) 299
—— sarcoma of the body of the uterus with complete (W. C. Swayne) 366

Keep (A. Corrie), *Report* on A. E. Giles's specimen of fibroma of the ovary 362
—— —— on C. Berkeley's specimen of ovarian abscess ruptured during labour 77
—— —— on H. Williamson's specimen of rudimentary horn of a uterus bicornis. 228
—— —— on J. M. Munro Kerr's specimen of tumour of the uterus 131

PAGE

KEEP (A. Corrie), *Report* on P. Horrocks's specimen of ectopic gestation 229
—— —— on W. C. Swayne's specimen of sarcoma of the body of the uterus with complete inversion . . 368
—— —— on W. F. V. Bonney's specimen of solid ovarian tumour with a cyst attached, with the tube open . 93
—— —— on W. W. H. Tate's specimen of sarcoma of the uterus (shown May 7th, 1902) . . . 252
—— *Remarks* in discussion on P. Horrocks's specimen of sarcoma of ovary 94
KERR (J. M. Munro), fibro-myoma of the vagina . . 130
—— small fibroma uteri showing sarcomatous changes . 129

Labour, ovarian tumour obstructing delivery; posterior vaginal section and ovariotomy; operation and delivery at one sitting; recovery (J. W. Taylor) . . 275
—— rupture of an ovarian abscess twelve hours after (C. Berkeley) 73
—— suppression of urine after (R. G. McKerron) . . 97
—— see *Parturition*.
Lawrence, A. E. Aust, M D., of Bristol, obituary notice of . 70
Laws, alterations in 51
LEA (Arnold W. W.), adeno-carcinoma of both ovaries . 225
LESLIE (W. Murray), *Remarks* in discussion on R. G. McKerron's paper on suppression of urine after labour . 123
LEWERS (A. H. N.), cancer of the cervix from eight cases treated by the supra-vaginal amputation, in which from four to fifteen years had elapsed without recurrence . 221
—— fibroid of the broad ligament weighing four and a half pounds, with twisted pedicle 364
—— primary tuberculosis of the cervix simulating cancer, and treated by vaginal hysterectomy . . . 144
—— *Remarks* in reply 155
—— pyosalpinx with twisted pedicle . . . 362
—— two uteri removed by abdominal pan-hysterectomy for cancer of the body 10
—— uterus removed by abdominal pan-hysterectomy for primary carcinoma of the body . . . 290
—— *Report* of Committee 291
—— *Remarks* in discussion on G. Ernest Herman and H. Russell Andrews's paper on the natural history of dysmenorrhœa 393

PAGE

Ligament, broad, fibroid of, weighing four and a half pounds, with twisted pedicle (A. H. N. Lewers) . . 364
Lipoma, retro-peritoneal, weighing thirteen pounds twelve ounces (A. Doran) 265
List of Officers elected for 1902 51
—— —— *for* 1903 v
—— *of past Presidents* ix
—— *of Referees of Papers for* 1903 . . . x
—— *of Standing Committees* . . . vii, viii
—— *of Honorary Local Secretaries* . . . viii
—— *of Honorary Fellows* . . . xi, xii
—— *of Ordinary Fellows* xiii
—— *of Deceased Fellows* [with obituary notices, which see] . 69
Lithopædion retained in patient for sixteen years (W. W. H. Tate) 95
Lockyer (Cuthbert), chorio-epithelioma with pulmonary metastases 24
—— *Remarks* in reply 37
—— uterus showing rapidly growing epithelioma of the cervix; death from recurrence five months after removal 284
—— *Report* on A. Routh's specimen of Fallopian tube ruptured towards its fimbriated end in two places . . 133
—— —— on A. Routh's specimen of uterus removed at eight and a half months of gestation by abdominal hysterectomy for fibroid obstructing labour . . . 41
—— —— on A. E. Giles's specimen of fibroma of the ovary . 362
—— —— on J. M. Munro Kerr's specimen of tumour of the uterus 131
—— —— on W. C. Swayne's specimen of sarcoma of the body of the uterus with complete inversion . . 368
—— *Remarks* in discussion on J. Bland-Sutton's specimen of a case of tubal pregnancy diagnosed before rupture and a case of tubal abortion 46
Lymphangitis mammæ: an affection of the breast arising about the tenth day of the puerperium with well-marked clinical features (R. H. Vincent) . . . 158

McCann (F. J.), "deciduoma malignum" after the menopause 294
—— squamous carcinoma of the cervix uteri . . 136
—— tubal mole removed by colpotomy . . . 133
—— *Remarks* in reply 136
—— *Report* of Committee 296

PAGE

McCann (F. J.), *Remarks* in discussion on A. H. N. Lewers's specimens of two uteri removed by abdominal pan-hysterectomy for cancer of the body . . . 22
McKerron (R. G.), suppression of urine after labour . 97
Malins (Edward), *Remarks* in discussion on W. W. H. Tate's specimen of gangrenous sarcoma of uterus removed by abdominal hysterectomy from a patient suffering from glycosuria 168
Meningitis, primary pneumococcus, simulating puerperal eclampsia (T. Wilson) 5
Menopause, "deciduoma malignum" after the (F. J. McCann) 294
Metastases, pulmonary, chorio-epithelioma with (C. Lockyer) 24
Mole, tubal, removed by colpotomy (J. McCann) . . 133
Myoma, pure, of ovary, with a microscopic section (A. Doran) 168

Necrosis of solid masses in unilocular ovarian cyst (J. S. Fairbairn) 126

Obituary notices of Deceased Fellows.
Goddard, Eugene, M.D.Durh., Highbury . . 69
Tinley, Thomas, M.D.Durh., Whitby . . . 69
Williams, John D., Cardiff 70
Lawrence, A. E. Aust, M.D., Bristol . . . 70
Sutherland, Henry, M.D., New Cavendish Street . 71
Harvey, Robert, C.B., D.S.O., Simla, India . . 71
Ovaries, adeno-carcinoma of both (A. W. W. Lea) . . 225
—— pregnancy after removal of both, for cystic tumour (A. Doran) 231
Ovariotomy and posterior vaginal section during labour; ovarian tumour obstructing delivery; operation and delivery at one sitting; recovery (J. W. Taylor) . 275
—— vaginal, for removal of small ovarian tumour, from a patient who was about two months pregnant (J. W. Taylor) 297
Ovary, dermoid cyst of, removed by posterior colpotomy (A. Routh) 38
—— fibroma of (F. N. Boyd) 176
—— —— (A. E. Giles) 360
—— —— one third of an inch in diameter (A. Doran) . 173
—— five specimens of fibroid tumour of, with observations on their pathological anatomy (J. S. Fairbairn) . . 177

PAGE
Ovary, pure fibroma of (A. Doran) . . . 172
—— pure myoma of, with a microscopic section (A. Doran) . 168
—— sarcoma of (P. Horrocks) 94
—— solid tumour of left, with an attached cyst communicating with the left Fallopian tube (W. F. V. Bonney) . 92
—— unilocular cyst containing solid masses undergoing necrotic change (J. S. Fairbairn) . . . 126

Pan-hysterectomy, abdominal, for cancer of the body of uterus (A. H. N. Lewers) 10
—— for primary carcinoma of the body of the uterus, removal by abdominal (A. H. N. Lewers) . . . 290
Parturition, uterus and vagina with the child *in situ* in the second stage of (W. F. Victor Bonney) . . 292
—— uterus removed at eight and a half months of gestation by abdominal hysterectomy for fibroid obstructing (A. Routh) 41
Pedicle, fibroid, of the broad ligament, weighing four and a half pounds, with twisted (A. H. N. Lewers) . . 364
—— pyosalpinx with twisted (A. H. N. Lewers) . . 362
Pneumococcus meningitis, primary, simulating puerperal eclampsia (T. Wilson) 5
Porro-Cæsarean section, presentation of report on (H. R. Spencer) 298
Porro medal and report on Porro-Cæsarean section (H. R. Spencer) 298
Pregnancy after removal of both ovaries for cystic tumour (A. Doran) 231
—— extra-uterine (P. Horrocks) 228
—— —— two cases of which went to term (J. Bland-Sutton) 316
—— —— unusual (H. Williamson) . . . 225
—— primary ovarian (A. W. Mayo Robson) . . 215
—— ruptured tubal (J. H. Dauber) . . . 321
—— tubal, diagnosed before rupture, and a case of tubal abortion (J. Bland-Sutton) 44
—— uterus removed at eight and a half months of, by abdominal hysterectomy for fibroid obstructing labour (A. Routh) 41
Prolapse, congenital, of uterus associated with spina bifida (H. R. Andrews) 137
Puerperal eclampsia, with autopsy and remarks (R. H. Bell) . 253

PAGE

Puerperium, lymphangitis mammæ: an affection of the breast arising about the tenth day of (R. H. Vincent) . . 158
Pyosalpinx with twisted pedicle (A. H. N. Lewers) . . 362

Report (audited) of the Treasurer for 1901 . . 47, 48
—— *of the Chairman of the Board for the Examination of Midwives* 49
—— *of the Hon. Librarian for* 1901 . . . 47
—— *of Committee on A. J. Sturmer's specimen of parasitic cyst of the vulva* 4
—— *of Committee on H. Williamson's specimen of pregnancy in rudimentary horn of a uterus bicornis* . . 228
—— *of Committee on W. E. Fothergill's specimen of decidual uterine cast of seven weeks' growth, together with an ovum of about five days' growth (shown June 5th,* 1901) . . 251
—— *of the Pathological Committee on Comyns Berkeley's specimen of ovarian abscess ruptured during labour* . . 77
—— —— *on W. F. V. Bonney's specimen of solid ovarian tumour with a cyst attached, with the tube open* . . 93
—— —— *on J. M. Munro Kerr's specimen of tumour of the uterus* 130
—— —— *on P. Horrocks's specimen of ectopic gestation* . 229
—— —— *on W. W. H. Tate's specimen of sarcoma of the uterus (shown May 7th,* 1902) 252
—— —— *on A. H. N. Lewers's specimen of uterus removed by abdominal pan-hysterectomy for primary carcinoma of the body* 291
—— —— *on F. J. McCann's specimen of "deciduoma malignum" after the menopause* 296
—— —— *on Alban Doran's specimen of retro-peritoneal lipoma (p.* 265) 310
—— —— *on sections from the liver in R. H. Bell's case of puerperal eclampsia (p.* 253) 310
—— —— *on J. Bland-Sutton's specimen of carcinoma of Fallopian tube and fibro-myoma of uterus* . . . 313
—— —— *on J. H. Dauber's specimen of ruptured tubal gestation* 322
—— —— *on A. E. Giles's specimen of fibroma of the ovary* . 361
—— —— *on W. C. Swayne's specimen of sarcoma of the body of the uterus, with complete inversion* . . . 367
—— *of Teratological Committee on Hugh S. Stannus's specimen of orbital tumour in a fœtus* 91

PAGE

Repositors, failure of elastic pressure with, in a case of complete inversion of uterus of seven months' duration; operation of anterior vaginal cœliotomy, anterior hysterotomy, and replacement; recovery (J. W. Taylor) . 299

Roberts (C. Hubert), *Report* on Alban Doran's specimen of retro-peritoneal lipoma (p. 265) . . . 310

—— —— on A. H. N. Lewers's specimen of uterus removed by abdominal pan-hysterectomy for primary carcinoma of the body 291

—— —— on A. J. Sturmer's specimen of parasitic cyst of the vulva 5

—— —— on F. J. McCann's specimen of "deciduoma malignum" after the menopause 296

—— —— on H. Williamson's specimen of rudimentary horn of a uterus bicornis 228

—— —— on P. Horrocks's specimen of ectopic gestation . 229

—— —— on sections from the liver in R. H. Bell's case of puerperal eclampsia (p. 253) 310

—— —— on W. W. H. Tate's specimen of sarcoma of the uterus (shown May 7th, 1902) . . . 252

—— *Remarks* in discussion on W. F. Victor Bonney's specimen of uterus and vagina with the child *in situ* in the second stage of labour 293

Robinson (G. Drummond), *Remarks* in discussion on R. H. Bell's case of puerperal eclampsia, with autopsy and remarks 263

—— —— in discussion on J. W. Taylor's paper on ovarian tumour obstructing delivery; posterior vaginal section and ovariotomy during labour; operation and delivery at one sitting; recovery 281

Robson (A. W. Mayo), primary ovarian gestation . . 215

Routh (Amand), dermoid cyst of ovary removed by posterior colpotomy (shown) 38

—— *Remarks* in reply 40

—— Fallopian tube ruptured towards its fimbriated end in two places 131

—— uterus removed at eight and a half months of gestation by abdominal hysterectomy for fibroid obstructing labour 41

—— *Remarks* in reply 43

—— *Report* on A. J. Sturmer's specimen of parasitic cyst of the vulva 5

PAGE

Routh (Amand), *Remarks* in discussion on T. Wilson's specimen of primary pneumococcus meningitis simulating puerperal eclampsia 10

—— —— in discussion on A. H. N. Lewers's specimens of two uteri removed by abdominal pan-hysterectomy for cancer of the body 22

—— —— in discussion on J. Bland-Sutton's specimen of a case of tubal pregnancy diagnosed before rupture and a case of tubal abortion 46

—— —— in discussion on P. Horrocks's specimen of sarcoma of ovary 94

—— —— in discussion on R. H. Vincent's short communication on lymphangitis mammæ, an affection arising about the tenth day of the puerperium with well-marked clinical features 163

—— —— in discussion on A. Doran's paper on pregnancy after removal of both ovaries for cystic tumour . . 248

—— —— in discussion on R. H. Bell's case of puerperal eclampsia, with autopsy and remarks . . 265

Rupture of an ovarian abscess twelve hours after labour (C. Berkeley) 73

Sarcoma, gangrenous, of uterus, removed by abdominal hysterectomy from a patient suffering from glycosuria (W. W. H. Tate) 165

—— of ovary (P. Horrocks) 94

—— of the body of the uterus with complete inversion (W. C. Swayne) 366

—— small fibroma uteri showing evidence of (J. M. Munro Kerr) 129

Sikes (A. W.), icterus neonatorum . . . 369

Smith (G. B.), *Report* on Alban Doran's specimen of retro-peritoneal lipoma (p. 265) 310

—— —— on A. E. Giles's specimen of fibroma of the ovary . 362

—— —— on A. H. N. Lewers's specimen of uterus removed by abdominal pan-hysterectomy for primary carcinoma of the body 291

—— —— on C. Berkeley's specimen of ovarian abscess ruptured during labour 77

—— —— on F. J. McCann's specimen of "deciduoma malignum" after the menopause 296

—— —— on H. Williamson's specimen of rudimentary horn of a uterus bicornis 228

PAGE

SMITH (G. B)., *Report* on J. M. Munro Kerr's specimen of tumour of the uterus 131
—— —— on P. Horrocks's specimen of ectopic gestation . 229
—— —— on sections from the liver in R. H. Bell's case of puerperal eclampsia (p. 253) 310
—— —— on W. C. Swayne's specimen of sarcoma of the body of the uterus with complete inversion . . . 368
—— —— on W. F. V. Bonney's specimen of solid ovarian tumour with a cyst attached, with the tube open . 93
—— —— on W. W. H. Tate's specimen of sarcoma of the uterus (shown May 7th, 1902) 252
SMITH (Heywood), *Remarks* in discussion on J. W. Taylor's paper on ovarian tumour obstructing delivery; posterior vaginal section and ovariotomy during labour; operation and delivery at one sitting; recovery . . . 279
—— —— in discussion on C. Lockyer's specimen of uterus showing rapidly growing epithelioma of the cervix; death from recurrence five months after removal . . 290
—— —— in discussion on W. Duncan's specimen of three months' gravid uterus removed by vaginal hysterectomy from squamous epithelioma of cervix . . . 297
—— —— in discussion on J. W. Taylor's paper on complete inversion of uterus of seven months' duration . . 304
—— —— in discussion on J. Bland-Sutton's case of primary cancer of the Fallopian tube 314
—— —— in discussion on G. Ernest Herman and H. Russell Andrews's paper on the natural history of dysmenorrhœa 390
SPENCER (H. R.), Porro medal and report on Porro-Cæsarean section 298
—— *Report* on Alban Doran's specimen of retro-peritoneal lipoma (p. 265) 310
—— —— on A. E. Giles's specimen of fibroma of the ovary . 362
—— —— on A. H. N. Lewers's specimen of uterus removed by abdominal pan-hysterectomy for primary carcinoma of the body 291
—— —— on F. J. McCann's specimen of "deciduoma malignum" after the menopause . . . 296
—— —— on J. Bland-Sutton's case of primary cancer of the Fallopian tube 314
—— —— on J. H. Dauber's specimen of ruptured tubal gestation 322

PAGE

SPENCER (H. R.), *Report* on W. C. Swayne's specimen of sarcoma of the body of the uterus with complete inversion . 368
—— *Remarks* in discussion on T. Wilson's specimen of primary pneumococcus meningitis simulating puerperal eclampsia 10
—— —— in discussion on A. H. N. Lewers's specimens of two uteri removed by abdominal pan-hysterectomy for cancer of the body 22
—— —— in discussion on C. Lockyer's paper on a case of chorio-epithelioma with pulmonary metastases . . 37
—— —— in discussion on J. S. Fairbairn's paper on five specimens of fibroid tumour of the ovary, with observations on their pathological anatomy . . . 211
—— —— in discussion on A. Doran's paper on pregnancy after removal of both ovaries for cystic tumour . 247
—— —— in discussion on A. Doran's specimen of retro-peritoneal lipoma weighing thirteen pounds twelve ounces 273
—— —— in discussion on J. W. Taylor's paper on ovarian tumour obstructing delivery; posterior vaginal section and ovariotomy during labour; operation and delivery at one sitting; recovery 280
—— —— in discussion on C. Lockyer's specimen of uterus showing rapidly growing epithelioma of the cervix; death from recurrence five months after removal . 289
—— —— in discussion on J. W. Taylor's paper on complete inversion of uterus of seven months' duration, etc. . 305
—— —— in discussion on W. F. V. Bonney's specimen of a dermoid cyst containing a large number of epithelial balls 359
—— —— in discussion on W. C. Swayne's specimen of sarcoma of the body of the uterus with complete inversion . 368
Spina bifida in association with congenital prolapse of uterus (H. R. Andrews) 137
STANNUS (Hugh S.), teratoma of the fœtal head . . 78
—— *Report* of Committee 91
STURMER (A. J.), (?) parasitic cyst of the vulva . . 2
Super-fœtation, probable (W. F. V. Bonney) . . 163
Suppression of urine after labour (R. G. McKerron) . 97
Sutherland, Henry, M.D., of New Cavendish Street, obituary notice of 71
SWAYNE (W. C.), cystic fibroid of uterus . . . 369

PAGE

SWAYNE (W. C.), sarcoma of the body of the uterus with complete inversion 366
—— *Report* of Committee 367

TARGETT (J. H.), *Report* on Alban Doran's specimen of retro-peritoneal lipoma (p. 265) 310
—— —— on A. H. N. Lewers's specimen of uterus removed by abdominal pan-hysterectomy for primary carcinoma of the body 291
—— —— on A. J. Sturmer's specimen of parasitic cyst of the vulva 5
—— —— on F. J. McCann's specimen of "deciduoma malignum" after the menopause . . . 296
—— —— on H. Williamson's specimen of rudimentary horn of a uterus bicornis 228
—— —— on J. Bland-Sutton's case of primary cancer of the Fallopian tube 314
—— —— on J. H. Dauber's specimen of ruptured tubal gestation 322
—— —— on P. Horrocks's specimen of ectopic gestation . 229
—— —— on sections from the liver in R. H. Bell's case of puerperal eclampsia (p. 253) 310
—— —— on W. E. Fothergill's specimen of decidual uterine cast of seven weeks' growth, together with an ovum of about five days' growth (shown June 5th, 1901) . 252
—— —— on W. W. H. Tate's specimen of sarcoma of the uterus (shown May 7th, 1902) . . . 252
TATE (W. W. H.), gangrenous sarcoma of uterus removed by abdominal hysterectomy from a patient suffering from glycosuria 165
—— lithopædion retained in patient for sixteen years . 95
—— *Report* of Committee 252
—— *Remarks* in discussion on R. G. McKerron's paper on suppression of urine after labour . . . 121
TAYLOR (J. W.), complete inversion of uterus of seven months' duration; failure of elastic pressure with repositors; operation of anterior vaginal cœliotomy, anterior hysterotomy, and replacement; recovery . . . 299
—— *Remarks* in reply 307
—— ovarian tumour obstructing delivery; posterior vaginal section and ovariotomy during labour; operation and delivery at one sitting; recovery . . . 275

PAGE
Taylor (J. W.), *Remarks* in reply . . . 281
—— small ovarian tumour removed by vaginal section from a patient who was about two months pregnant . . 297
Teratoma of the fœtal head (H. S. Stannus) . . 78
Tinley, Thomas, M.D., of Whitby, obituary notice of . 69
Tubercle of uterus (P. Horrocks) 141
—— (H. Williamson) 141
Tuberculosis of cervix (E. O. Croft) . . . 142
—— primary, of the cervix simulating cancer, and treated by vaginal hysterectomy (A. H. N. Lewers) . . 144
Tumour, cystic, pregnancy after removal of both ovaries for (A. Doran) 231
—— fibroid obstructing labour, uterus removed at eight and a half months of gestation by abdominal hysterectomy for (A. Routh) 41
—— fibroma of ovary (F. N. Boyd) . . . 176
—— —— (A. E. Giles) 360
—— —— one third of an inch in diameter (A. Doran) . 173
—— fibro-myoma of the vagina (J. M. Munro Kerr) . 130
—— ovarian, obstructing delivery; posterior vaginal section and ovariotomy during labour; operation and delivery at one sitting; recovery (J. W. Taylor) . . . 275
—— pure fibroma of the ovary (A. Doran) . . . 172
—— pure myoma of the ovary, with a microscopic section (A. Doran) 168
—— retro-peritoneal lipoma weighing thirteen pounds twelve ounces (A. Doran) 265
—— sarcoma of ovary (P. Horrocks) . . . 94
—— small ovarian, removed by vaginal section from a patient who was about two months pregnant (J. W. Taylor) . 297
—— solid, of left ovary with an attached cyst communicating with the left Fallopian tube (W. F. V. Bonney) . . 92

Urine, suppression of, after labour (R. G. McKerron) . 97
Uterus and vagina with the child *in situ* in the second stage of labour (W. F. Victor Bonney) . . . 292
—— cancer of the cervix of, from eight cases treated by the supra-vaginal amputation, in which from four to fifteen years had elapsed without recurrence (A. H. N. Lewers) . 221
—— complete inversion of seven months' duration; failure of elastic pressure with repositors; operation of anterior vaginal cœliotomy, anterior hysterotomy, and replacement; recovery (J. W. Taylor) . . . 299

PAGE

Uterus, congenital prolapse of, associated with spina bifida (H. R. Andrews) 137
—— cystic fibroid of (W. C. Swayne) . . . 369
—— gangrenous sarcoma of, removed by abdominal hysterectomy from a patient suffering from glycosuria (W. W. H. Tate) 165
—— primary tuberculosis of the cervix of, simulating cancer, and treated by vaginal hysterectomy (A. H. N. Lewers) . 144
—— removed at eight and a half months of gestation by abdominal hysterectomy for fibroid obstructing labour (A. Routh) 41
—— removed by abdominal pan-hysterectomy for primary carcinoma of the body (A. H. N. Lewers) . . 290
—— sarcoma of the body, with complete inversion (W. C. Swayne) 366
—— showing rapidly growing epithelioma of the cervix; death from recurrence five months after removal (C. Lockyer) 284
—— small fibroma of, showing sarcomatous changes (J. M. Munro Kerr) 129
—— squamous carcinoma of cervix of (F. J. McCann) . 136
—— three months' gravid, removed by vaginal hysterectomy for squamous epithelioma of cervix (W. Duncan) . 297
—— tubercle of (P. Horrocks) 141
—— —— (H. Williamson) 141
—— tuberculosis of cervix of (E. O. Croft) . . 142
Uteri, two, removed by abdominal pan-hysterectomy for cancer of the body (A. H. N. Lewers) . . . 10

Vagina, fibro-myoma of (J. M. Munro Kerr) . . 130
Vincent (Ralph Henry), lymphangitis mammæ: an affection of the breast arising about the tenth day of the puerperium with well-marked clinical features . . 158
Vulva, (?) parasitic cyst of (A. J. Sturmer) . . 2

Williams, John D., of Cardiff, obituary notice of . . 70
Williamson (Herbert), abnormal umbilical cord . . 141
—— tubercle of uterus 141
—— unusual case of ectopic gestation . . . 225
—— *Report* of Committee 228
—— —— on P. Horrocks's specimen of ectopic gestation . 229

PAGE

WILLIAMSON (H.), *Report* on W. W. H. Tate's specimen of sarcoma of the uterus (shown May 7th, 1902) . . . 252

—— *Remarks* in discussion on R. H. Bell's case of puerperal eclampsia, with autopsy and remarks 263

WILSON (Thomas), primary pneumococcus meningitis simulating puerperal eclampsia (shown) 5

WOOLBERT (Major, R.M.S.), *Remarks* in discussion on C. Berkeley's specimen of ovarian abscess ruptured during labour 77

OBSTETRICAL SOCIETY.

ADDITIONS TO THE LIBRARY

BY DONATION OR PURCHASE DURING THE YEAR 1902.

Presented by

AUVARD. Traitement de l'éclampsie puerpérale. sm. 8vo. Paris, 1889. Purchased.

BALLANTYNE (J. W.). Manual of antenatal pathology and hygiene. The fœtus. *illust.*, 8vo. Edinburgh, 1902 Ditto.

BAR (Paul). Deux questions obstétricales.

I. Dans le cas de viciation pelvienne, le médicin peut-il aujourd'hui, sans engager sa responsabilité morale, provoquer l'accouchement? Pratiquer l'embryotomie sur l'enfant vivant?

II. De la mise à exécution des interventions dans les cas de dystocie par viciation pelvienne.

8vo. Paris, 1902 Author.

BECK (T. Snow). On the management of women during and after parturition. 8vo. undated. Dr. Heywood Smith.

——— On the nerves of the uterus. From the 'Philosophical Transactions,' part ii for 1846. 4to. Lond. 1846 Ditto.

Bibliographia Medica [Index Medicus] Recueil mensuel. Classement méthodique de la Bibliographie internationale des sciences médicales. Marcel Baudouin. Tome i. 8vo. Paris, 1900 Purchased.

Bibliothèque de médecin-praticien ou résumé général de tous les ouvrages de clinique médicale et chirurgicale de toutes les monographies, de tous les mémoires de médecine et de chirurgie pratiques, anciens et modernes, publiés en France et à l'étranger: par une société de médecins: sous la direction du docteur Fabre. Maladies des Femmes. Two volumes. 8vo. Paris, 1842 Dr. Heywood Smith.

Presented by

Bland-Sutton (J.) and Arthur E. Giles. The diseases of women: a handbook for students and practitioners. 3rd edit. *illust.*, 8vo. Lond. 1902 — Authors.

Blundell (James). Observations on some of the more important diseases of women. 8vo. Lond. 1837 — Dr. Heywood Smith.

Broussais (F. J. V.). Histoire des phlegmasies ou inflammations chroniques, fondée sur de nouvelles observations de clinique et d'anatomie pathologique; ouvrage présentant un tableau raisonné des variétés et des combinaisons diverses de ces maladies, avec leurs différentes méthodes de traitement. Troisième édition revue et augmentée de notes. Three volumes. 8vo. Paris, 1822 — Ditto.

Bumm (E.). Grundriss zum Studium der Geburtshülfe in achtundzwanzig Vorlesungen und fünfhundert-fünfundsiebenzig bildlichen Darstellungen. *illust.*, la. 8vo. Wiesbaden, 1902 — Purchased.

Canuet (L. Urb.). Ars extrahendi secundinas ou l'art de la déliverance, in casu inertiæ uteri, spasmo et convulsionibus, extremæ debilitati et hæmorrhagiæ adjunctæ. Editio secunda. 8vo. Paris, 1807 — Dr. Heywood Smith.

Catalogue of books added to the Radcliffe Library, Oxford University Museum, during the year 1901 4to. Oxford, 1901 — The Radcliffe Librarian.

——— (descriptive) of the Museum of the British Congress on Tuberculosis held in London, July 22nd to 26th, 1901. Compiled and edited by W. Jobson Horne, M.D. 8vo. Lond. 1901 — Congress on Tuberculosis.

Chapman (Edmund). A treatise on the improvement of midwifery, chiefly with regard to the operation. To which are added, fifty-seven cases, selected from upwards of twenty-seven years' practice. 3rd edit., with large additions. 8vo. Lond. 1759 — Dr. Heywood Smith.

Chrobak (R.) See *Reports*.

Presented by

CLAY (Charles). The British record of Obstetric Medicine and Surgery for 1848; consisting of original papers on midwifery and the diseases of women and children, by the most eminent living practical obstetricians; a collection of rare and valuable monographs of ancient and modern writers; a retrospective digest of European journals for 1848, containing 350 references; encyclopædia obstetrica, from Aaron to Andracune, nearly 150 articles. Two volumes. 8vo. Manchester and Lond. 1848 — Dr. Heywood Smith.

COMBE (Andrew). A treatise on the physiological and moral management of infancy. 3rd edit. sm. 8vo. Edin. 1842 — Ditto.

COUVELAIRE (A). Études anatomiques sur les grossesses tubaires. la. 8vo. Paris, 1901 — Purchased.

CULLINGWORTH (Charles J.). Clinical illustrations of diseases of the Fallopian tubes and of early tubal gestation. A series of drawings with descriptive text and histories of the cases. 3rd edit., revised. 8vo. Lond. 1902 — Author.

CURATULO (G. Emilio). L'Arte di Juno Lucina in Roma. Storia dell' Ostetricia dalle sue origini fino al secolo xx con documenti inediti. *illust.*, la 8vo. Rome, 1901 — Dr. Cullingworth.

DARAN (Jaques). A complete treatise on the virulent gonorrhœa, both in men and women. Translated from the French. sm. 8vo. Lond. 1766 — Dr. Heywood Smith.

DE LA MOTTE (le Sr.). Traité des acouchemens naturels, non naturels, et contre nature, expliqués dans un grand nombre d'observations et de réflexions sur l'art d'accoucher. 4to. The Hague, 1726 — Ditto.

DIENST (Arthur). Neuere Untersuchungen über das Wesen der Eklampsie und Gesichtspunkte über die Behandlung der Krankheit. ('Volkmann's Sammlung,' klinischer Vorträge, neue Folge, Nr. 342.) 8vo. Leipzig, 1902 — Purchased

DOHRN (R.). Ueber die gesetzliche Verantwortlichkeit des Arztes bei geburtshülflichen Operationen. ('Volkmann's Sammlung,' klinischer Vorträge, neue Folge, Nr. 336.) 8vo. Leipzig, 1902 — Ditto

EKSTEIN (Emil). Geburtshilfliche Neuorganisationen in Oesterreich. 8vo. Stuttgart, 1902 — Ditto.

Presented by

FERGUSON (James Haig). See *Haultain*.

FRANTA (J.). Kystes hydatiques pendant la grossesse, l'accouchement et les suites de couches.
8vo. Prag. 1901 — Author.

FREUND (Hermann W.). Vorschläge zur weiteren Reform des Hebammenwesens.
8vo. Leipz. u. Wien, 1902 — Purchased.

GARRIGUES (Henry J.). A text-book of the science and art of obstetrics.
illust., 8vo. Phila. and Lond. 1902 — Author.

GILES (Arthur E.). See *Bland-Sutton* (J.).

GRAHAM (Thomas J.). On the diseases of females: a treatise describing their symptoms, causes, varieties, and treatment including the diseases and management of pregnancy and confinement. Designed as a companion to the author's 'Modern Domestic Medicine,' containing also an account of the symptoms and treatment of diseases of the heart, and a medical glossary. 6th edit.
8vo. Lond. 1855 — Dr. Heywood Smith.

HAIGHTON (Dr.). A syllabus on the lectures on midwifery delivered at Guy's Hospital.
8vo. Lond. undated — Ditto.

HAULTAIN (Francis W. N.) and James Haig FERGUSON. Handbook of Obstetric Nursing. 4th. edit. revised and enlarged.
illust., sm. 8vo. Edin. and Lond. 1902 — Purchased

HÜBL (Hugo). Ueber das Chorio-Epitheliom in der Vagina bei sonst gesundem Genitale.
illust., 8vo. Wien, 1902 — Ditto.

KEITH (Arthur). Human embryology and morphology.
illust., 8vo. Lond. 1902 — Ditto.

KERMAUNER (Fritz). Neuere Anschauungen über die Blasenmole. (Separatabdruck aus den 'Mitteilungen des Vereines der Aerzte in Steiermark,' Nr. 1, 1902.) — Dr. Alfons Rosthorn.

——— und H. LAMÉRIS. Zur Frage der erweiterten Radikal-operation des Gebärmutterkrebses. ('Sonderabdruck aus der Frauenklinik der Universität Graz.,' Band v, Heft 1.) — Ditto.

KLEINHANS (Fritz). Ueber einen Fall von Deciduoma malignum. ('Sonderabdruck a. d. Prager med. Wochenschrift,' xxiv, Nr. 17, 1899.) — Ditto.

Presented by

Kossmann (R.). Allgemeine Gynaekologie.
illust., la 8vo. Berl. 1903 Purchased.

Lachapelle (Mme.). Pratique des accouchemens ou mémoires et observations choisies, sur les points les plus importans de l'art. Three volumes.
8vo. Paris, 1825 Dr. Heywood Smith.

Lachs (Johann). Die Gynäkologie des Soranus von Ephesus. ('Volkmann's Sammlung,' klinischer Vorträge, neue Folge, Nr. 335.)
8vo. Leipzig, 1902 Purchased.

Launay (Léon). Les relations nosologiques de la chorée des femmes enceintes. Thèse pour le doctorat en médecine. Année 1901. Ditto.

Lewers (Arthur H. N.). Cancer of the uterus; a clinical monograph on its diagnosis and treatment, with the after-results in seventy-three cases treated by radical operation.
illust., 8vo. Lond. 1902 Author.

Lönnberg (Ingolf). Studien über das Nabelbläschen an der Nachgeburt des ausgetragenen Kindes.
illust., 8vo. Stockholm, 1901 Purchased.

L'Operazione Cesarea Porro nel xxx Anniversario. mdcccci. 8vo. Rome, 1901 Dr. Herbert R. Spencer.

Luithlen (Friedrich). Die Zellgewebsverhärtungen der Neugeborenen. ('Sclerema œdematosum, Adiposum und Sclerodermie.') Eine monographische Studie. 8vo. Wien, 1902 Purchased.

Maclennan (Alexander). Abdominal examination and manipulation in pregnancy; with an introduction by Professor Murdoch Cameron.
sm. 8vo. Lond. 1902 Ditto.

Menville (Dr.). Histoire médicale et philosophique de la femme considérée dans toutes les époques principales de sa vie avec tous les changements qui surviennent dans son physique et son moral avec l'hygiène applicable à son sexe et toutes les maladies qui peuvent l'atteindre aux différents âges. Three volumes. 8vo. Paris, 1845 Dr. Heywood Smith.

Meyer (Robert). Ueber epitheliale Gebilde im Myometrium des fœtalen und kindlichen Uterus einschliesslich des Gartner'schen Ganges.
illust., 8vo. Berl. 1899 Purchased.

Presented by

MINOT (Charles Sedgwick). The embryological basis of pathology. (Reprinted from 'Science,' N.S., vol. xiii, No. 326, pp. 481–498, March 29th, 1901.) Author.

——— The problem of consciousness in its biological aspects. (Reprinted from 'Science,' N.S., vol. xvi, No. 392, pp. 1–2, July 4th, 1902.) Ditto.

NAGEL (Wilhelm). Operative Geburtshülfe für Aerzte und Studierende. *illust.*, 8vo. Berl. 1902 Ditto.

OLSHAUSEN (R.) und J. VEIT. Lehrbuch der Geburtshülfe mit Einschluss der Wochenbetts-krankheiten und der Operationslehre. Fünfte, neu bearbeitete Auflage. *illust.*, 8vo. Bonn, 1902 Purchased.

PICHARD (F.-L.). Maladies des femmes. Traitement rationnel et pratique des ulcérations du col de la matrice. 8vo. Paris, 1847 Dr. Heywood Smith.

PICK (Ludwig). Ueber Hyperemesis gravidarum. ('Volkmann's Sammlung,' klinischer Vorträge, neue Folge, Nr. 325, 326.) 8vo. Leipzig, 1902 Purchased.

PINCUS (Ludwig). Zur Praxis der "Belastungslagerung." ('Volkmann's Sammlung,' klinischer Vorträge, neue Folge, Nr. 332.) 8vo. Leipzig, 1902 Ditto.

POLANO (Oscar). Ueber die Entwicklung und den jetzigen Stand der Lehre von der Blasenmole und dem sogenannten malignen Deciduom. ('Volkmann's Sammlung,' klinischer Vorträge, neue Folge, Nr. 329.) 8vo. Leipzig, 1902 Ditto.

RICHTER (Paul). Ueber Pemphigus neonatorum. 8vo. Berlin, 1902 Ditto.

ROSTHORN (Alphons von). Geburtshilfe und Frauenheilkunde an der k. k. deutschen Universität in Prag in der zweiten Hälfte des Jahrhunderts. ('Separatabdruck aus der Festschrift der k. k. deutschen Universität in Prag anlässlich des 50 jährigen Regierungsjubiläums Sr. Majestät des Kaisers Franz Josef I.') Author.

——— Neuere Bestrebungen und Erfahrungen über die operative Behandlung des Gebärmutterkrebses. (Separatabdruck aus den "Mittheilungen des Vereines der Arzte in Steiermark," Nr. 3, 1902.) Ditto.

——— Spencer Wells. ('Sonderabdruck a. d. Prager med. Wochenschrift,' xxii, Nr. 9, 1897.) Ditto.

Presented by

SCHATZ (Prof. Dr.). Die griechischen Götter und die menschlichen Missgeburten. Vortrag gehalten im Docentenverein der Universität Rostock am 3 Mai, 1901. *illust.*, 8vo. Wiesbaden, 1901 Purchased.

SCHAUENSTEIN (Walther). Zur Bakteriologie des puerperalen Uterussekretes. (Sonderabdruck aus der k. k. Frauenklinik der Universität Graz., Bd. v, Heft 3.) Dr. Alfons Rosthorn.

SCIPIADES (Elemér). Die Frage der Prophylaxis der Ophthalmoblenorrhœa neonatorum mit Berücksichtigung der Erfolge der Silberacetat-Instillation. ('Volkmann's Sammlung,' klinischer Vorträge, neue Folge, Nr. 340.)
8vo. Leipzig, 1902 Purchased.

SIEBOLD (Ed. Casp. Jac. von). Versuch einer Geschichte der Geburtshülfe. Zweite Auflage. Zweiter Band. sm. 8vo. Tübingen, 1902 Ditto.

SIPPEL (Fritz). Ueber die Berechtigung der Vernichtung des kindlichen Lebens zur Rettung der Mutter vom geburtshilflichen, gerichtlichmedizinischen und ethischen Standpunkt.
8vo. Tübingen, 1902 Ditto.

SOUTHWELL (Thomas). Remarks on some of the errors both in anatomy and practice, contained in a late 'Treatise of Midwifery,' by Fielding Ould, Man-midwife. 8vo. Dubl. 1742 Ditto.

STRATZ (C. H.). Die Frauenkleidung. Zweite Auflage. *illust.*, 8vo. Stuttgart, 1902 —

TANDLER (Julius) und Josef HALBAN. Topographie des weiblichen Ureters mit besonderer Berücksichtigung der pathologischen Zustände und der gynäkologischen Operationen in 32 chromolithographischen Tafeln mit erläuterndem Texte.
illust., 4to. Wien u. Leipz. 1901 Purchased.

THORN (W.). Die Stellung der manuellen Umwandlung in der Therapie der Gesichts- und Stirnlagen. 8vo. Leipzig, 1902 Ditto.

Presented by

VOLKMANN's Sammlung klinischer Vorträge, neue Folge:

325, 326. *Pick*, Über Hyperemesis gravidarum.
329. *Polano*, Ueber die Entwicklung und den jetzigen Stand der Lehre von der Blasenmole und dem sogenannten malignen Deciduom.
332. *Pincus*, Zur Praxis der "Belastungslagerung."
335. *Lachs*, Die Gynäkologie des Soranus von Ephesus.
336. *Dohrn*, Ueber die gesetzliche Verantwortlichkeit des Arztes bei geburtshülflichen Operationen.
339. *Thorn*, Die Stellung der manuellen Umwandlung in der Therapie der Gesichts- und Stirnlagen.
340. *Scipiades*, Die Frage der Prophylaxis der Ophthalmoblenorrhœa neonatorum mit Berücksichtigung der Erfolge der Silberacetat-Instillation.
342. *Dienst*, Neuere Untersuchungen über das Wesen der Eklampsie und Gesichtspunkte über die Behandlung der Krankheit.

WEBSTER (J. Clarence). Human placentation: an account of the changes in the uterine mucosa and in the attached fetal structures during pregnancy. *illust.*, 8vo. Chicago, 1901

WEINBERG (Wilhelm). Beiträge zur Physiologie und Pathologie der Mehrlingsgeburten beim Menschen. ('Separatabdruck aus dem Archiv für die ges. Physiologie,' Bd. lxxxviii.) Dr. Alfons Rosthorn.

TRANSACTIONS.

AMERICAN ASSOCIATION OF OBSTETRICIANS AND GYNECOLOGISTS—
Transactions, vol. xiv, for 1901.
8vo. Philad. 1902 Association.

AMERICAN GYNECOLOGICAL SOCIETY—
Transactions, vol. xxvi, for 1901.
8vo. Philad. 1901 Society.

CLINICAL SOCIETY OF LONDON—
Transactions, vol. xxxv. 8vo. Lond. 1902 Ditto.

COLLEGE OF PHYSICIANS OF PHILADELPHIA—
Transactions of the Section on Gynecology. Vol. VI, 1900. Vol. VII, 1901. [Reprinted from the 'American Journal of Obstetrics.'] College.

DET KJOBENHAVNSKE MEDICINSKE SELSKABS—
Forhandlinger 1901–1902, redigeret af Dr. Fr. Vogelius. 8vo. Copenhagen, 1902 Society.

Presented by

DEUTSCHE GESELLSCHAFT FÜR GYNÄKOLOGIE—
Verhandlungen, Neunte Versammlung abgehalten zu Giessen, 1901. 8vo. Leipzig, 1901 Society.

MEDICAL (ROYAL) AND CHIRURGICAL SOCIETY—
Transactions, vol. lxxxiv. 8vo. Lond. 1901 Ditto.

MEDICAL SOCIETY OF LONDON—
Transactions, vol. xxiv. 8vo. Lond. 1901 Ditto.

SOCIÉTÉ DE MÉDECINE DE ROUEN—
Bulletin, 2e Série. Vol. xiv. 39e Année, 1900.
8vo. Rouen, 1901 Ditto.

JOURNALS.

ARCHIVIO ITALIANO DI GINECOLOGIA, Anno v, 1902.
8vo. Naples, 1902 Exchange.

REPORTS.

AMERICA—HOSPITALS—Boston Lying-in Hospital: the 69th year, for 1901. 8vo. Boston, 1902 Hospital Staff.

——— ——— Medical and Surgical Report of the Presbyterian Hospital in the city of New York, vol. v, January, 1902. 8vo. New York, 1902 Ditto.

——— ——— The Society of the New York Hospital. Annual Report for the year 1901.
8vo. New York, 1902 Society

HOSPITALS—Annual Report of the Government Maternity Hospital, Madras, for the year 1901.
la. 8vo. Madras, 1902 Hospital Staff.

——— Middlesex Hospital Reports for the year 1900.
8vo. Lond. 1900 Ditto.

——— St. Bartholomew's Hospital Reports, vol. xxxvii.
8vo. Lond. 1901 Ditto.

——— St. Thomas's Hospital Reports, New Series, vol. xxix. 8vo. Lond. 1900 Ditto.

	Presented by
Berichte aus der zweiten geburtsh.-gynäkologischen Klinik in Wien. Herausgegeben von R. Chrobak. Two volumes. 8vo. Wien, 1902	Purchased.
Jahresbericht über die Fortschritte auf dem Gebiete der Geburtshilfe und Gynäkologie, herausgegeben von Richard Frommel, xiv Jahrgang, 1901. 8vo. Wiesbaden, 1901	Dr. Frommel.
Jahresbericht der Gesellschaft für Natur- und Heilkunde in Dresden. Sitzungsperiode 1900–1901. 8vo. Dresden, 1901	Society.

PRINTED BY ADLARD AND SON, LONDON AND DORKING.

SERIAL

RG
1
C3
v.44

Obstetrical Society of London
Transactions

GERSTS